



Reducing Neointimal Hyperplasia in Experimental Carotid Balloon Damage Model with Oral Administration of Cilostazol

Hasan Murat Arslan¹, Perçin Karakol², Ali Vefa Özcan³

¹Department of Cardiovascular Surgery, Istanbul Fatih Sultan Mehmet Training and Research Hospital, Istanbul, Türkiye

²Department of Plastic, Reconstructive and Aesthetic Surgery, Health Science University Bağcılar Training and Research Hospital, Istanbul, Türkiye

³Department of Cardiovascular Surgery, Pamukkale University Education Practice and Research Hospital, Denizli, Türkiye

Abstract

Introduction: Percutaneous revascularization is one of the interventions through which results are obtained quite quickly among the current treatment of blockage artery diseases. In fact, the success achieved is lower than expected due to stenosis formation and spontaneous thrombosis. Vascular endothelial damage after endovascular interventions causes it to become a sticky surface for leukocytes and platelets, the distortion of the normally smooth surface through which the blood moves nonstop causes an increase in adhesion and procoagulant activities and permeability. While many cytokines, vasoactive molecules, and growth factors are released intermittently, if the inflammatory response is not suppressed in some way, the accumulation of extracellular matrix occurs with smooth muscle cell migration and proliferation in the vascular wall. This process, known as neointimal hyperplasia, has become a nightmare for many surgeons. As the known physiopathological mechanism of restenosis began to be understood, many pharmacological agents, mechanical agents were developed to prevent this process and tested with animal and human clinical trials. In our study, we aimed to show the inhibitive effect of cilostazol on neointimal hyperplasia by giving the experimental animal model an oral way.

Methods: Intimal damage was created in the control and experiment group using the rat carotid artery balloon damage model. A group of animals was reserved as a Sham group. Preparations obtained from rat common carotid after oral cilostazol treatment for 2 weeks were evaluated histopathologically. Their statistical significance was observed.

Results: In within-group analyses, while no difference was observed among themselves, in cross-group analyses, in terms of intimal thickening, a significant difference was found between Group 1 (Sham) and Group 2 (Control), Group 2 and Group 3 (Experiment), however, between Group 1 and Group 3, no statistically significant difference was detected. In light of these results, we reached the conclusion that cilostazol has an inhibitive effect on intimal hyperplasia when taken through the oral path. On the other hand, when comparing intimal and medial thickness rates, that the low artery intima/media ratio was found only in the experimental group, shows that the endothelial damage created in the intima was limited by cilostazol and decreased neointimal hyperplasia unrelated to the media layer.

Discussion and Conclusion: This drug whose systemic and topical effectiveness has been detected previously, would yield positive results not only in patients with peripheral artery disease, but also in peripheral artery patients with symptoms of claudicatio intermittence because of the fact that it shows the most effective and direct impact when administered orally, it is easy to use and its absorption is quite high.

Keywords: Carotid artery balloon injury; cilostazol; neointimal hyperplasia.

Correspondence (İletişim): Perçin Karakol, M.D. Sağlık Bilimleri Üniversitesi Bağcılar Eğitim ve Araştırma Hastanesi, Plastik Rekonstruktif ve Estetik Cerrahi Anabilim Dalı, İstanbul, Türkiye

Phone (Telefon): +90 535 396 55 35 **E-mail (E-posta):** ppercin@gmail.com

Submitted Date (Başvuru Tarihi): 30.04.2020 **Revised Date (Revize Tarihi):** 23.05.2020 **Accepted Date (Kabul Tarihi):** 27.05.2020

Copyright 2022 Haydarpaşa Numune Medical Journal

OPEN ACCESS This is an open access article under the CC BY-NC license (<http://creativecommons.org/licenses/by-nc/4.0/>).



At present, percutaneous revascularization has been started to be used frequently in the treatment of all occlusive artery diseases both central and peripheral since it is both practical and solution-oriented. However, the success of such percutaneous interventions is relatively low due to spontaneous thrombosis development and/or formation of stenosis. Balloon dilatation applied to arterial embolectomy; causes arterial wall damage with the release of high thrombogenic subendothelial structures resulting in local platelet adhesion and thrombosis formation and the rupture of internal elastic lamina^[1]. Local platelet activation and bioactive substances can increase platelet aggregation and vasoconstriction^[2,3]. Inflammatory cells play key role in neointimal hyperplasia, while leukocytes in the circulation complete their normal migration to the field of damage, this is responded to as smooth muscle proliferation and neointimal hyperplasia^[1,4,5]. This process, which is a normal adaptation mechanism against hemodynamic stress of the arteries, is the cause for return of complaints in the early period not only after percutaneous revascularization but also after applications such as balloon angioplasty, endarterectomy, and vascular stent placement and the rewinding of the pathologic cascade^[6]. Blocking this process would cause significant extension of the time the artery remains unclogged, reduction in organ loss and indirectly longer and higher quality living. Removal of ischemic symptoms and preventing secondary brain

infarct are the main objective. Animal and human studies continue at different stages for platelet inhibitors such as Cilostazol and Hirudin aimed at preventing the process of restenosis by defining all of its physiopathological stages separately, ciprostone which is a synthetic prostocycline analog, calcium channel blockers due to their antiproliferative effects and angiotensin converting enzyme inhibitors, various antineoplastic drugs, such as colchicine, an agent that stops mitosis in the metaphase phase, corticosteroids, various antioxidant drugs, and many more pharmacological agents^[7-9]. These drugs and their effects on neointimal hyperplasia are summarized (Table 1). However, a definitive effective treatment method for preventing intimal hyperplasia has still not been fully found. Efforts are underway to compare drugs and to reveal mechanisms of action. The antithrombocyte, antiagregant, antiproliferative effects of Cilostazol on smoothartery muscles, and its effects on changing lipid profiles and protecting endothelium have been proven (Fig. 1). Cilostazol is easily absorbed when taken through the oral path and rises to its maximum level within 3–4 h. It attaches especially to albumine, metabolizes through cytochrome p450, and then discarded, mostly with urine^[11,12]. Since it is not possible for the endothelium to be restored entirely, it is also important at least to ensure vascular openness, maintain the lipid profile and ensure that the drugs used to prevent the occasional interruption of blood flow to activate clotting cascade and are

Table 1. The mechanism of action of some drugs that have been shown to have effects on neointimal hyperplasia by creating animal experimental models

Drug	Effect	Experimental study			
		Animal	Artery	Damage	Intimal Hyperplasia
Aspirin	Antiagregan	Rat	Carotis	Deendotelization	Decreases
Dipiridamol	Antiagregan	Rabbit	Ear	Crush	Decreases
Enoxoparin	Low molecular weight heparin	Rabbit	İliac	Balloon angioplasty	Decreases
Heparin	Antithrombotic	Rat	Carotids	Balloon dilatation	Decreases
Hirudin	Antithrombotic	Rabbit Pig	Femoral artery Carotids	Air trauma	Decreases
Warfarin	Antithrombotic	Rat	Carotids	Balloon angioplasty	Decreases
Terapidil	PDGF receptor Antagonist	Rat Rabbit	Aorta İliac	Deendotelization	Decreases
Vapiprost	Tromboxan A receptor Antgonist	Rat	Aorta	Deendotelization	Decreases
Diltiazem	Calcium Antagonist	Rabbit	Carotids	Wire turning	Decreases
Nifedipine	Calcium Antagonist	Rat	Aorta	Deendotelization	Decreases
Cilazapril	ACE inhibitory	Rat	Carotids	Deendotelization	Decreases
Lovastatine	HMGCO-A reductase inhibitory	Rabbit	Carotids	Silicone collar	Decreases
Prednisolone	Corticosteroid	Rabbit	Ear	Crush	Decreases
Verapamil	Calcium Antagonist	Rabbit	Aorta	Deendotelization	Decreases

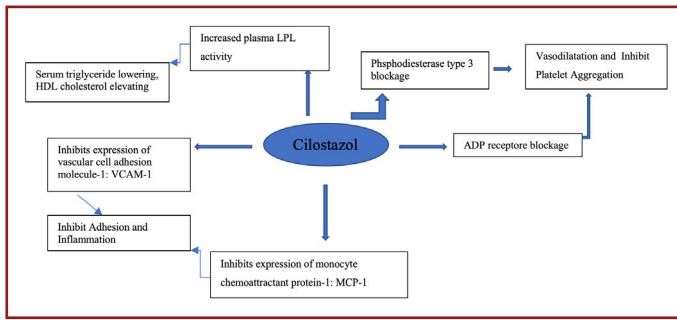


Figure 1. Proven effects and mechanisms of Cilostazol.

suitable for combined applications. While doing this study, we aimed to prove experimentally the effect of this drug on neointimal hyperplasia when taken orally.

Materials and Methods

The study was carried out on 20, 10 months old adult Sprague Dawley rats with an average weight of 450–500 g after taking Animal Experiments Local Ethics Board approval from our University. A rat balloon catheter damage model described by Yang Gao and his friends was used to cause vascular damage. The right carotid artery was selected for all rats. Working groups of animals selected randomly were described below (Table 2).

Anesthesia in all subjects was provided by 100 mg/kg ketamine hydrochloride (Ketalar, Eczacıbaşı, Türkiye) and 100 mg/kg xylazine hydrochloride (Rompun, Bayer, Türkiye) through intramuscular way mixed with a ratio of 6/4.1/3 of this dose was repeated as i.m. when necessary. After the depth of anesthesia was provided, the rat was suspended by exploring the right common carotid artery (RCA) with a longitudinal incision from the right of the middle line of the neck. The distal part of the external carotid artery was ligatured with silk suture by returning from the proximal and distal. By making a vertical incision to the external carotid artery, the 2/0 Fogarty catheter was advanced from the external carotid artery to the common carotide and by inflating with saline along the line, it was withdrawn after having held for 10 s. The operation was repeated 3 times in the same order. In this way, balloon damage was created in the RCA endothelium. After the damage was done with

the balloon catheter, the external carotid artery was ligated with suture from the point where it left the common carotid. After monitoring blood flow continuity in the RCA, the incision was closed with silk suture after hemostasis control. All subject group animals were monitored one by one in separate cages until the end of the study.

Tablet forms of cilostazol were made into a solution by crushing in 50 cc liquid (serum physiological) to make 20 mg/kg doses. The daily fluid requirement of a rat was observed and was found to be 30 cc on average. The rats were placed in cages separately and their waters were changed every morning. 2.5 cc Cilostazol was inserted into the daily waters of rats in the experimental group; it was observed that they drank close to all of their water. Treatment regimen continued for 14 days. Although different generic forms of drugs that prevent neointimal hyperplasia are on the market, the use of cilostazol is only designed as oral. In experimental studies, the drug is generally tested through intraperitoneal and topical methods since giving it to rats in this way to provide the appropriate blood dosage in equal and full doses cannot be foreseen^[10].

In the 2nd session after the 14th day, in all rats defined with experimental neointimal models suitable to the phase 3, exploring the right common carotid, sternal notch was reached by making an incision from the middle neck line under anesthesia, 10 mm section of the artery was cutoff at once with number 11 scalpel and removed without being crushed. After the procedure, all group rats were sacrificed. Artery samples were buried in paraffin blocks by being placed into 10% buffered formaldehyde solution. After routine follow-up, 500 μ sections were prepared. The sections were routinely painted with Hemotoxine-eoline and Orcein paint. They were examined histopathologically with the light microscope.

Using the SSPI-10.1 program parameters obtained as a result of the study was evaluated with:

- Kruskal–Wallis variance analysis test,
- Bonferroni sensitivity Mann–Whitney test,
- Pairwise significant difference testing,
- Wilcoxon signed ranks two paired sample test

Table 2. Classification of workgroups

Group 1 (Sham group) n=6: The group given only standard food and drinking water without any interference to the right carotid artery
 Group 2 (Control group) n=7: The group whose right carotid artery was damaged with balloon dilatation and given standard food and drinking water for 14 days
 Group 3 (Experimental group) n=7: The group whose right carotid artery was damaged with balloon dilatation, and given treatment of crushed and diluted cilostazol added into their drinking water for 14 days in addition to their standard food

Results

Histopathological and Statistical Analysis; All preparations for histochemical examination were stained with elastic Orcein. Thus, it was possible to measure the thickness of the intima, media, and adventitia layers separately. The intima and media thicknesses were measured and proportioned to each other using the light microscope and the Macro-media MX-11.0.2 imaging program. Here, intimal thickening due to hyperplasia in the intima was evaluated in Group 1 by mm (Fig. 2). Measurements were made from the two thickest areas of intimal thickness and their averages were obtained. Proportioning was made by repeating the same process in media thickness. The statistical significance was measured using SSPI-10. 1 program. All groups were compared with the parameters obtained as a result of intima thickness, media thickness, and proportion. While microscopic, intimal thickness was found in Group 3 to be close to the Sham group, intimal hyperplasia was found to be in the wide area in Group 2 (Fig. 3). It was observed that some media cells had passed to the intima by going through hypertrophy (Fig. 4).

When groups are evaluated by histopathological measurements within themselves; when all groups were analyzed within the group, there was no statistically significant difference in the groups themselves, in terms of vascular intimal and medial thicknesses.

When the differences between the groups are evaluated; in terms of intimal thickness measurement; it was seen that there was a significant difference between Group 1 and Group 2 and Group 2 and Group 3, and that there was no significant difference between Group 1 and Group 3 (Table 3).

In terms of Intima/Media thickness ratios; it was seen that there was a significant difference between Group 1 and Group

2, Group 2 and Group 3, and there was no difference between Group 1 and Group 3. Similar results have been shown to be achieved compared to Group 3 Group 1 (Table 4).

Discussion

Vascular angiographic imaging methods used for the purpose of diagnosis and treatment of vascular occlusion disease that develops especially due to diabetes, smoking, hyperlipidemia, and hypertension, as well as many etiological factors are used frequently today. These diagnostic methods are interventional methods that have an effect of damage on the arterial wall, especially on the endothelium. While damage and thickening of the artery endothelium due to smoking mostly affects medium-sized arterial structures, thromboangiitis obliterans (Buerger disease) is observed as both intimal and medial thickening of the endothelium. In the treatment of acute and chronic periods of diseases that cause vascular lumen

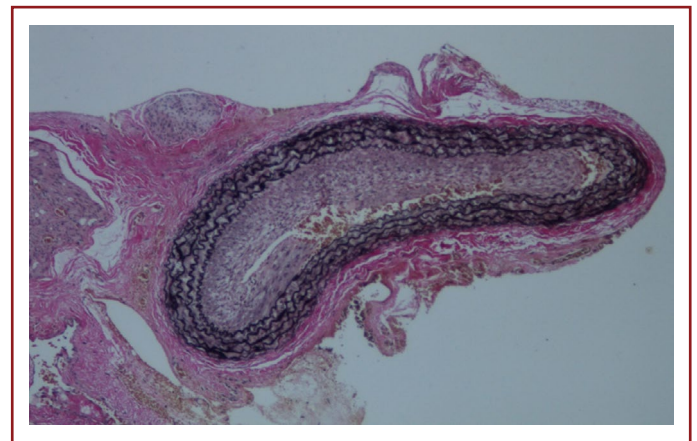


Figure 3. Group II: Thickened intima marked under elastic orcein staining, 500 μ m.

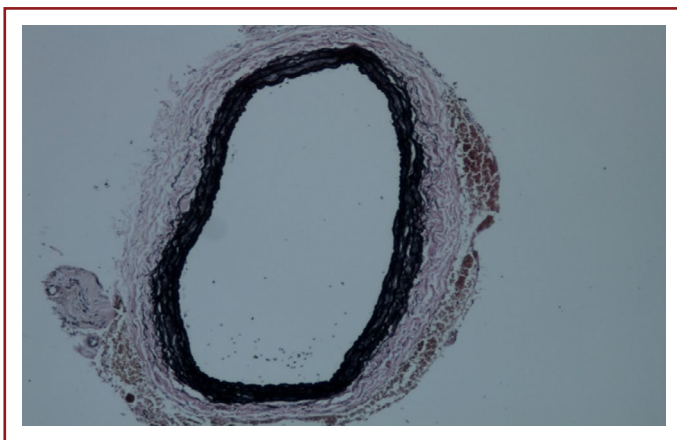


Figure 2. Group I: Intima, media, and adventitia under orcein staining, 500 μ m.

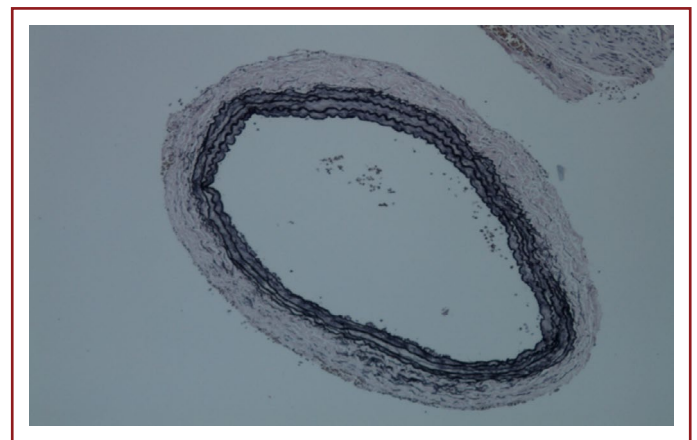


Figure 4. Group III: Transverse artery section image under orcein staining, 500 μ m.

Table 3. Statistics for intimal area thickness measurement

Groups	Mean (average)±standard deviation		
Group 1	0.135±0.0292		
Group 2	0.196±0.0459		
Group 3	0.154±0.0407		
	Group 1–Group 2	Group 1–Group 3	Group 2–Group 3
p	p<0.031	p>0.05	p<0.031

Table 4. Statistics for artery intima/media area thickness ratio measurement

Groups	Mean (average)±standard deviation		
Group 1	0.776±0.277		
Group 2	1.062±0.195		
Group 3	0.808±0.137		
	Group 1–Group 2	Group 1–Group 3	Group 2–Group 3
p	p<0.043	p>0.005	p<0.043

obstruction and endothelial thickening embolectomy and revascularization with the use of graft is frequently used. The cause of the damage is embolectomy balloon catheter application and traumatization of the endothelium during graft anastomosis. During these operations, the response of the artery wall layer intima to endothelial damage is subendothelial fibroproliferation and neointimal formation. Although this intimal response is the result of post-traumatic vascular repair, in some cases it can be too severe. The most important cause of graft occlusion after embolectomy and graft anastomose in the first 1 month is neointimal hyperplasia. After the 1st year, the most important reason is atherosclerotic changes. Based on the known physiopathological properties of restenosis, many pharmacological agents to prevent this process have been tested and actively implemented in animal models and humans. However, more combined treatments are needed today as a definitive effective treatment method for preventing intimal hyperplasia has not been fully found^[6]. In our study, we investigated the effect of cilostazol to prevent the development of neointimal hyperplasia after endothelial damage due to trauma, so rats that were used in our experimental study were subjected to normal nutrition and were not fed a cholesterol-rich diet. In our study, we used older animals as subjects, and chose male rats as gender because they were more fatty and overweight. We watched the experiment group in single cages so that rats could take equal and fully effective doses, and we calculated the water they drank as

cc and allowed them to finish it within a certain period of time. In addition, cilostazol was calculated according to daily kilogram as a melt in the water of rats as solution due to the fact that the daily use of cilostazol is oral tablets. The critical role here is endothelial cell integrity. Any event that disrupts the endothelial surface results in the migration of the smooth muscle cells and intimal thickening, which begins to proliferate in the media. While these cells continue proliferation on the one hand, on the other hand they synthesize and heal extracellular matrix elements^[13,14]. Growth factors in mitogenic properties initiate smooth muscle cell proliferation^[14]. Although this intimal response is the result of post-traumatic vascular repair, in some cases it can be too severe. Cilostazol is known to have positive effects on many atherosclerotic vascular diseases. Numerous studies have been done in terms of the effect of cilostazol on peripheral artery diseases, and studies have shown that cilostazol is indicated in treatment in peripheral artery disease, mostly in terms of maximum walking distance. Cilostazol has been shown to have antiproliferative effects, anti-thrombotic effects on platelets, endothelial protective effects, and modification of lipid profiles, especially on smooth muscle cells. It has also been shown to be protective against vascular damage since it inhibits platelet adhesion, aggregate, and smooth muscle cell proliferation. Our goal is to show restenosis that occurs into lumens rather than cell proliferation from the media, and to prevent intimal thickening by cilostazol.

Ethics Committee Approval: Pamukkale University Animal Experiments Ethics Committee. Project no PAUHDEK-2011/044 - 31/10/2011.

Peer-review: Externally peer-reviewed.

Authorship Contributions: Concept: P.K., H.M.A., A.V.Ö.; Design: H.M.A., A.V.Ö., P.K.; Data Collection or Processing: H.M.A., P.K., A.V.Ö.; Analysis or Interpretation: H.M.A., P.K., A.V.Ö.; Literatur Search: H.M.A., P.K., A.V.Ö.; Writing: P.K., H.M.A., A.V.Ö.

Conflict of Interest: None declared.

Financial Disclosure: The authors declared that this study received no financial support.

References

1. Clowes AW. Pathological intimal hyperplasia as a response to vascular injury and reconstruction. In: Rutherford RB, editor. *Vascular Surgery*. 4th ed. Philadelphia: W.B. Saunders; 1995. p.285–93.
2. Zarins C, Glagov S. Artery wall pathology in atherosclerosis. In: Rutherford RB, editor. *Vascular Surgery*. 4th ed. Philadelphia: W.B. Saunders; 1995. p.204–22.
3. Mondy JS, Williams JK, Adams MR, Dean RH, Geary RL. Structural determinants of lumen narrowing after angioplasty in atherosclerotic nonhuman primates. *J Vasc Surg* 1997;26:875–83. [\[CrossRef\]](#)
4. Jackson CL. Animal models of restenosis. *Trends Cardiovasc Med* 1994;4:122–30. [\[CrossRef\]](#)
5. Kipshidze N, Dangas G, Tsapenko M, Moses J, Leon MB, Kutryk M, et al. Role of the endothelium in modulating neointimal formation: Vasculoprotective approaches to attenuate restenosis after percutaneous coronary interventions. *J Am Coll Cardiol* 2004;44:733–9. [\[CrossRef\]](#)
6. Mach F. Toward new therapeutic strategies against neointimal formation in restenosis. *Arterioscler Thromb Vasc Biol* 2000;20:1699–700. [\[CrossRef\]](#)
7. Nakamura T, Houchi H, Minami A, Sakamoto S, Tsuchiya K, Niwa Y, et al. Endothelium-dependent relaxation by cilostazol, a phosphodiesterase III inhibitor, on rat thoracic aorta. *Life Sci* 2001;69:1709–15. [\[CrossRef\]](#)
8. Igawa T, Tani T, Chijiwa T, Shiragiku T, Shimidzu S, Kawamura K, et al. Potentiation of anti-platelet aggregating activity of cilostazol with vascular endothelial cells. *Thromb Res* 1990;57:617–23. [\[CrossRef\]](#)
9. Tsuchikane E, Katoh O, Sumitsuji S, Fukuhara A, Funamoto M, Otsuji S, et al. Impact of cilostazol on intimal proliferation after directional coronary atherectomy. *Am Heart J* 1998;135:495–502. [\[CrossRef\]](#)
10. Ishizaka N, Taguchi J, Kimura Y, Ikari Y, Aizawa T, Togo M, et al. Effects of a single local administration of cilostazol on neointimal formation in balloon-injured rat carotid artery. *Atherosclerosis* 1999;142:41–6. [\[CrossRef\]](#)
11. Dawson DL, Cutler BS, Hiatt WR, Hobson RW 2nd, Martin JD, et al. A comparison of cilostazol and pentoxifylline for treating intermittent claudication. *Am J Med* 2000;109:523–30. [\[CrossRef\]](#)
12. Elam MB, Heckman J, Crouse JR, Hunninghake DB, Herd JA, Davidson M, et al. Effect of the novel antiplatelet agent cilostazol on plasma lipoproteins in patients with intermittent claudication. *Arterioscler Thromb Vasc Biol* 1998;18:1942–7. [\[CrossRef\]](#)
13. Wang Y, Bai L, Lin Y, Guan H, Zhu N, Chen Y, et al. Demonstration of an add-on effect of probucol and cilostazol on the statin-induced anti-atherogenic effects. *Histol Histopathol* 2014;29:1593–600.
14. Chanchaoenthana W, Leelahavanichkul A, Taratummarat S, Wongphom J, Tiranathanagul K, Eiam-Ong S. Cilostazol attenuates intimal hyperplasia in a mouse model of chronic kidney disease. *PLoS One* 2017;12:e0187872. [\[CrossRef\]](#)