

Comparison of Two Different Methods in the Removal of Oil-Based Calcium Hydroxide From Root Canal System: A Triple-Blinded Randomised Clinical Trial

 Momina Anis MOTIWALA,  Sheikh Bilal BADAR,  Robia GHAFOR

ABSTRACT

Objective: To compare the effectiveness of rotary master apical file (RMAF) with ultrasonic activation of endodontic file (UAF) in the removal of silicon oil-based calcium hydroxide (SOBCH) from the canal.

Methods: Ethical review committee approval and informed consent was obtained. 60 cases with necrotic teeth in which silicon oil-based intracanal medicament (Metapex) was to be placed were randomised in one of the two groups using sealed envelopes containing assignment codes for medicament removal: RMAF and UAF group. After standard protocol of coronal access, cleaning and shaping, silicon oil-based SOBCH was placed using a Lentulo spiral. A periapical radiograph was taken after SOBCH placement to check for adequate adaptation. On 7th day, after instrumentation and medicament removal according to respective group, a second radiograph was taken to evaluate the effectiveness. Effectiveness was calculated using a graded scale in which 0 and 1 are effective and 2 and 3 are ineffective cleaning. Teeth were statistically analyzed using the Mann Whitney U and Chi-square test.

Results: There was no statistically significant difference in the removal effectiveness of group RMAF and Group UAF at coronal ($P=0.74$) middle ($P=0.71$) and apical third ($P=0.68$). According to the graded score both techniques were equally effective in cleaning at all thirds of canal (RMAF=Apical: 1.09 ± 0.70 , Middle: 0.61 ± 0.80 , Coronal: 0.33 ± 0.48 and UAC=Apical: 1.00 ± 0.77 , Middle: 0.52 ± 0.74 , Coronal: 0.28 ± 0.46). Effectiveness of SOBCH removal using the two methods was not statistically significant between maxillary and mandibular teeth ($P=0.35$).

Conclusion: Both the removal methods, Ultrasonic activation of file and Rotary master apical file, for SOBCH were equally effective in all the thirds of canal. And none of the techniques were able to completely remove the SOBCH. Effectiveness of SOBCH removal using the two methods was not statistically different between maxillary and mandibular teeth.

Keywords: Adhesion failure, calcium hydroxide, clinical trial, intracanal medicament, metapex removal

Please cite this article as:
Motiwala MA, Badar SB, Ghafoor R. Comparison of Two Different Methods in the Removal of Oil-Based Calcium Hydroxide From Root Canal System: A Triple-Blinded Randomised Clinical Trial. *Eur Endod J* 2021; 6: 38-43

From the Department of Operative Dentistry (M.A.M., S.B.B.), Aga Khan University Hospital, Karachi, Pakistan; Department of Surgery (R.G. ✉ robia.ghafoor@aku.edu), Aga Khan University Hospital, Karachi, Pakistan

Received 15 July 2020,
Accepted 10 September 2020

Published online: 15 February 2021
DOI 10.14744/ej.2020.78941

This work is licensed under a Creative Commons Attribution-NonCommercial 4.0 International License.



HIGHLIGHTS

- Complete removal of calcium hydroxide especially the oil based formulation from the canals is important as it may interfere with sealer penetration, compromising the seal and ultimately resulting in failure of the root canal treatment.
- None of the techniques render the root canal completely clean.
- Our study compares the two common and successful medicament removal methods reported in literature and helps to determine that ultrasonic activation of file is comparable to rotary master apical file in practical/clinical setting as this study was in-vivo instead of other in-vitro studies.
- It was essential to establish an evidence based guideline and a trial was needed to determine the effectiveness of different methods.

INTRODUCTION

The objective of root canal treatment is the elimination of pain and infection through chemo-mechanical debridement followed by obturation of the root canal system (1). The elimination and control of microorganism during endodontic treatment is important because the presence of bacteroides is correlated with clinical symptoms in the affected teeth (2). Mechanical preparation of infected root canals can eliminate microorganisms, however, due to the complexity of root canal system some of the bacteria hide in isthmuses, apical delta, dentinal tubules and ramifications (1). Thus, the use of intracanal medicaments can eliminate these hidden

bacteria (3, 4). For selection of the ideal intracanal medicament, it is essential to determine which medicament can destroy microorganisms and neutralise their byproducts (5).

Calcium hydroxide [Ca(OH)₂] has been used as an intracanal medicament in necrotic teeth, endodontic conditions including apexification, apexogenesis, and after trauma to prevent or resolve external resorption (6). A study by Shuping et al. (7) quoted that root canal system was rendered 92.5% bacteria free after the use of Ca(OH)₂ as an intracanal medicament. It works by altering the bacterial cell walls and by denaturing a potent endotoxin, lipopolysaccharide, thereby rendering it less antigenic (8, 9). Its alkalinity (pH 12.5-12.8) (10) is attributed to its antimicrobial properties (11).

In spite of the success of Ca(OH)₂ as an intracanal medicament, several bacterial species, including *Enterococcus faecalis*, are reported to be resistant to complete eradication (3, 12). *Enterococcus faecalis* is often associated with primary endodontic failure and is difficult to remove during endodontic retreatment (13). For these cases use of Metapex (Meta Dental Corp. Ltd., Elmhurst, NY, USA), a silicone oil-based Ca(OH)₂ (SOBCH) paste containing 38% iodoform, is recommended as it better disinfects dentinal tubules infected with *E.faecalis* as opposed to calcium hydroxide alone (14).

However, before obturation, it is prudent to clean the canal from any remnants of intracanal medicament, as it has been found to be associated with decreased quality of root canal. It includes hindrance in the penetration of sealer into the dentinal tubules, thereby, decreasing adhesion of sealer with dentine resulting in leakage of root canal treated tooth (15). The residual intracanal medicament also results in interaction with zinc oxide eugenol-based sealer, forming calcium eugenolate (16). Moreover, it is also found to be associated with staining of tooth structure (17, 18).

There are various formulations available of Ca(OH)₂ which has either saline, or other potent medicaments mixed with it or addition of vehicles such as silicon oil (19). Considering the nature of oil-based Ca(OH)₂, it is difficult to remove from the canals and so there are a number of techniques to remove intracanal medicament completely from the canal including chemical methods, mechanical methods and lasers (20). Studies assessing ease of retrieval of SOBCH i.e Metapex showed that it was difficult to remove and ethylene diamine tetra acetic acid (EDTA) or NaOCl alone did not effectively remove Ca(OH)₂ from the canal (16, 21). Moreover, none of the irrigation technique was able to completely remove all traces of intracanal medicament (22). Kumar et al. (23) compared various techniques for the removal of SOBCH and was unable to find any technique that had removed more than 50 percent of the volume of intracanal medicament. Another study had compared various method for removal of oil-based Ca(OH)₂ and concluded that none of the technique was able to render canal completely clean, however, rotary and ultrasonic techniques significantly removed more Ca(OH)₂ (24).

All of the mentioned studies have been performed on extracted human teeth. Therefore, they are unable to make any justifiable inference for usage of these tested modalities on

patients. *In-vitro* setting does not mimic the true clinical conditions and the limitations to use rotary or ultrasonic instruments on extracted teeth are not closely depicted whereas a clinical study has all the factors affecting the results including the patient's oral health condition, saliva, tongue and retraction. A clinician's skill and instruments efficacy is realistic when a study is done *in-vivo*. Since the literature is unable to propose any single technique that effectively removes the SOBCH medicament from the canal in a clinical setting and all the previous studies were *in-vitro*, it warrants a clinical study. Since, Kenee et al. (24) had shown that rotary and ultrasonic techniques worked relatively better than other techniques, the current study aimed to evaluate both of these techniques to conclude which one is better when used intraorally.

The aim of this randomised controlled trial was to compare the effectiveness of rotary master apical file with ultrasonic activation of endodontic file in the removal of silicon oil based calcium hydroxide from the canal.

Null hypothesis

The rotary master apical file (RAMF) is similar to ultrasonic activation of endodontic files (UAF) in the removal of SOBCH from the canal.

MATERIALS AND METHODS

The present study is a parallel type triple-blinded, randomised clinical trial conducted at the Dental Clinics at our Hospital. The trial was in accordance to the Consolidated Standards of Reporting Trials (CONSORT) and registered at clinicaltrials.gov. (Nct04336709). After the approval from the institution's Ethical Research Committee (ERC#2019-0304-3229), the subjects were recruited from the pool of patients being referred to the Operative Dentistry Department of our Hospital for the treatment of necrotic teeth from July 2019 to March 2020.

The inclusion criteria was patients aged older than 18 years who presented for root canal treatment of single rooted necrotic teeth (diagnosis confirmed using cold and electric pulp test) with chronic apical periodontitis (lesion size >2.0x2.0mm on periapical digital radiograph) having canal curvature less than 25° (determined by Schneider's method). Pregnant, immunocompromised or patients with other systemic illness were excluded. Periodontally compromised or teeth unable to be isolated under rubber dam were also not part of the study.

Sample size was calculated by sample size calculator (sample size determination in Health studies, WHO). The study by Bhuyan et al. (25) reported that the mean percentage of remaining Ca(OH)₂ after using ProTaper rotary was 35.49±4.73 while after using ultrasonic activation the mean remaining percentage of Ca(OH)₂ was 25.82±6.72. Keeping the above difference at the level of significance (α) at 1% and power of study (1- β) at 99%, we needed at least 21 observations per group. In order to ensure the required sample of 42 at the end of the study and keeping in mind the dropouts, 60 subjects were enrolled for the study.

Participant recruitment, randomization and blinding

All subjects were recruited by one investigator (SBBB) who was not the part of data collection or assessment. Participa-

tion was voluntary after explanation and discussion of the risks, advantages and discomfort following the treatment procedure. Informed consent was obtained.

Patients falling in inclusion criteria were randomly assigned to one of the two groups using sealed envelopes containing assignment codes of SOBCH removal methods ie. rotary file or ultrasonic activation of file. Neither the patient nor the assessor or analyst was aware of the group allocation, however, due to the nature of intervention, the clinician carrying out the procedure was aware of the group. All participating investigators were trained on the case selection, assessment techniques, sample collection, data compilation sheets and their precise role in the study.

Clinical procedure

Endodontic procedure was performed by a single dentist not involved in the data collection. Standard protocol for root canal treatment was followed. Tooth was anaesthetised with local anaesthesia solution (2% lidocaine with 1:100,000 adrenaline) and then rubber dam was used to isolate the targeted tooth. After adequate access preparation, canal patency was obtained followed by working length determination on periapical radiograph using ISO 15K endodontic file within the canal. Optimum length was taken as 1 to 2 mm short of radiographic apex. All the canals were cleaned and shaped using ProTaper Next rotary file system (PTN, (Dentsply; Sirona, USA)) until X2 under copious irrigation with 5ml of 5.25% sodium hypochlorite solution (NaOCl). After canal preparation and adequate irrigation, canal was dried using absorbent paper followed by placement of SOBCH (Metapex, Meta Biomed, Korea) up to the working length using Lentulo spiral fillers. Periapical digital radiographs using a cone indicator were taken to check adaptability of intracanal medicaments. The access cavity was filled with a temporary filling, Cavit-G (3M ESPE AG, Seefeld, Germany). On the subsequent postoperative visit after 7 days, after removal of temporary restoration, the intracanal medicament was removed from the canals via one of the two techniques:

1. Irrigation with 5 ml of 5.25% NaOCl using a 27 gauge needle inserted to initial binding, after placement of the size 20 Hedstrom file to 1mm short of working length followed by ultrasonic (EMS, Nyon, Switzerland) activation of an endodontic file (UAF) without touching the walls and activated at power setting of 4 with NaOCl as the irrigant for 30 seconds.
2. Identical to 1, except a the master apical rotary file (ProTaper) (RMAF), rotating at 250 RPM was inserted to working length instead of using ultrasonic activation.

After each technique, the canals were irrigated with 5 ml of 5.25% NaOCl and then dried with paper points. Periapical digital radiographs were taken to evaluate the removal of intracanal medicament.

Two periapical radiographs (one after placing SOBCH and other after removal of SOBCH) were used for data collection. The clinical procedure was done by one member of the team (investigator A: M.A.M.) while the radiographs were assessed by the other investigator (investigator B: S.B.B.) who evaluated radiographs

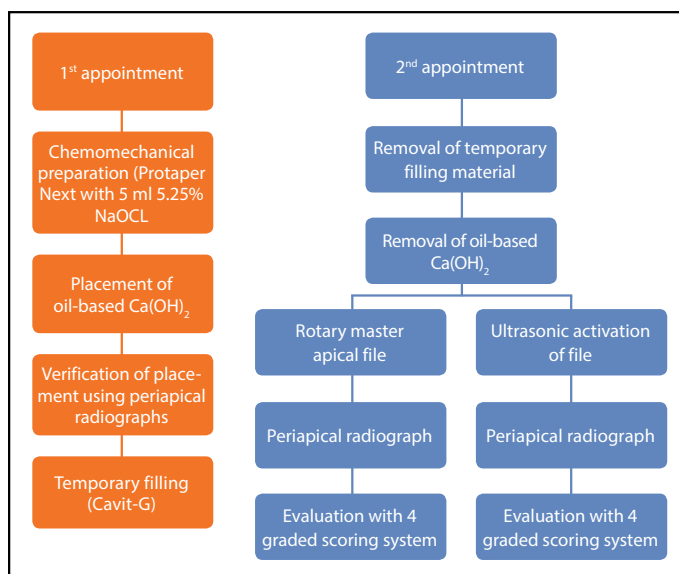


Figure 1. Protocol for evaluation and data collection

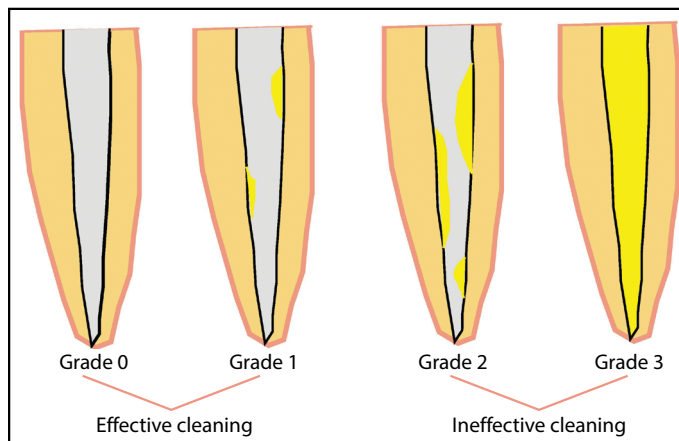


Figure 2. Grading for effectiveness of Ca(OH)_2 removal from root canals

in both the groups without knowing the study group. The protocol for data collection is summarised in Figure 1.

The outcome was evaluated radiographically using a four grade scoring system (26) (Fig. 2) to determine the effectiveness of removal of the two methods (Primary independent variable). The other variable recorded was the arch of the treated tooth. The remaining Ca(OH)_2 in the canal was calculated for each experimental group in three segments of each root canal (coronal, middle, and apical). The grade 0 means complete cleaning and 3 means inability to clean, so the investigators grouped the grade 0 and 1 and considered it as effective cleaning and 2 and 3 were grouped as ineffective cleaning for the ease of data collection and analysis.

For Grades 2 and 3 (ineffective cleaning), the intracanal medicament was removed using combination of techniques and irrigants in order to clean the canal completely and a final xray was repeated.

Ten radiographs were evaluated and graded again for evaluation of remaining intra canal medicament after an interval of one week to determine intraexaminer reliability.

Data analysis

SPSS version 23 was used for data analysis. Kolmogorov-Smirnov test was used to determine the distribution of data, which was found to be non-normal hence, nonparametric Mann Whitney U test was used to determine the difference between the two methods of medicament removal i.e UAF and RMAF at different surface levels. Chi-square was used to determine the association among variables like tooth location and technique for removal of intra canal medicament. Intraclass correlation coefficient was used to assess the intraexaminer reliability. Level of significance was kept at <0.01.

RESULTS

A total of 115 patients were analyzed out of which 55 were excluded because they either did not match the inclusion criteria, refused to participate or had other reasons. The trial included 60 patients of either gender, who were randomised in to two groups of 30 individuals each and received the intervention. From this, 11 were lost to follow up (6 from rotary group and 5 from ultrasonic group) and 7 were excluded due to fracture, failure or extraction of tooth. (3 from rotary group and 4 from ultrasonic group). A total of 42 patients were analysed in the end, 21 in each group. The present study is summarised in a CONSORT flow chart (Fig. 3). Of the 42 teeth, there were 22 incisors, 13 canines and 7 premolars.

The Intraclass Correlation Coefficient (ICC) came out to be 0.86 for intraexaminer reliability indicating good reproducibility of the results.

There was no statistically significant difference in the removal effectiveness of group RMAF and Group UAF at coronal (P=0.74) middle (P=0.71) and apical third (P=0.68) (Table 1).

Figure 4 shows the mean of scores graded on periapical radiographs after removal of medicament which reveals that both techniques were effective in cleaning at all thirds of

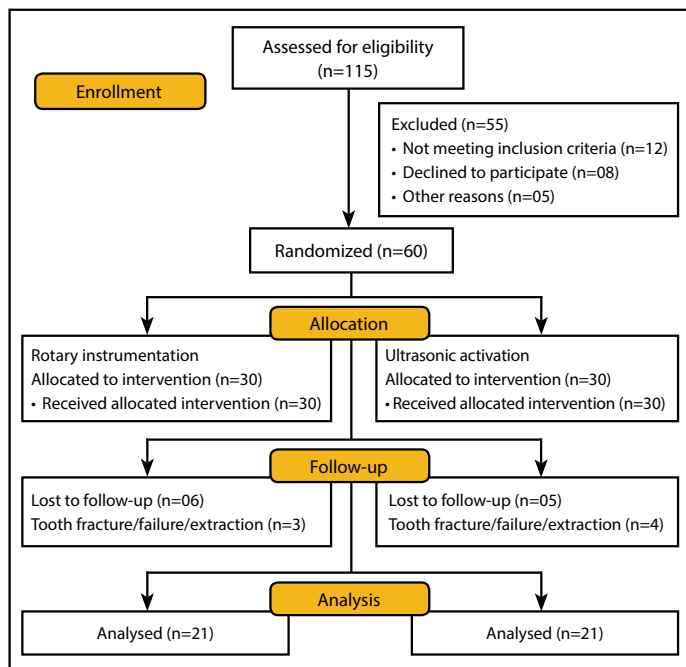


Figure 3. CONSORT Flow Diagram

TABLE 1. Comparison of oil-based Ca(OH)₂ removal methods at coronal, apical and middle thirds of root canals

	Removal method	n	Mean rank	Sum of ranks	P-value
Coronal third	Ultrasonic	21	21.00	441.00	0.74
	Rotary	21	22.00	462.00	
Middle third	Ultrasonic	21	20.88	438.50	0.71
	Rotary	21	22.12	464.50	
Apical third	Ultrasonic	21	20.79	436.50	0.68
	Rotary	21	22.21	436.50	

*P<0.01. Mann-Whitney U test

TABLE 2. Association between tooth arch and oil-based calcium hydroxide removal method

Removal method	Arch (n)		P-value
	Maxilla	Mandible	
Ultrasonic	12	9	0.35
Rotary	9	12	

*P<0.01. Chi square

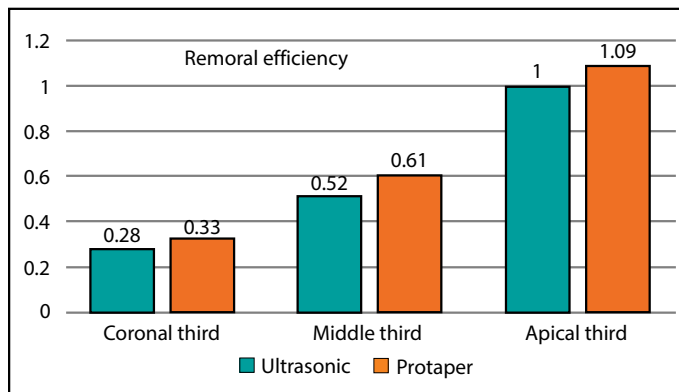


Figure 4. Mean scores after removal of oil-based calcium hydroxide

canal (RMAF=Apical: 1.09±0.70, Middle: 0.61±0.80, Coronal: 0.33±0.48 and UAC=Apical: 1.00±0.77, Middle: 0.52±0.74, Coronal: 0.28±0.46). Though the medicament was not completely removed from any third of the canal in both techniques, the apical third had comparatively greater residue than the coronal and middle third.

Effectiveness of SOBCH removal using the two methods was not statistically significant between maxillary and mandibular teeth (P=0.35) (Table 2).

DISCUSSION

Root canal disinfection is important to achieve a successful outcome in specially cases like of chronic apical periodontitis. Ca(OH)₂ being the most common intracanal medicament is used in such cases between the appointments (27). Oil-based Ca(OH)₂ was the intracanal medicament of choice for our trial as it is difficult to remove as compared to its aqueous formula-

tion and needs special measures (27). A study Bolhari et al. (28) reveals that inability to remove Ca(OH)_2 from the canal walls had destructive effects on the pushout bond strength (from 2.32 ± 1.43 to 0.947 ± 0.47) of Resilon/Epiphany sealers with adhesive failures being the most common reason for failure.

Several studies have evaluated the effectiveness of various intracanal medicament removal instruments and irrigants. Khaleel et al. (29) in their study suggests that sonic and ultrasonic activation of file removes more Ca(OH)_2 from the canal walls as compared to ProTaper rotary files in all thirds of canal ($P=0.0001$). This may be attributed to the fact that ultrasonic activation allows a small file to be oscillated creating acoustic streaming in the irrigation solution in a large prepared canal space, coming in maximum contact with the walls for removal of medicaments (30). In another study by Tamil et al. (31) ultrasonic activation of file was found to be the most effective technique for intracanal medicament removal leaving 0% of Ca(OH)_2 whereas rotary file left a maximum 70% of residue in the canal. On the contrary, the present study signifies that there is no difference in the effectiveness of removal of oil based Ca(OH)_2 between RMAF and UAF in all thirds of the canal.

The ProTaper rotary file used in the present study has positive rake angle improving its cutting efficiency, variable taper along its length, balanced pitch and helical angle to prevent screwing effect which may contribute to its improved effectiveness to remove oil-based Ca(OH)_2 from canal (32). A study by Agrawal et al. (33) showed rotary files to have better effectiveness as compared to ultrasonics in the removal of Ca(OH)_2 .

Comparatively, the intracanal medicament remnants were more in the apical than the coronal and middle third which is in line with the previous studies (24, 29, 31). This may be due to the irregular dentinal tubules, smaller canal area, anatomical complexity and constrictions of the apical third. In addition to this, the packing force when the files are inserted in the canal for medicament removal may plug Ca(OH)_2 apically making its removal difficult.

None of the studies determined the association between removal methods and tooth location in maxillary or mandibular arch. It can be assumed that the direct access and easy manipulation of mandibular teeth would yield better effectiveness in intracanal medicament removal in mandibular teeth but the present study did not signify any association with respect to tooth location.

The present study have used periapical digital radiographs to assess the remaining Ca(OH)_2 in the canals because of its low radiation dose, ease of availability, cheaper and simplicity of procedure than CBCT (34). Exposing the patient to 3D radiographs to evaluate removal of intracanal medicament did not seem to be justifiable as its main indication is for evaluation of complex endodontic conditions (35). Also, there is positive correlation between periapical radiography and direct visualisation for confirmation of medicament removal, thus making it the modality of choice (36).

In order to exclude factors such as canal shape, curvature, and its effect on the instrumentation and removal of medicament,

which might mislead our results, single rooted teeth with less than 25° root curvatures were taken according to the Schneider's method (37).

Myriad of studies have calculated and reported the remaining amount of Ca(OH)_2 on the canal walls using various methods, such as micro-computed tomography, CBCT, stereo microscopes and scanning electron microscopes (23, 25, 27, 38), but all of them were on extracted teeth which fails to mimic the conditions that exist in oral environment. This trial compares two techniques for removal of intracanal medicament in clinical setup so that the generated results are practical and applicable for clinical settings.

The limitation of current study is that 2D radiograph had been used for the analysis of effectiveness of intracanal medicament removal methods. There might be superimpositions, magnifications and due to its nature a minute remnant of Ca(OH)_2 might be perceived as more residual material but this small amount is less likely to have significant effect on the results (36). Also, this study compared only two instrumentation systems and more techniques should be compared to assess removal of oil-based Ca(OH)_2 . Moreover, different irrigation solutions with variable irrigation times, and concentrations could be compared in further studies.

Clinical implications

The study evaluates the effectiveness of the removal method which helps clinician to select the appropriate method to remove oil-based Ca(OH)_2 which is difficult to remove, leaving remnants and compromising adequate seal, ultimately improving 3-dimensional obturation seal and better success rates.

CONCLUSION

Within the limitations of the present study, both the removal methods for oil-based calcium hydroxide intracanal medicament were equally effective in all the thirds of canal. And none of the techniques were able to completely remove the oil-based Ca(OH)_2 . Effectiveness of Metapex removal using the two methods was not statistically different between maxillary and mandibular teeth.

Disclosures

Conflict of interest: No conflict of interest to disclose.

Ethics Committee Approval: This study was approved by the Aga Khan University Hospital Ethics Committee (ERC#2019-0304-3229).

Peer-review: Externally peer-reviewed.

Financial Disclosure: The authors declared that this study has received no financial support.

Authorship contributions: Concept – M.A.M.; Design – M.A.M., S.B.B.; Supervision – R.G.; Funding - R.G.; Materials - M.A.M., S.B.B.; Data collection &/or processing – M.A.M., S.B.B., R.G.; Analysis and/or interpretation – M.A.M., S.B.B., R.G.; Literature search – M.A.M.; Writing – M.A.M., S.B.B.; Critical Review – R.G.

REFERENCES

- Hargreaves KM, Berman LH, Rotstein I. Cohen's pathways of the pulp. 11th ed. St. Louis, Missouri: Elsevier Health Sciences; 2016.
- Sundqvist G, Johansson E, Sjögren U. Prevalence of black-pigmented bacteroides species in root canal infections. *J Endod* 1989; 15(1):13–9.

3. Bystrom A, Claesson R, Sundqvist G. The antibacterial effect of camphorated paramonochlorophenol, camphorated phenol and calcium hydroxide in the treatment of infected root canals. *Endod Dent Traumatol* 1985; 1(5):170–5. [\[CrossRef\]](#)
4. Gomes BP, Lilley JD, Drucker DB. Variations in the susceptibilities of components of the endodontic microflora to biomechanical procedures. *Int Endod J* 1996; 29(4):235–41. [\[CrossRef\]](#)
5. Valera MC, de Moraes Rego J, Jorge AO. Effect of sodium hypochlorite and five intracanal medications on *Candida albicans* in root canals. *J Endod* 2001; 27(6):401–3. [\[CrossRef\]](#)
6. Walton RE, Holton IF Jr, Michelich R. Calcium hydroxide as an intracanal medication: effect on posttreatment pain. *J Endod* 2003; 29(10):627–9.
7. Shuping GB, Orstavik D, Sigurdsson A, Trope M. Reduction of intracanal bacteria using nickel-titanium rotary instrumentation and various medications. *J Endod* 2000; 26(12):751–5. [\[CrossRef\]](#)
8. Safavi KE, Nichols FC. Effect of calcium hydroxide on bacterial lipopolysaccharide. *J Endod* 1993; 19(2):76–8. [\[CrossRef\]](#)
9. Silva L, Nelson-Filho P, Leonardo MR, Rossi MA, Pansani CA. Effect of calcium hydroxide on bacterial endotoxin in vivo. *J Endod* 2002; 28(2):94–8.
10. Mohammadi Z, Dummer PM. Properties and applications of calcium hydroxide in endodontics and dental traumatology. *Int Endod J* 2011; 44(8):697–730. [\[CrossRef\]](#)
11. Gordon TM, Ranly DM, Boyan BD. The effects of calcium hydroxide on bovine pulp tissue: variations in pH and calcium concentration. *J Endod* 1985; 11(4):156–60. [\[CrossRef\]](#)
12. Haapasalo M, Orstavik D. In vitro infection and disinfection of dental tubules. *J Dent Res* 1987; 66(8):1375–9. [\[CrossRef\]](#)
13. Sundqvist G, Figdor D, Persson S, Sjögren U. Microbiologic analysis of teeth with failed endodontic treatment and the outcome of conservative re-treatment. *Oral Surg Oral Med Oral Pathol Oral Radiol Endod* 1998; 85(1):86–93. [\[CrossRef\]](#)
14. Cwikla SJ, Bélanger M, Giguère S, Progulske-Fox A, Vertucci FJ. Dentinal tubule disinfection using three calcium hydroxide formulations. *J Endod* 2005; 31(1):50–2. [\[CrossRef\]](#)
15. Calt S, Serper A. Dentinal tubule penetration of root canal sealers after root canal dressing with calcium hydroxide. *J Endod* 1999; 25(6):431–3.
16. Margelos J, Eliades G, Verdelis C, Palaghias G. Interaction of calcium hydroxide with zinc oxide-eugenol type sealers: a potential clinical problem. *J Endod* 1997; 23(1):43–8. [\[CrossRef\]](#)
17. Kahler B, Rossi-Fedele G. A review of tooth discoloration after regenerative endodontic therapy. *J Endod* 2016; 42(4):563–9. [\[CrossRef\]](#)
18. Chen BK, George R, Walsh LJ. Discoloration of roots caused by residual endodontic intracanal medicaments. *ScientificWorldJournal* 2014; 2014:404676. [\[CrossRef\]](#)
19. Estrela C, Pécora JD, Souza-Neto MD, Estrela CR, Bammann LL. Effect of vehicle on antimicrobial properties of calcium hydroxide pastes. *Braz Dent J* 1999; 10(2):63–72.
20. Kourti E, Pantelidou O. Comparison of different agitation methods for the removal of calcium hydroxide from the root canal: Scanning electron microscopy study. *J Conserv Dent* 2017; 20(6):439–44. [\[CrossRef\]](#)
21. Nandini S, Velmurugan N, Kandaswamy D. Removal efficiency of calcium hydroxide intracanal medicament with two calcium chelators: volumetric analysis using spiral CT, an in vitro study. *J Endod* 2006; 32(11):1097–101. [\[CrossRef\]](#)
22. Chou K, George R, Walsh LJ. Effectiveness of different intracanal irrigation techniques in removing intracanal paste medicaments. *Aust Endod J* 2014; 40(1):21–5. [\[CrossRef\]](#)
23. Kumar P, de Ataide IN, Fernandes M, Lambor R. A cone-beam computed tomography assessment of the efficacy of different irrigation devices for removal of silicone oil-based calcium hydroxide from root canal system. *J Conserv Dent* 2017; 20(2):68–71. [\[CrossRef\]](#)
24. Kenee DM, Allemang JD, Johnson JD, Hellstein J, Nichol BK. A quantitative assessment of efficacy of various calcium hydroxide removal techniques. *J Endod* 2006; 32(6):563–5. [\[CrossRef\]](#)
25. Bhuyan AC, Seal M, Pendharkar K. Effectiveness of four different techniques in removing intracanal medicament from the root canals: An in vitro study. *Contemp Clin Dent* 2015; 6(3):309–12. [\[CrossRef\]](#)
26. Khademi AA, Amini K, Ghodsian B, Zahed SM, Teymori F, Shadmehr E. Removal efficiency of calcium hydroxide intracanal medicament with Rinse-Endo system in comparison with passive ultrasonic irrigation, an in vitro study. *Dent Res J (Isfahan)* 2015; 12(2):157–60.
27. Raghu R, Pradeep G, Shetty A, Gautham PM, Puneetha PG, Reddy TV. Retrieval of calcium hydroxide intracanal medicament with three calcium chelators, ethylenediaminetetraacetic acid, citric acid, and chitosan from root canals: An in vitro cone beam computed tomography volumetric analysis. *J Conserv Dent* 2017; 20(1):25–9. [\[CrossRef\]](#)
28. Bolhari B, Shokouhinejad N, Masoudi A. The effect of calcium hydroxide on the bond strength of resilon/epiphany self-etch and assessment of calcium hydroxide removal techniques: an ex-vivo study. *J Dent (Tehran)* 2012; 9(2):150–5.
29. Khaleel HY, Al-Ashaw AJ, Yang Y, Pang AH, Ma JZ. Quantitative comparison of calcium hydroxide removal by EndoActivator, ultrasonic and ProTaper file agitation techniques: an in vitro study. *J Huazhong Univ Sci Technolog Med Sci* 2013; 33(1):142–5. [\[CrossRef\]](#)
30. van der Sluis LW, Versluis M, Wu MK, Wesselink PR. Passive ultrasonic irrigation of the root canal: a review of the literature. *Int Endod J* 2007; 40(6):415–26. [\[CrossRef\]](#)
31. Tamil S, Andamuthu SA, Vaiyapuri R, Prasad AS, Jambai SS, Chittrarasu M. A comparative evaluation of intracanal calcium hydroxide removal with hand file, rotary file, and passive ultrasonic irrigation: an in vitro study. *J Pharm Bioallied Sci* 2019; 11(Suppl 2):S442–5. [\[CrossRef\]](#)
32. Sanghvi Z, Mistry KU. Design features of rotary instruments in endodontics. *J Ahmedabad Dent Coll Hosp* 2011; 2:6–11.
33. Agrawal P, Garg G, Bavabeedu SS, Arora S, Moyin S, Punathil S. Evaluation of intracanal calcium hydroxide removal with different techniques: a scanning electron microscope study. *J Contemp Dent Pract* 2018; 19(12):1463–8. [\[CrossRef\]](#)
34. Mota de Almeida FJ, Knutsson K, Flygare L. The effect of cone beam CT (CBCT) on therapeutic decision-making in endodontics. *Dentomaxillofac Radiol* 2014; 43(4):20130137. [\[CrossRef\]](#)
35. American Association of Endodontists; American Academy of Oral and Maxillofacial Radiology. Use of cone-beam computed tomography in endodontics Joint Position Statement of the American Association of Endodontists and the American Academy of Oral and Maxillofacial Radiology. *Oral Surg Oral Med Oral Pathol Oral Radiol Endod* 2011; 111(2):234–7. [\[CrossRef\]](#)
36. Küçükaya Eren S, Aksel H, Parashos P. A novel model for testing the efficiency of removal of calcium hydroxide from complex root canal anatomies. *Aust Endod J* 2017; 43(1):5–10. [\[CrossRef\]](#)
37. Schneider SW. A comparison of canal preparations in straight and curved root canals. *Oral Surg Oral Med Oral Pathol* 1971; 32(2):271–5. [\[CrossRef\]](#)
38. Gupta R, Sharma H, Kumari RA, Prakash AC, Rai N, Jain L. Effectiveness of two techniques in removal of calcium hydroxide medicament from root canals: an in-vitro assessment. *J Clin Diagn Res* 2018; 12(7). [\[CrossRef\]](#)