



Keratositis Obturans

IMAGE

Satvinder Singh Bakshi

A 13-year-old male patient presented with pain and hearing loss in the right ear for 5 days. Examination revealed a brownish-white flaky mass surrounded by granulation tissue in the right external auditory canal. A provisional diagnosis of keratositis obturans was made, and the mass was removed under general anesthesia (Fig. 1a). Postremoval examination revealed erosion and granulation in the external auditory canal (Fig. 1b), and postoperative biopsy confirmed the diagnosis (Fig. 1c). The patient was started on antibiotics and steroid drops for 7 days and was asymptomatic 3 months postoperatively. Keratositis obturans is characterized by abnormal accumulation of desquamated keratin in the external auditory canal, leading to the occlusion and expansion of the bony portion of the canal. It is common in young patients and can be bilateral in 50% of the cases. The etiology may be linked to abnormal shedding of the epithelium and failure of cell migration from the surface of the tympanic membrane, leading to the accumulation of a mass (1, 2). The condition is more common in patients with bronchiectasis and chronic sinusitis and in smokers. The presentation is usually of severe ear pain and conductive deafness (2). Computer tomography typically demonstrates soft tissue plug in the external ear canal with an expansion of the osseous part. The differential diagnosis includes external auditory canal cholesteatoma and impacted cerumen (2, 3). Softening of the mass using sodium bicarbonate and glycerine solution followed by removal under anesthesia is the treatment of choice (3). Widening of the external auditory canal followed by skin grafting is rarely required. Prognosis is good; however, because recurrence is common, close follow-up of the patients is advised (1).

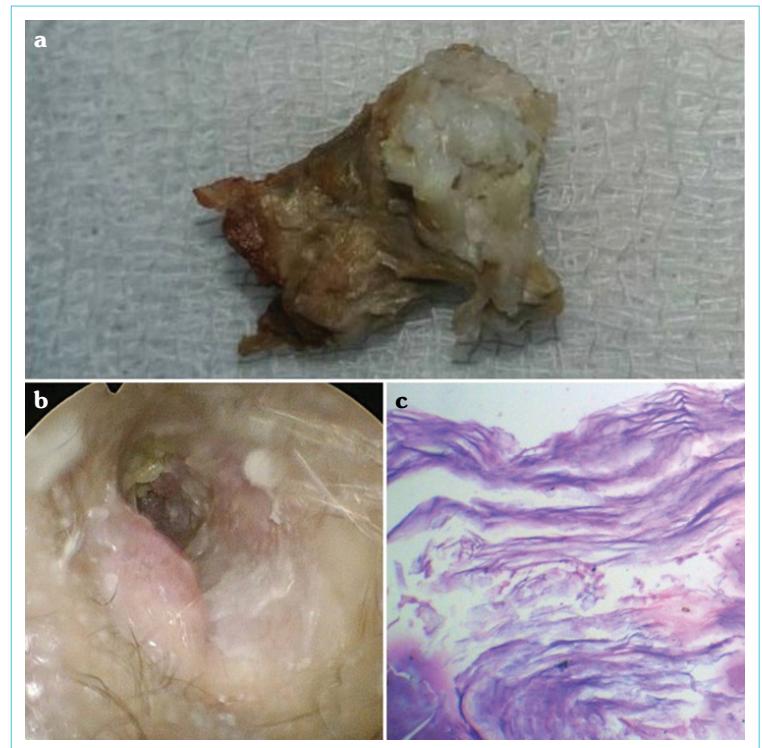


Figure 1. (a) Whitish flaky mass removed from the external auditory canal. (b) Postoperative picture showing granulation tissue and erosion of the external auditory canal. (c) Histopathological image revealing laminated flakes of keratin with chronic inflammatory infiltrate [HE, 40×]

Informed Consent: Written informed consent was obtained from patients who participated in this study.

Peer-review: Externally peer-reviewed.

Conflict of Interest: The author have no conflict of interest to declare.

Financial Disclosure: The author declared that this study has received no financial support.

Cite this article as:
Bakshi SS.
Keratositis Obturans.
Erciyas Med J 2023; 45(1):
113-4.

Department of ENT and Head
and Neck Surgery, All India
Institute of Medical Sciences
Mangalagiri,
Andhra Pradesh, India

Submitted
25.06.2022

Accepted
29.06.2022

Available Online
29.12.2022

Correspondence
Satvinder Singh Bakshi,
Department of ENT and Head
and Neck Surgery, All India
Institute of Medical Sciences
Mangalagiri,
Andhra Pradesh, India
Phone: +96 98420998
e-mail: saty.bakshi@gmail.com

©Copyright 2023 by Erciyas
University Faculty of Medicine -
Available online at
www.erciyesmedj.com

REFERENCES

1. Harounian JA, Patel VA, Isildak H. Contemporary management of keratosis obturans: a systematic review. *J Laryngol Otol* 2021; 135(9): 759–64.
2. Saniasiaya J, Nik Othman NA, Mohamad Pakarul Razy NH. Keratosis obturans complicated with facial nerve palsy: a diagnostic dilemma. *Braz J Otorhinolaryngol* 2020; 86(1): 130–2. [[CrossRef](#)]
3. Chen KW, Chen HC. Keratosis obturans of the external auditory canal with the complication of acute taste loss. *Ear Nose Throat J* 2022; 101(3): 148–9. [[CrossRef](#)]