

Idiopathic Atrophoderma of Pasini and Pierini

Çalka Ö.¹, Metin A.¹, Kösem M.²

Departments of Dermatology¹, and Pathology², School of Medicine, Yüzüncü Yıl University, Van, Turkey

Key words: *Atrophoderma, pasini and pierini*

Idiopathic atrophoderma of Pasini and Pierini (IAPP) is a rare and distinctive form of dermal atrophy of unknown etiology. The lesions may be single or multiple and round, oval or irregular in shape. They are gray-brown or bluish-brown colored and depressed below level of normal surrounding skin. Most commonly occurring on the back, they later appear on the chest and abdomen. The lesions may range in size from 1 to 20 centimeters in diameter and enlarge very slowly in years (1-3).

We present a 32 year-old man with a 13-year history of asymptomatic, depressed brownish lesion on his back histological examination of which revealed to be consistent with IAPP.

Case report

A 32-year-old man who had been suffering from skin lesion for 13 years applied to our clinic. He had a brownish plaque lesion on his back, approximately 12x7 cm in diameter in interscapular area (Figure 1). The plaque was moderately demarcated and depressed below the level of surrounding skin. Despite minimal induration, shining was not observed. He had no history of trauma, infection and injection. There were no itching, pain, burning and any other symptom.

Routine laboratory investigation and antibodies against *Borrelia burgdorferi* (IgM and IgG) showed no abnormality. A punch biopsy specimen was taken from the involved area. On histopathological examination, sections from the formaline-fixed dermal biopsy showed oedema in collagen bundles in mid and deep dermis, a few superficial dilated vessels, and perivascular infiltrate consisting of lymphocytes, a few macrophages and melanophages in the superficial dermis (Figure 2).

Discussion

IAPP which was referred to as 'idiopathic progressive atrophoderma' was first described in 1923 (2,4,5).

The cause of IAPP is unknown. In some cases genetic factors may seem to play a role such as C2 deficiency and some familial cases (1,4). The zosteriform distribution found in some cases that raises the possibility of neurogenic cause (6).

In one study, glycosaminoglycan content of the involved skin was determined and dermatan sulphate content in the involved skin was greater than that in the

uninvolved skin. These results may imply that abnormal metabolism of dermatan sulphate may play a role in the pathogenesis of IAPP (7).

In another study, direct immunofluorescent studies showed IgM and C3 deposition in the small blood vessels of papillary dermis and focal fibrinogen in the mid-dermis (8). Electron microscopic study demonstrated macrophages and lymphocytes around vessels and between collagen fibers in the mid-dermis, and monoclonal antibody studies of the cells in the perivascular infiltrate demonstrated cells reacting with T cell and macrophages (9). These results suggest that immunological factors may play a role in the pathogenesis of IAPP.

IAPP has an insidious onset in the second or third decade of life, and most patients are female (1,10). The lesions may be single or multiple, round, oval or irregular in shape. They are gray-brown or bluish-brown colored and depressed below level of normal surrounding skin. It commonly occurs on the back, later on the chest and abdomen. Involvement of proximal extremities, hands or feet is rare, and the face is spared (1,2,5,10-12). In some cases the lesions are located parallel to the skin markings and may coalesce into large and irregular plaques (10).

The lesions range in size from 1 to 20 centimeters in diameter and enlarge very slowly within 10 years or more, than, usually remain unchanged. In some lesions induration may occur secondary to sclerosis. The epidermis does not appear atrophic, markings are preserved and although decreased in number follicles are present (1,2,10,11). Our patient had one lesion on his back with a 13-year history (onset at 19-year old) without any symptoms, which remained unchanged for the last 3 years. This data is concordant with previous knowledge.

The histological changes are slight and variable. In the earlier stages the collagen in the lower dermis may be oedematous, and elastic tissue clumped and scanty. Perivascular infiltrate consisting of lymphocytes and macrophages and vascular ectasia may be observed in some cases. Later the oedema subsides and there is some reduction in the total thickness of the dermis. Collagen bundles appear clumped and occasionally hyalinised. The epidermis and subcutaneous tissue are not involved (1,10).

The relationship of IAPP to morphea is controversial. Some authors think that IAPP is a distinct entity because of early onset, longstanding course, absence of lilac margin and histologically clear sclerosis (2,4,5); others suggest that IAPP is a variant of morphea due to the likelihood of developing systemic sclerosis in some patients. Co-occurrence of IAPP and morphea has been reported (2-

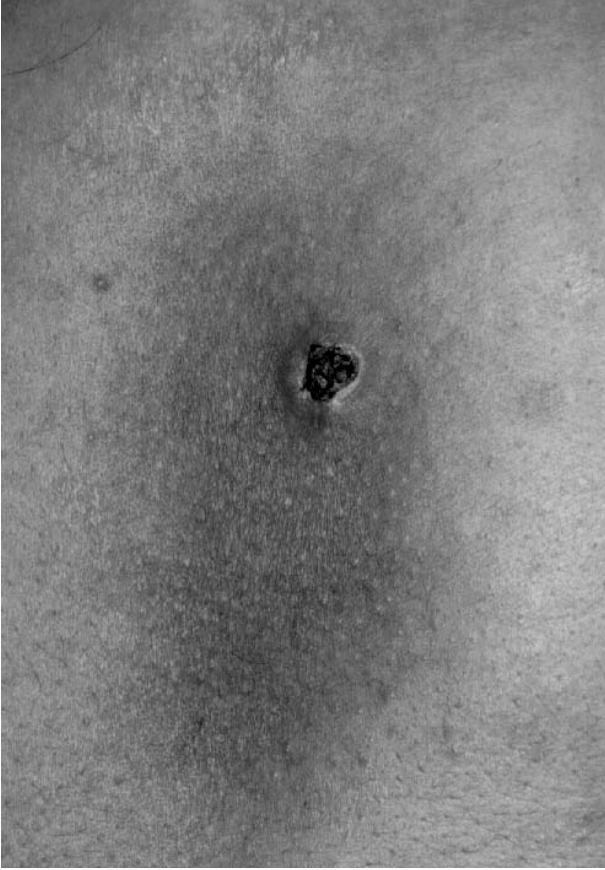


Figure 1. The brownish and depressed plaque plus crusting lesion which developed after punch biopsy on the back of patient.

5,10). Bruce et al. suggested that two types of atrophoderma occur; one as a separate idiopathic entity and the other as a variant closely related to morphea (10). In addition, analysis of glycosaminoglycan in IAPP patients showed that dermatan sulphate content in the involved skin was more than uninvolved skin, and this pattern has been observed in the systemic or localized scleroderma (7). Our patient's clinical features support the idea that IAPP is a distinct entity.

Some IAPP patients who had serum antibodies against *Borrelia burgdorferi* have been treated with oral antibiotics (3). In our patient antibodies against *Borrelia burgdorferi* (IgG and IgM) were not detected.

No effective treatment for IAPP is known. However, psoralen and UVA (PUVA), potassium benzoic acid and oral antibiotics may be helpful to some patients if *Borrelia burgdorferi* antibodies are elevated (1-3).

References

1. Burton JL, Lovell CR: Disorders of connective tissue: Cutaneous atrophy. In: Textbook of Dermatology (Eds: Champion RH, Burton JL, Burns DA, Breathnach SM): Blackwell Science Ltd London 1998, pp: 2003-2018.
2. Taştan HB, Kurumlu Z: İdiopatik atrofoderma Pasini Pierini. In XIIth Prof. Dr. A. Lütfü Tat Symposium Book. Ankara, 1995, pp: 23-28.
3. Beuchner SA, Ruffli T: Atrophoderma of Pasini and Pierini.

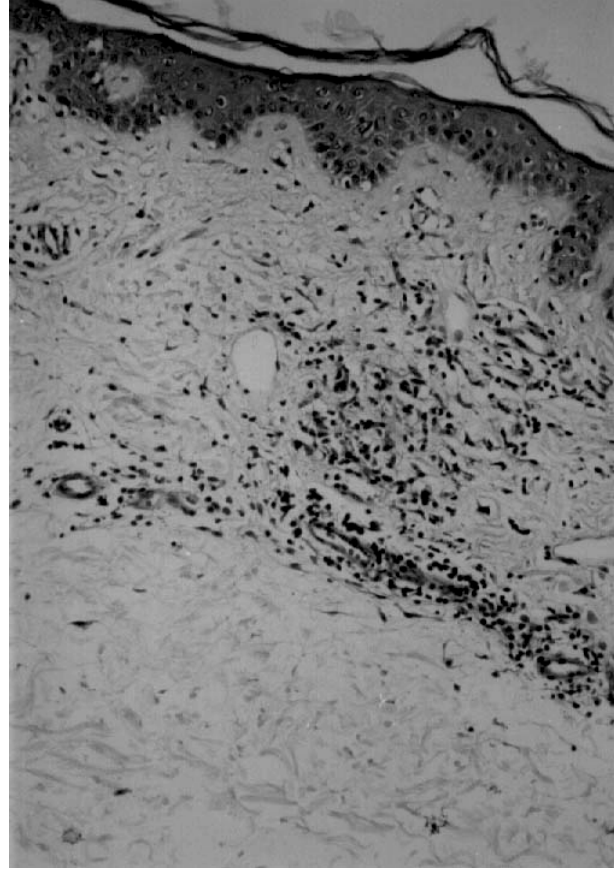


Figure 2. The collagen bundles in the dermis are oedematous and slightly homogenized in appearance. There is a perivascular infiltrate which consisting of lymphocytes, a few macrophages and melanophages. Some vessels are dilated (HEX50).

- Clinical and histopathologic findings and antibodies to *Borrelia burgdorferi* in 34 patients. J Am Acad Dermatol 30: 441-446, 1994.
4. Pullara TJ, Lober CV, Fenske NA: Idiopathic atrophoderma of Pasini and Pierini. Int J Dermatol 23: 643-645, 1984.
5. Şentürk M, Baysal V, Sarı A, Yıldırım M: Pasini ve Pierini'nin idiyopatik atrofoderması. Turk J Dermatopathol 7: 140-143, 1998.
6. Wakelin SH, James MP: Zosteriform atrophoderma of Pasini and Pierini. Clin Exp Dermatol 20: 244-246, 1995.
7. Tajima S, Sakurao K: A case of atrofoderma of Pasini and Pierini: analysis of glycosaminoglycan of the lesional skin. J Dermatol 22: 767-769, 1995.
8. Berman A, Berman GD, Winkelman RK: Atrophoderma (Pasini-Pierini). Findings on direct immunofluorescent, monoclonal antibody and ultrastructural studies. Int J Dermatol 27: 487-490, 1988.
9. Kernohan NM, Stankler L, Sewell HF: Atrophoderma of Pasini and Pierini. An immunopathologic case study. Am J Clin Pathol 97: 63-68, 1992.
10. Bruce S, Fretzin SD: Disorders of collagen, elastin and ground substance. In: Dermatology (Eds. Moschella SL, Hurley HJ). 3rd ed. WB Saunders Comp. Philadelphia 1992, pp: 1278-1279.
11. Karakayalı G, Artüz F, Allı N: Pasini ve Pierini'nin idiyopatik atrofoderması. T Klin J Dermatol 4: 190-192, 1994.

12. Pişkin S, Görgülü A, Öztürk A, Şeker V: Pasini ve Pierini atrofoderması. *Deri Hastalıkları ve Frengi Arşivi* 27: 212-213, 1993.

Correspondence:

Dr. Ömer Çalka
YYÜ Tıp Fakültesi Araştırma Hastanesi
Dermatoloji AD 65300 Van, TURKEY
e-mail: ocalka@hotmail.com