



DOI: 10.14744/eur.2023.39306
Eur Eye Res 2024;4(1):42–50

EUROPEAN
EYE
RESEARCH

ORIGINAL ARTICLE

Surgical approaches to juvenile open-angle glaucoma

 Yasemin Un,  Serhat Imamoglu,  Oksan Alpogan,  Ruveyde Bolac,  Merve Beyza Yildiz

Ophthalmology Clinic, Haydarpasa Numune Training and Research Hospital, Istanbul, Türkiye

Abstract

Purpose: To present the surgical options and surgical outcomes of juvenile open-angle glaucoma (JOAG).

Methods: A retrospective review of the case series with JOAG that had undergone surgical treatment was undertaken. Surgical techniques, patient characteristics, and surgical outcomes were analyzed.

Results: Thirteen eyes from eight patients with the diagnosis of JOAG were included in the study. The mean age was 26.77 ± 9.83 years. Five (62.5%) of the patients were male. The distribution of the operations was as follows: deep sclerectomy and external suture trabeculotomy in one eye (8%); Ahmed glaucoma valve implantation in one eye (8%); trabeculectomy with antimetabolite augmentation in five eyes (38%); and gonioscopy-assisted transluminal trabeculotomy (GATT) in six eyes (46%). The preoperative mean intraocular pressure (IOP) was 27.62 ± 7.17 mmHg, which decreased to 17.62 ± 13.06 mmHg at the last follow-up visit (36.21% decrease, $P = 0.023$, Wilcoxon rank test). IOP control was achieved without any additional surgical intervention in 10 (76.9%) eyes over the mean of 15.62 ± 12.17 months of the follow-up period. Further glaucoma surgery was required in three eyes, of which two had undergone GATT and one had undergone trabeculectomy as the primary surgery.

Conclusion: The surgical treatment of JOAG results in IOP reduction, and more than one surgery may be required in some cases.

Keywords: Ahmed glaucoma valve; gonioscopy-assisted transluminal trabeculotomy; juvenile open-angle glaucoma; trabeculectomy; trabeculotomy.

Juvenile open-angle glaucoma (JOAG) is defined as primary open-angle glaucoma (POAG) diagnosed in patients aged 3–40 years.^[1] JOAG is estimated to affect 0.7% of patients referred for glaucoma evaluation among Caucasians,^[2] while an investigation from a tertiary referral center in India reported JOAG to represent 3.3% of all glaucoma admissions.^[3] Although JOAG was previously considered an autosomal dominant disease, recent studies indicate a much more complex inheritance pattern.^[4,5]

Given its low prevalence, there is not as much data on JOAG as there is on POAG, or primary congenital glaucoma. JOAG is characterized by higher intraocular pressure (IOP) levels and rapidly progressive visual field loss compared to its adult-onset counterpart.^[6–9] Owing to the younger population being affected, the lifetime impact of JOAG is greater. JOAG is often refractory to medical therapy and frequently requires surgical interventions to achieve IOP control.^[1,5] Surgical interventions in JOAG provide



Cite this article as: Un Y, Imamoglu S, Alpogan O, Bolaç R, Yıldız MB. Surgical approaches to juvenile open-angle glaucoma. Eur Eye Res 2024;4:42–50.

Correspondence: Yasemin Un, M.D. Haydarpasa Numune Training and Research Hospital, Istanbul, Türkiye

E-mail: malkocyasemin@hotmail.com

Submitted Date: 21.06.2023 **Revised Date:** 01.08.2023 **Accepted Date:** 07.08.2023 **Available Online Date:** 20.03.2024

OPEN ACCESS This is an open access article under the CC BY-NC license (<http://creativecommons.org/licenses/by-nc/4.0/>).



IOP control by facilitating aqueous humor outflow.^[10] Trabeculectomy, angle surgery techniques such as goniotomy and trabeculotomy, minimally invasive glaucoma operations, and tube procedures are among the surgical interventions performed in JOAG.^[1]

In this paper, we present our experiences with JOAG patients who underwent surgical interventions in our tertiary referral glaucoma center.

Materials and Methods

This retrospective study was conducted with patients with JOAG referred to the glaucoma department of our eye clinic between January 2019 and December 2022. All patients were informed about the procedure, and their informed consent was obtained. The study was approved by the local ethics committee (registration code: HNEAH-KAEK 2023/74–4162). All study procedures adhered to the tenets of the Declaration of Helsinki. All glaucoma surgeries performed between January 2019 and December 2022 were reviewed. Patients with JOAG who underwent surgical intervention with or without prior glaucoma surgery were included in the study. Among all operations performed within this period, only 16 had the diagnosis of JOAG, and just 13 of them met the inclusion criteria. The diagnosis of JOAG was made based on the detection of glaucomatous optic neuropathy with corresponding visual field defects in patients aged 3–40 years who were found to have open-angle without any intraocular pathology

that led to the IOP rise. Eight patients (13 eyes) with JOAG who underwent glaucoma surgery were included in the study. A single glaucoma subspecialist (SI) performed the glaucoma surgery. Surgery was indicated in cases where the IOP was higher than the target IOP following maximal medical therapy, glaucoma progression was detected, or there were advanced glaucomatous changes. The surgeon decided on the type of operation depending on his surgical experience.

Inclusion Criteria

- All glaucomatous eyes with a JOAG diagnosis that underwent glaucoma surgery
- A follow-up duration of at least 6 months after surgery
- Available preoperative, operative, and postoperative patient data
- 90° or above goniotomy for patients who underwent Prolene suture gonioscopy-assisted transluminal trabeculotomy (GATT) or external trabeculotomy.

Exclusion Criteria

- A follow-up duration of <6 months
- Lower than 90° of goniotomy in the GATT group
- Presence of any intraocular inflammatory disease, diabetic retinopathy, maculopathy, or intraocular surgery other than glaucoma surgery.

The patients' characteristics and surgical operations are shown in Table 1.

Table 1. Patient characteristics, operations applied, and surgical outcomes

	Age (years)	Laterality	CDR	Surgery	Preop IOP (mm Hg)	Follow-up (months)	Last visit IOP (mm Hg)	Success
Patient 1	22	Right	0.8	Ds + ext trabeculotomy	28	12	14	1
		Left	0.2	trabeculectomy	34	12	14	1
Patient 2	12	Right	0.9	Trabeculectomy	40	40	33	0
		Left	0.7	Trabeculectomy	24	33	13	1
Patient 3	40	Left	0.9	Trabeculectomy	21	6	15	1
Patient 4	31	Left	0.9	GATT	20	6	10	1
Patient 5	21	Right	0.7	GATT	30	6	14	1
		Left	0.7	GATT	38	12	9	0 (trabeculectomy at 1st month)
Patient 6	35	Right	0.9	GATT	23	15	56	0
Patient 7	26	Right	0.9	Trabeculectomy	35	14	9	1
		Left	1	AGV	26	35	18	1
Patient 8	40	Right	0.9	GATT	20	6	12	1
		Left	0.9	GATT	20	6	12	1

CDR: Cup-to-disc ratio; Ds + ext trabeculotomy: Deep sclerectomy and external trabeculotomy; preop: Preoperative; IOP: Intraocular pressure; GATT: Gonioscopy-assisted transluminal trabeculotomy; AGV: Ahmed glaucoma valve.

Surgical Procedures

Trabeculectomy

The trabeculectomies were performed using the limbal-based approach. A sponge soaked in 0.2 mg/mL of mitomycin C was applied subconjunctivally for 3 min. After meticulous rinsing of the surgical area, a 3 × 4 mm-width, 2/3-thick scleral flap was created, and approximately 1 × 2 mm of sclerotomy was performed. Through the sclerotomy opening, full-thickness excision of the peripheral iris was undertaken. After the suturation of the two corners of the scleral flap using 10–0 nylon sutures, filtration was controlled by the infusion of balanced sodium solution through the side port, and if filtration was considered too much, additional scleral flap suturation was applied. The conjunctiva and tenon tissue were sutured using 8–0 Vicryl sutures.

GATT

GATT operations were performed using modified Swan Jacob lenses (Ocular Instruments, Bellevue, WA, USA). The patient's head was turned away from the surgeon while the operating microscope eyepiece was tilted 60° in the direction of the surgeon. After a 2–2.5-mm goniotomy was performed at the nasal side with a 23-gauge (G) non-bent MVR knife, a heat-blunted 6/0 Prolene suture was advanced through the Schlemm canal by repeatedly grasping, pushing, and re-grasping cycles with 23-G vitreoretinal forceps. When the distal end of the suture was seen in the goniotomy aperture, a 360° goniotomy was achieved by gently pulling the two ends of the suture together. In the case of unsuccessful 360° advancement through the canal, one proximal end of the suture was pulled, and the degree of goniotomy achieved was noted based on angle hemorrhage.

Ahmed's Glaucoma Valve (AGV)

In this study, there was one patient who underwent AGV implantation. During this procedure, AGV-FP7 (New World Medical, Inc., Rancho Cucamonga, CA, USA) was implanted at the superotemporal quadrant using the long scleral tunnel technique.^[11] The tube tip was positioned in the anterior chamber.

Deep sclerectomy and External Suture Trabeculotomy

One patient underwent a deep sclerectomy and external suture trabeculotomy with the limbal approach. After the subconjunctival application of 0.2 mg/mL of mitomycin C for 3 min and meticulous rinsing, a superficial scleral flap was created. Following deep scleral flap dissection and

deroofing of the Schlemm canal, successful 360° cannulation was performed using a heat-blunted 6/0 Prolene suture. By grasping the two ends of the suture and gently pulling the suture ends, a 360° trabeculotomy was performed. Then, the scleral flap corners and tenon-conjunctival tissue were sutured.

Outcome Measures

The data on demographics, baseline clinical characteristics, surgical procedures applied, follow-up durations, preoperative and last-visit glaucoma medications, and baseline and postoperative (1st day, 1st week, 1st month, 6th month, 1st year, 2nd year, and last visit) IOP measurements were obtained from the patient's medical records. Surgical success was defined as an IOP of >5 and <21 mmHg or at least a 20% IOP reduction without further glaucoma surgery. Surgical success ratios, the IOP decrease from the baseline to the last visit, the number of glaucoma medications, and changes from the baseline to the last visit were analyzed.

Statistical Analysis

All analyses were made using IBM SPSS Statistics Standard Concurrent User, v. 21.0 (IBM Corp., Armonk, New York, USA). The statistical significance level was accepted as $P < 0.05$. Frequencies and percentages were used for discrete variables, and mean ± standard deviation and median (interquartile range) values were used for continuous variables. Whether the continuous variables were normally distributed was examined using the Kolmogorov-Smirnov test. The Wilcoxon rank test was used for the comparison of time-dependent changes in continuous variables.

Results

A total of 13 eyes of eight patients were included in the study. Three (37.5%) patients were female, and five patients (62.5%) were male. The mean age of the patients was 26.77 ± 9.83 years. The mean best-corrected visual acuity (BCVA) was 0.40 ± 0.14 LogMAR. The mean cup-to-disc ratio (CDR) was 0.80 ± 0.05. The mean preoperative IOP was 27.62 ± 1.99 mmHg. The mean spherical equivalent of the eyes was -4.75 ± 3.36 diopters. All eyes were phakic. The demographic characteristics of the patients are shown in Table 2.

The distribution of surgical operations among the 13 eyes was as follows: deep sclerectomy and external suture trabeculotomy in one eye (8%), AGV implantation in one eye (8%), trabeculectomy with antimetabolite augmentation in five eyes (38%), and GATT in six eyes (46%) (Fig. 1). Of

Table 2. Patient and eye statistics

	Demographic variables
Age (mean±SD) (min-max) (years)	26.77±9.83 (12–40)
Sex	
Female	3 (37.5%)
Male	5 (62.5%)
Laterality	
Right	5 (38.5%)
Left	8 (61.5%)
BCVA (min-max) (LogMAR)	0.40±0.14 (0–1.5)
CDR (min-max)	0.80±0.05 (0.2–1)
SE (min-max)(diopters)	–4.75±3.36 (–12.00–0.25)
Preop IOP (min-max) (mmHg)	27.62±1.99 (20–40)
Follow-up (min-max) (months)	15.62±12.17 (6–40)

SD: Standard deviation; BCVA: Best-corrected visual acuity; SE: Spherical equivalent; CDR: Cup-to-disc ratio; IOP: Intraocular pressure.

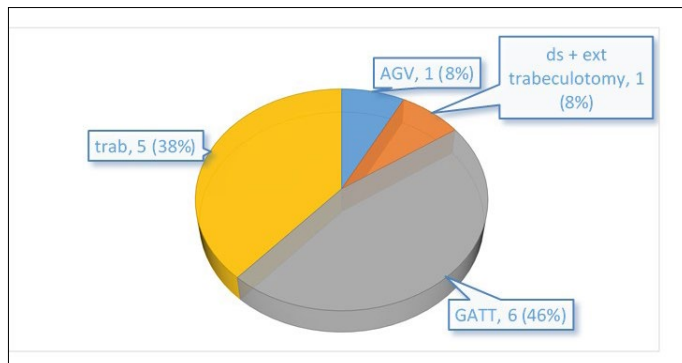


Fig. 1. Graphical demonstration of the distribution of surgical operations performed for JOAG. trab: trabeculectomy, AGV: Ahmed glaucoma valve implantation, ds + ext trabeculotomy: Deep sclerectomy and external trabeculotomy, GATT: Gonioscopy-assisted transluminal trabeculotomy.

the 13 surgical operations, 12 (92%) were performed under general anesthesia, and one was performed under subtenon anesthesia. Among the operations, all were primary operations except the AGV implanted eye, which had a previous trabeculectomy operation.

The overall mean preoperative IOP was 27.62±7.17 mm Hg, with the greatest change detected in IOP at the 1st month (50.95% decrease, P=0.003) and 6th month (53.76% decrease, P=0.001) postoperatively. The mean IOP at the last visit was 17.62±13.06 mmHg (36.21% decrease, P=0.023, Wilcoxon rank test). Figure 2 presents the IOP change curve for all surgical operations according to the follow-up time.

The graphical demonstration of the two most commonly applied surgical techniques, i.e., trabeculectomy and GATT, is given in Figure 3. The follow-up times of the two operations differed: 6–15 months for GATT and 6–40 months for trabeculectomy, and the last visit was also undertaken at different times in each group.

For GATT and trabeculectomy surgeries, the IOP measurements and P values for the comparison of preoperative and postoperative values are presented in Table 3. For GATT, a statistically significant decrease in the IOP from baseline was only detected in the postoperative 1st and 6th months. For trabeculectomy, the IOP reduction was statistically significant at all postoperative follow-up visits.

The IOP of the eye that underwent AGV implantation was 26 mmHg, 11 mmHg, and 8 mmHg preoperatively, postoperatively in the 6th month, postoperatively in the 1st year, and postoperatively in the 2nd year, respectively.

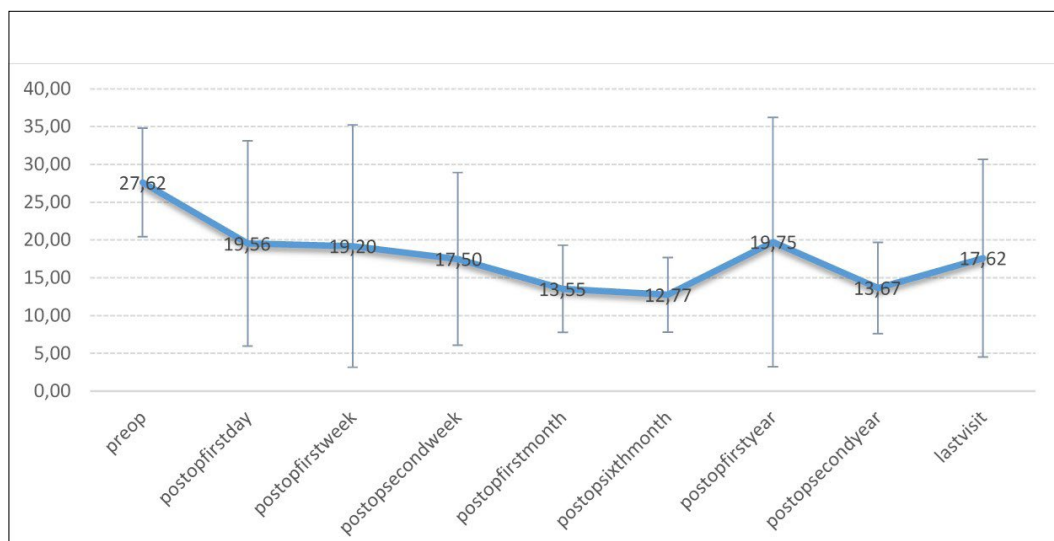


Fig. 2. Time-dependent intraocular pressure change curve after the surgical treatment of JOAG.

Table 3. IOP values and preoperative-postoperative IOP comparisons according to the surgery performed

	GATT IOP (mmHg) Mean ± SD (median)	n	P*-value	Trab IOP (mmHg) Mean ± SD (median)	n	P*-value
Preop	25.7±7.39 (21.5)	6		30.8±7.98 (34)	5	
Day1	28.75±15.65 (29.5)	4	0.999	10.25±4.27 (10,5)	4	0.068
Week 1	24.2±19.02 (12)	5	0.893	9±4.83 (7,5)	4	0.068
Week 2	27±13.23 (32)	3	0.999	13±5.77 (13)	4	0.068
Month 1	15.4±6.19 (13)	5	0.043**	11±5.39 (10)	5	0.043**
Month 6	10.5±2.66 (11)	6	0.027**	16.4±6.11 (19)	5	0.043**
Year 1	32.5±33.23 (32.5)	2	0.655	15.25±10.9 (11.5)	4	0.068
Year 2		0		16.5±4.95 (16.5)	2	0.043**
Last	18.83±18.29 (12)	6	0.344	16.8±9.34 (14)	5	0.180

*Preop versus others; **statistically significant (Wilcoxon rank test; $P < 0.05$) SD: Standard deviation; trab: Trabeculectomy; GATT: Gonioscopy-assisted transluminal trabeculectomy; IOP: Intraocular pressure.

The IOP of the eye that underwent deep sclerectomy and external suture trabeculectomy was 28 mmHg, 20 mmHg, 35 mmHg, 7 mmHg, 17 mmHg, 10 mmHg, and 14 mmHg at preoperative, postoperative, 1st day, 1st week, 2nd week, 1st month, 6th month, and 1st year, respectively.

All patients were using four antiglaucomatous medications preoperatively. At the last postoperative visit, the mean number of antiglaucomatous medications was 1.67 ± 1.53 (median: 2) (Wilcoxon rank test; $P = 0.003$). The last visit's mean BCVA was 0.49 ± 0.55 LogMAR. The change in BCVA was not statistically significant (Wilcoxon rank test, $P = 0.189$).

While 10 eyes (76.9%) of the 13 treated surgically fulfilled

the surgical success criteria, surgical success was not achieved in the remaining three eyes (23.1%). Two of the three eyes had undergone GATT and achieved IOP control with additional trabeculectomy surgery. The remaining eye was in the trabeculectomy group and treated with a second trabeculectomy, which also failed, and finally, transscleral cyclophotocoagulation was applied to control the IOP.

When the overall surgical complication distribution of the eyes with JOAG was examined, angle hemorrhage occurred in seven eyes (53.8%) intraoperatively, while hyphema was detected in two eyes (15.4%), hypotonia maculopathy in two eyes (15.4%), an IOP spike in three eyes (23.0%), and vascularized bleb formation in one eye (7.7%) in the

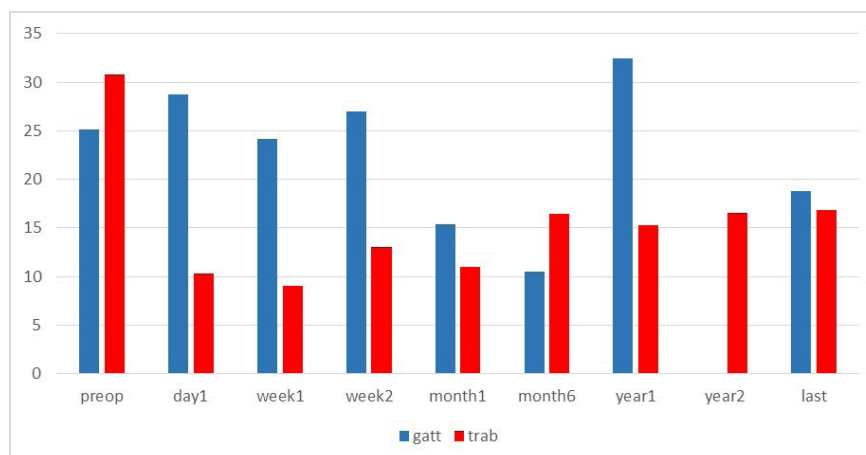


Fig. 3. Time-dependent mean IOP comparisons of the GATT and trabeculectomy surgeries. GATT: Gonioscopy-assisted transluminal trabeculectomy, trab: trabeculectomy.

postoperative period.

In the eye that underwent deep sclerectomy and external suture trabeculotomy, intraoperative angle hemorrhage and a postoperative IOP spike were detected. In the eye where AGV implantation was performed, no intraoperative or postoperative complications occurred. In the trabeculectomy group, no intraoperative complications were detected. In the postoperative period, early postoperative hypotony and hypotony maculopathy developed in two eyes, which were healed by conservative treatment in one eye and by blood injection into the bleb in the other eye within 2 months postoperative. A vascularized bleb formation and bleb failure despite two needling applications occurred in one eye, which further underwent a second trabeculectomy performed on the same eye 1 year later, and transscleral cyclophotocoagulation was required for IOP control. In the GATT group, intraoperative angle hemorrhage was present in all eyes, and the postoperative complications were micro-hyphema in two eyes and an IOP spike in two eyes.

Discussion

JOAG can be considered an intermediate form of glaucoma between POAG and congenital glaucoma, which possesses some diagnostic and therapeutic difficulties. JOAG is characterized by early disease onset and rapid progression.^[9] Since it is a rare disorder that does not present with early complaints, physicians do not usually suspect JOAG until later stages.^[9] However, the lifetime social, economic, and academic impacts of JOAG are comparable to those of POAG because the disease affects the young working population.

The estimated prevalence of JOAG is 0.7% in all admissions to glaucoma clinics among Caucasians.^[2] Elgin et al.^[12] investigated the refractive status and anterior segment parameters of patients with JOAG and healthy subjects and found the eyes with JOAG to be more myopic and have lower central corneal thickness and greater axial length and anterior chamber depth values. These anterior segment changes may be associated with myopia, which is common in JOAG. Moreover, Gupta et al.^[13] reported that JOAG had a greater baseline myopic refraction and that faster myopia development over time indicated glaucoma progression. In our cohort, we were able to investigate the refractive status and determine the mean spherical equivalent value to be -4.75 ± 3.36 diopters (-0.25 – -12.00), which is consistent with the results of Elgin et al.^[12] and the literature. Although we did not have data on the visual

field tests, we analyzed the CDR and found the mean value to be 0.80 ± 0.05 , which indicates moderate to advanced glaucoma.

Clinical evaluation and treatment options have been the subject of many studies related to glaucoma practice. In clinical practice, antiglaucoma medications play an important role in the management of JOAG. Saavedra et al.,^[14] who evaluated 36 eyes with JOAG, reported that all eyes were on at least one glaucoma medication (66.6% on one, 16.7% on two, and 16.7% on three medications). In our cohort, all eyes were on four medications preoperatively. Cimolai^[15] reviewed the adverse central nervous system effects of brimonidine in pediatric populations and observed somnolence, lethargy, apnea, and hypoventilation. We used brimonidine in all patients in our cohort because our cohort was composed of relatively older patients, with the youngest patient being 12 years old. After surgical procedures, the eyes with JOAG mostly require antiglaucomatous medications for adequate IOP control. In our case series, six of the 13 eyes were free of antiglaucomatous medications after surgical management (four after trabeculectomy and two after GATT).

While topical antiglaucomatous medications are beneficial, surgical management is typically required for adequate disease progression. Although there is conflicting research concerning the management of JOAG, surgery is generally indicated at some point in patients' lives. In a study examining the surgery requirement and antiglaucomatous medication use in severe glaucoma of different etiologies, Warjri et al.^[16] found that JOAG was controlled with medication alone in only two (11.76%) of 17 eyes, while nine (52.94%) eyes required surgery, and six (35.29%) required surgery and additional antiglaucomatous medication. In a study by Baig et al.,^[17] in which 22 pediatric eyes with JOAG were included, surgery or laser treatment was performed in 68% ($n = 15$) of the eyes: trabeculectomy with antimetabolites in 60%, goniotomy in 7%, non-penetrating deep sclerectomy in 7%, selective laser trabeculoplasty (SLT) in 13%, and argon laser trabeculoplasty in 13%. Chan et al.^[18] reported that 60% of 10 pediatric eyes with JOAG underwent glaucoma laser therapy or surgery, including SLT and EX-PRESS implantation. In a retrospective study conducted with 36 pediatric eyes with JOAG in Latin America, Saavedra et al.^[14] found that none of the eyes with JOAG required surgery. However, since that study included patients younger than 16 years of age and the median follow-up was 1.3 years, patients who subsequently required surgical treatment might have been overlooked. In contrast, our sample only consisted of JOAG cases that

were treated surgically. Since our clinic is a reference center, most admissions belong to more aggressive and advanced cases requiring surgical treatment; therefore, there are fewer patients with JOAG who are treated with medical therapy only. There are many surgical options for JOAG, with SLT, argon laser trabeculoplasty, trabeculectomy, deep sclerectomy, goniotomy, trabeculectomy, micro-invasive glaucoma surgery (MIGS), and glaucoma drainage devices being among the therapeutic lasers and surgical options used for the treatment of this condition.^[1]

Trabeculectomy is known to be effective in JOAG. Pathania et al.^[10] retrospectively reported the outcomes of trabeculectomy without mitomycin C augmentation in 60 eyes with primary JOAG. They determined the probability of qualified success to be 96% ($n = 36$, 95% confidence interval: 84–99%) at the end of 5 years. However, in a report by Yalvac et al.,^[19] the use of mitomycin C was found to improve the surgical success rate from 75% to 90% in JOAG. In our cohort, mitomycin C was used in all trabeculectomies. While the use of MMC improves surgical outcomes by controlling the fibrotic tissue reaction around the bleb that limits filtration, it has a higher incidence of early postoperative complications, including hypotonia and over-filtration, as well as late hypotonia and cystic bleb formation.^[20,21] We observed early over-filtration-related hypotonia and hypotony maculopathy in two eyes, which were resolved within 2 months postoperatively using conservative treatment in one eye and a blood injection into the bleb in the other eye. Of the trabeculectomized eyes, one (the right eye of patient 2) developed a vascularized bleb and bleb failure despite two needling applications, and a second trabeculectomy performed on the same eye 1 year later also failed in the second postoperative year; therefore, transscleral cyclophotocoagulation was required for IOP control.

Recent reports have revealed the results of MIGS, including GATT, catheter trabeculotomy, Kahook Dual Blade®, and Xen gel implant for JOAG. Wang et al.^[22] reported that GATT was effective in the treatment of 59 eyes with JOAG with and without prior glaucoma surgery. In that study, the mean IOP decreased from 26.5 ± 9.0 mmHg at baseline to 14.1 ± 2.3 mmHg at the postoperative 18th month, and the use of glaucoma medication decreased from an average of 3.7 ± 0.9 molecules preoperatively to 0.4 ± 0.8 molecules. In a study evaluating 56 eyes that underwent GATT, Salimi et al.^[23] reported that young age (18–39 years) was a predictive factor for surgical success, and localized pathology in the trabecular meshwork explained the success of GATT in these eyes. Rojas and Bohnsack^[24]

examined 360° catheter trabeculotomy and standard trabeculotomy in primary and secondary childhood glaucoma cases and evaluated whether complete drainage was achieved in 16 patients with JOAG who underwent a 360° trabeculotomy. They reported that the IOP decreased from 26.6 ± 7.8 mmHg preoperatively to 13.8 ± 2.8 mmHg postoperatively ($P < 0.001$), and the number of glaucoma medications used decreased from 3.1 ± 0.5 to 1.1 ± 1.2 ($P = 0.004$). Eleven (69%) of the 16 eyes with JOAG were reported to achieve 360° cannulation. At the last follow-up (mean: 3.9 ± 1.8 years), the success rate of IOP control with a 360° catheter trabeculotomy was 100%, while this rate was 67% for a 270–360° trabeculotomy and 50% for a standard trabeculotomy below 180°. Thus, the authors concluded that the canalization of Schlemm's canal using an illuminated microcatheter was successful in most JOAG cases. Khouri et al.^[25] reported the surgical success of the Kahook Dual Blade® in a 14-year-old male patient with JOAG. Klug and Solá-Del Valle^[26] reported successful bilateral XEN gel stent implantation in a 48-year-old woman with JOAG. In our cohort, six eyes underwent GATT, and one eye underwent a deep sclerotomy and an external suture trabeculotomy. Canalization was successfully performed at 360° in four of the six GATT operations, 270° in one, and 90° in one. The external suture trabeculotomy was also completed by 360° canalization. In one eye with 90° canalization at GATT surgery (left eye of patient 5), IOP control was achieved after trabeculectomy at the postoperative 6th week. In another eye (patient 4) with 270° canalization at GATT surgery, IOP was under control by the 6th postoperative month. The eye of patient 6 that underwent 360° GATT showed an early IOP spike and required trabeculectomy later due to the failure of the first procedure. In the eye of patient 1, in which a deep sclerotomy and an external 360° suture trabeculotomy were performed, the IOP was measured to be 12 mmHg at the postoperative 1st-year follow-up. Wang et al.^[22] reported micro-hyphema in 49%, macro-hyphema in 51%, an IOP spike in 48%, and varying degrees of ciliochoroidal detachment in 30% of patients with JOAG who underwent GATT. In our case series, intraoperative hyphema was seen in all patients who underwent GATT, and precipitating postoperative hemorrhage was noted in two of the six GATT operations and the external trabeculotomy performed in one patient. We observed a postoperative IOP spike in two eyes but no ciliochoroidal hemorrhage.

Recently, Le et al.^[27] revealed the 1st-year outcomes of Ahmed versus Baerveldt tube implantation for the treatment of 32 eyes in 25 patients with JOAG. They found the 1st-year failure rate to be 9.3% and the postoperative

complication rate to be 9.3%. The authors concluded that both implantation procedures had a 90.7% success rate at the end of 1 year. It is usually necessary to continue antiglaucoma medications to control the IOP after surgery. In our case series, AGV implantation was only performed on one eye (the left eye of patient 7) to control JOAG. This eye had a history of trabeculectomy failure, and AGV implantation provided IOP control without any complications over the 35-month follow-up.

Our study has some limitations. First, we worked with a very small sample. However, we were able to find this many patients by examining all glaucoma surgeries performed in a glaucoma reference center in the past 3 years. The reason for this is that JOAG is a rare disease, while another reason may be that some JOAG cases are followed without the need for surgery. Another limitation is the heterogeneity of the surgeries performed in our small sample. Due to the small size of our sample, the difference between the preoperative and last-visit IOP was not statistically significant in the analyses we performed on the eyes that underwent trabeculectomy and GATT surgeries, while the reduction in IOP indicates surgical success. However, the decrease in IOP was statistically significant when we included all eyes.

Conclusion

In conclusion, although JOAG is a rare disorder, it may have a great impact on the lives of patients. When surgical treatment is indicated for JOAG to control IOP and glaucoma progression, GATT, trabeculectomy, external suture trabeculotomy, and AGV implantations are among the preferred options. While surgical outcomes are mostly satisfactory, one procedure may not be adequate, subsequent operations may be required, and antiglaucomatous drugs are needed frequently.

Ethics Committee Approval: This study was approved by Haydarpaşa Numune Training and Research Hospital Ethics Committee (17.04.2023 date; number 2023/74).

Peer-review: Externally peer-reviewed.

Authorship Contributions: Concept: Y.Ü., S.İ.; Design: Y.Ü., S.İ.; Supervision: S.İ.; Resource: S.İ.; Materials: S.İ.; Data Collection and/or Processing: Y.Ü., O.A., R.B., M.B.Y.; Analysis and/or Interpretation: Y.Ü., O.A.; Literature Search: Y.Ü., R.B., M.B.Y.; Writing: Y.Ü.; Critical Reviews: S.İ., O.A., R.B., M.B.Y.

Conflict of Interest: None declared.

Use of AI for Writing Assistance: Not declared.

Financial Disclosure: The authors declared that this study received no financial support.

References

- Ciociola EC, Klifto MR. Juvenile open angle glaucoma: Current diagnosis and management. *Curr Opin Ophthalmol* 2022;33:97–102. [\[CrossRef\]](#)
- Goldwyn R, Waltman SR, Becker B. Primary open-angle glaucoma in adolescents and young adults. *Arch Ophthalmol* 1970;84:579–82. [\[CrossRef\]](#)
- Das J, Bhomaj S, Chaudhuri Z, Sharma P, Negi A, Dasgupta A. Profile of glaucoma in a major eye hospital in north India. *Indian J Ophthalmol* 2001;49:25-30.
- Gupta V, Somarajan BI, Gupta S, Chaurasia AK, Kumar S, Dutta P, et al. The inheritance of juvenile onset primary open angle glaucoma. *Clin Genet* 2017;92:134–42. [\[CrossRef\]](#)
- Turalba AV, Chen TC. Clinical and genetic characteristics of primary juvenile-onset open-angle glaucoma (JOAG). *Semin Ophthalmol* 2008;23:19–25. [\[CrossRef\]](#)
- Gupta V, Srivastava RM, Rao A, Mittal M, Fingert J. Clinical correlates to the goniodysgenesis among juvenile-onset primary open-angle glaucoma patients. *Graefes Arch Clin Exp Ophthalmol* 2013;251:1571–6. [\[CrossRef\]](#)
- Park SC, Kee C. Large diurnal variation of intraocular pressure despite maximal medical treatment in juvenile open angle glaucoma. *J Glaucoma* 2007;16:164–8. [\[CrossRef\]](#)
- Aponte EP, Diehl N, Mohny BG. Incidence and clinical characteristics of childhood glaucoma: A population-based study. *Arch Ophthalmol* 2010;128:478–82. [\[CrossRef\]](#)
- Kwon Y, Lee EJ, Han JC, Kee C. Clinical Characteristics of Juvenile-onset open angle glaucoma. *Korean J Ophthalmol* 2016;30:127–33. [\[CrossRef\]](#)
- Pathania D, Senthil S, Rao H, Mandal A, Garudadari C. Outcomes of trabeculectomy in juvenile open angle glaucoma. *Indian J Ophthalmol* 2014;62:224–8. [\[CrossRef\]](#)
- Kugu S, Erdogan G, Sevim MS, Ozerturk Y. Efficacy of long scleral tunnel technique in preventing Ahmed glaucoma valve tube exposure through conjunctiva. *Semin Ophthalmol* 2015;30:1–5. [\[CrossRef\]](#)
- Elgin U, Şen E, Uzel M, Yılmazbaş P. Comparison of refractive status and anterior segment parameters of juvenile open-angle glaucoma and normal subjects. *Turk J Ophthalmol* 2018;48:295–8. [\[CrossRef\]](#)
- Gupta S, Singh A, Mahalingam K, Selvan H, Gupta P, Pandey S, et al. Myopia and glaucoma progression among patients with juvenile onset open angle glaucoma: A retrospective follow up study. *Ophthalmic Physiol Opt* 2021;41:475–85. [\[CrossRef\]](#)
- Saavedra C, Rios HA, Belalcazar S, Rosenstiehl SM. Characteristics of pediatric glaucoma in a Latin American reference center. *J Curr Glaucoma Pract* 2020;14:10–5. [\[CrossRef\]](#)
- Cimolai N. A review of neuropsychiatric adverse events from topical ophthalmic brimonidine. *Hum Exp Toxicol* 2020;39:1279–90. [\[CrossRef\]](#)
- Warjri GB, Sidhu T, Kishan A, Behera AK, Shakrawal J, Selvan H , et al. Achieving low target intraocular pressures in severe glaucoma. *Eur J Ophthalmol* 2020;31:3068–73. [\[CrossRef\]](#)
- Baig NB, Chan JJ, Ho JC, Tang GC, Tsang S, Wan KH, et al.

- Paediatric glaucoma in Hong Kong: A multicentre retrospective analysis of epidemiology, presentation, clinical interventions, and outcomes. *Hong Kong Med J* 2021;27:18–26. [\[CrossRef\]](#)
18. Chan JC, Chow SC, Lai JS. Retrospective analysis of paediatric glaucoma at a tertiary referral centre in Hong Kong. *Jpn J Ophthalmol* 2021;65:115–21. [\[CrossRef\]](#)
 19. Yalvac IS, Nurözler A, Kahraman C, Kasim R, Duman S. The results of trabeculectomy with and without mitomycin C in young patients. *Ophthalmologica* 1998;212:399–403. [\[CrossRef\]](#)
 20. Bindlish R, Condon GP, Schlosser JD, D'Antonio J, Lauer KB, Lehrer R. Efficacy and safety of mitomycin-C in primary trabeculectomy: Five-year follow-up. *Ophthalmology* 2002;109:1336–41. [\[CrossRef\]](#)
 21. Küçük E, Abit MS, Karakurt A, Saricaoğlu MS. Management of hypotony after trabeculectomy with mitomycin C in a juvenile open angle glaucoma. *Glo Kat* 2014;9:288–90.
 22. Wang Y, Wang H, Han Y, Shi Y, Xin C, Yin P, et al. Outcomes of gonioscopy-assisted transluminal trabeculectomy in juvenile-onset primary open-angle glaucoma. *Eye (Lond)* 2021;35:2848–54. [\[CrossRef\]](#)
 23. Salimi A, Nithianandan H, Al Farsi H, Harasymowycz P, Saheb H. Gonioscopy-assisted transluminal trabeculectomy in younger to middle-aged adults: One-year outcomes. *Ophthalmol Glaucoma* 2021;4:162–72. [\[CrossRef\]](#)
 24. Rojas C, Bohnsack BL. Rate of complete catheterization of schlemm's canal and trabeculectomy success in primary and secondary childhood glaucomas. *Am J Ophthalmol* 2020;212:69–78. [\[CrossRef\]](#)
 25. Khouri AS, Zhu Y, Sadek H. Ab interno trabeculectomy with the dual blade in juvenile open-angle glaucoma. *Eur J Ophthalmol* 2021;31:NP43–5. [\[CrossRef\]](#)
 26. Klug E, Solá-Del Valle D. Bilateral XEN gel stent implantation in juvenile-onset open-angle glaucoma. *Case Rep Ophthalmol* 2020;11:336–41. [\[CrossRef\]](#)
 27. Le PH, Nguyen M, Humphrey KA, Klifto MR. Ahmed and Baerveldt Drainage implants in the treatment of juvenile open-angle glaucoma. *J Glaucoma* 2021;30:276–80. [\[CrossRef\]](#)