



DOI: 10.14744/eer.2022.83703
Eur Eye Res 2022;2(4):173–179

EUROPEAN
EYE
RESEARCH

ORIGINAL ARTICLE

Visual outcome of macular hole surgery based on pre-operative hole configuration in optical coherence tomography from a developing country-Nepal

Saurav Piya,¹ Sweta Singh,² Jeena Gurung,¹ Simanta Khadka,³
 Bikram Bahadur Thapa,⁴ Shanti Gurung⁵

¹Sudarshan Eye Care and Nursing Home, Gaur, Rautahat, Nepal

²Lumbini Eye Institute, Bhairahawa, Nepal

³Matrika Eye Centre, Kathmandu, Nepal

⁴Nepalgunj Medical College and Teaching Hospital, Nepalgunj, Banke, Nepal

⁵Birtamode Eye Hospital, Birtamode, Jhapa, Nepal

Abstract

Purpose: To predict the post-operative visual outcome considering the pre-operative factors and macular hole (MH) indices based on hole configuration in OCT.

Methods: Twenty-six eyes of 26 patients with full thickness MH (Stage II, III, and IV) were enrolled in this retrospective observational study between June 2017 and April 2019. Preoperative morphological parameters of MH such as base and minimum diameter, vertical height, left arm, and right arm length were calculated manually using the software in the cirrus optical coherence tomography (OCT) machine. MH Index (MHI), hole form factor (HFF), traction hole index, and diameter hole index were calculated and correlated with post-operative best-corrected visual acuity (VA) at last follow-up. 23-gauge pars plana vitrectomy, internal limiting membrane peeling with 12% C3F8 tamponade was performed in all patients and was followed up to 6 months postoperatively.

Results: The median value of patient's age, duration of symptoms, pre- and post-operative best corrected VA were 60 years, 9 months, 1.15 logMAR, 0.80 logMAR, similarly axial length, minimum hole diameter, base diameter of the MH, and central subfoveal macular thickness (CMT) were 22.8 mm, 646.5 μ m, 736.5 μ m, and 291 μ m, respectively. Post-operative visual outcome after MH surgery is better in patients with MHI ≥ 0.5 , HFF ≥ 0.9 , and CMT ≥ 300 μ m.

Conclusion: Pre-operative measurement of MH indices calculated from OCT images can be a prognostic factor in determining the post-operative visual outcome of MH surgery.

Keywords: Central subfoveal macular thickness; hole form factor; macular hole; macular hole index; visual outcome.

Pars plana vitrectomy (PPV) with internal limiting membrane (ILM) peeling is a widely used surgical modality for macular hole (MH) surgery. Post-operative achievement is ascribed to full removal of the posterior vitreous cortex




Cite this article as: Piya S, Singh S, Gurung J, Khadka S, Thapa BB, Gurung S. Visual outcome of macular hole surgery based on pre-operative hole configuration in optical coherence tomography from a developing country-Nepal. Eur Eye Res 2022;2:173-179.

Correspondence: Saurav Piya, M.D. Sudarshan Eye Care and Nursing Home, Gaur, Rautahat, Nepal

Phone: +977-9841347736 **E-mail:** sauravpiya@gmail.com

Submitted Date: 15.09.2022 **Revised Date:** 08.11.2022 **Accepted Date:** 11.11.2022

OPEN ACCESS This is an open access article under the CC BY-NC license (<http://creativecommons.org/licenses/by-nc/4.0/>).



along with the ILM and subsequent release of tangential vitreous traction which is the most commonly accepted cause of MH.^[1–9]

PPV with ILM peeling for full-thickness MH has reported primary closure rates of 76.4–100%.^[9] Despite considerable advances in surgical techniques to operate MHs, visual outcome differs even after the MH has been successfully closed.^[1,10] Based on recent case series of studies on MH, better visual outcome after surgery is related to young age, male gender, better baseline preoperative visual acuity (VA), shorter duration of symptoms, earlier staging of MH, small MH diameter, and successful hole closure.^[11–20]

Stereoscopic ophthalmoscopy makes it difficult to visualize the transverse image of the MH, thus other instruments such as optical coherence tomography (OCT) are being currently used to observe the structural changes in the morphology of MH in both pre-operative and postoperative patients. The OCT which is a non-invasive retinal mapping device enables quantitative assessment of MH deformation in a two-dimensional color map.^[21–23]

Various literatures on OCT image of quantitative parameters have been studied to predict MH post-operative vision in advance, such as MH index (MHI), traction hole index (THI), hole form factor (HFF), diameter hole index (DHI), minimum diameter (MD), and base diameter (BD).^[1,12] Extensive research has also been undertaken to study prognostic variables following MH surgery.^[24–27]

To predict post-operative visual outcome, we assessed several preoperative factors including patient's age, pre-operative VA, duration of symptoms, staging of Gass classification for MH and MHI, THI, HFF, DHI, and central sub-foveal macular thickness (CMT) of MH measured by OCT. The aim of this study was to assess the visual outcome improvement after MH surgery based on above parameters and check its usefulness as a visual prognostic factor. We believe that this prognostic indicator has specific role in lower resource setup like Nepal, where pre-operative predictive factors can help achieve the realistic expectation of patient as well as surgeon.

Materials and Methods

Patient's data were collected retrospectively by reviewing the surgical records of 26 consecutive patients (26 eyes) who underwent MH surgery at the department of Vitreoretina, Lumbini Eye Institute from June 2017 to April 2019. The permission for the study was granted by the institutional review committee (23 Nov, 2019, Ref No: 03/018/19) and adheres to the tenets of declaration of Helsinki.

The inclusion criteria for this study were: Gass Stages II, III, and IV full-thickness MH, standard 23-gauge PPV surgery with ILM peeling, and at least 6 months follow-up period following surgery. The study excluded eyes if they had pre-existing eye diseases (such as significant diabetic retinopathy, proliferative vitreo-retinopathy, age-related macular degeneration, advanced glaucoma, optic atrophy, and other diseases) that limit VA, prior intra-ocular surgical history with the exception of cataract surgery and MH with retinal detachment.

Pre-operative data included patient's age, gender, presenting complaints, etiology of MH, laterality, duration of symptoms, and presence of comorbid conditions. Patients were divided into four age subgroups: Group 1: ≤ 60 years; Group 2: 61–65 years; Group 3: 66–70 years; and Group 4: > 70 years. The duration of symptoms was divided into < 6 months and ≥ 6 months. All patients underwent comprehensive preoperative ophthalmological examinations including retinoscopy, uncorrected and best-corrected VA (BCVA) was documented using Snellen's chart which was then converted to LogMAR for analysis. Axial length was measured using Zeiss IOL master 500 (Zeiss Meditec, Germany) and intraocular pressure measured with Goldmann applanation tonometer, dilated fundus examination was carried out with slit lamp biomicroscopy and peripheral retina was checked with indirect ophthalmoscope with scleral depression. MHs were staged according to the Gass classification based on OCT examination. Cirrus HD-OCT 500 (Zeiss Meditec, Germany) cross-sectional horizontal scans of the MHs were imaged and measured manually by the software measuring tool in the OCT machine preoperatively by a single investigator for central retinal thickness, hole diameter at the level of retinal pigment epithelium (BD), minimum inner diameter of the hole (MD), maximum hole height from the retinal pigment epithelium to the vitreoretinal interface (hole height), left arm length and right arm length corresponding to the distance between the left and right edge of the base and MD, respectively.

We searched for a useful index based on the pre-operative MH configuration on OCT recordings. MHI was defined as the ratio of the hole height to the BD. THI is defined as the ratio of the hole height to the MD. HFF is defined as the ratio of the sum of the right and left arm length to the BD. DHI defined as the ratio of MD to BD (Fig. 1). These parameters were correlated with the post-operative BCVA.

Standard 23-gauge three port transconjunctival PPV was performed by a single surgeon. Posterior vitreous detachment was induced using triamcinolone acetonide (10

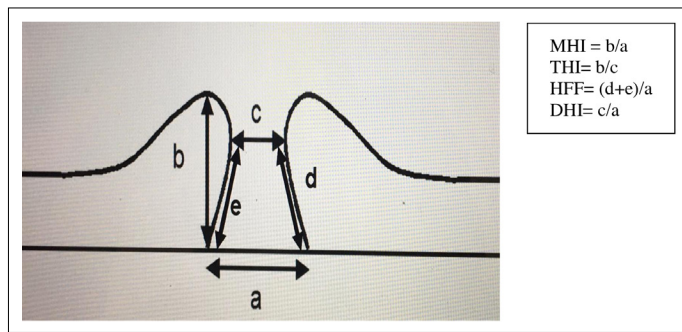


Fig. 1. Diagram showing various macular hole indices.

mg/mL) whenever necessary followed by removal of the residual thin premacular posterior cortex and peripheral vitreous. All of the eyes underwent ILM peeling after staining with 0.025% brilliant blue G dye. In all eyes, fluid-air exchange was performed followed by gas tamponade (12% C3F8). Patients were instructed to keep their head in prone position for at least 2 weeks after surgery. Patients were then examined on 1st postoperative day, then at 2 weeks, 2 months, and 6 months.

Statistical Analysis

Data were entered and analyzed with Statistical Package for the Social Sciences (SPSS) (Version 20, SPSS, IBM, Chicago, USA). Wilcoxon rank sum test was used to analyze comparisons between pre-operative and post-operative measurements. The Spearman coefficient and Kruskal–Wallis test were calculated to assess correlations between post-operative logMAR BCVA at last visit following surgery and the parameters that define the geometry of the MH and staging of MH respectively. Categorical variables were

compared by Pearson Chi-squared test. A p-value of less from statistical tests than 0.05 was considered statistically significant.

Results

Twenty-six eyes of 26 patients (10, 38.5% male; 16, 61.5% female) with full thickness MHs were included in this study. The median values of patients’ age, duration of symptoms, pre- and post-operative logMAR BCVA, axial length, minimum hole diameter, BD of the MH, and central sub foveal macular thickness were 60 years, 9 months, 1.15 logMAR, 0.80 logMAR, 22.8 mm, 646.5 μm, 736.5 μm, and 291 μm, respectively, with interquartile range of 14.25 years, 8 months, 0.4 logMAR, 0.4 logMAR, 0.89 mm, 281.25 μm, 364.75 μm, and 172 μm, respectively. The demographic characteristics of the patient’s age are shown in Table 1. Patients mostly presented with decreased vision 96.2% (25 eyes), followed by metamorphopsia 3.8% (one eye). Majority of MH were idiopathic 88.5% (23 eyes) whereas 11.5% (three eyes) had traumatic etiology. Male to female ratio was 1:1.6. Bilateral involvement was recorded in three patients of which two were females. According to Gass staging, 19.2% (five eyes) patients had Grade II, 53.8% (14 eyes) had Grade III, and 26.9% (seven eyes) had Grade IV MH. The Median MHI, HFF, THI, and DHI were 0.5, 0.72, 1.0, and 0.79 with interquartile range of 0.30, 0.28, 0.0, and 0.16, respectively.

Fifteen eyes (57.7%) of the total patients were presented at or before 60 years. All females presented before 66 years of age and 50% of the males presented after 65 years. This early presentation of females than males was statistically significant. (P=0.018, Pearson Chi-square) Table 2 represents the age group and the BCVA at the last follow-up visit.

Patients presented at or before 60 years had a better post-operative logMAR BCVA at last follow-up (6 months) which was not statistically significant. (P=0.032, Spearman correlation) Table 3 shows the comparative VA pre- and post-operatively as per WHO criteria for visual impairment. After surgery, 15.4% of eyes regained normal VA.

Table 1. Demographic characteristics of the patients

Age Range	Male (%)	Female (%)	Total (%)
≤60	4 (15.38)	11 (42.30)	15 (57.7)
61–65	1 (3.84)	5 (19.23)	6 (23.1)
66–70	2 (7.7)	0 (0)	2 (7.7)
>70	3 (11.5)	0 (0)	3 (11.5)
Total	10 (38.5)	16 (61.5)	26 (100)

Table 2. Post-operative logMAR BCVA according to age groups

Age group	BCVA at last follow-up at 6 months (logMAR unit)							Number of patients
	0.00	0.30	0.60	0.80	1.00	1.10	1.30	
≤60	1	3	2	3	4	0	2	15
61–65	0	0	2	2	1	1	0	6
66–70	0	0	0	1	0	0	1	2
>70	0	0	0	2	0	0	1	3
Total patient	1	3	4	8	5	1	4	26

logMAR: Logarithm of minimum angle of resolution; BCVA: Best corrected visual acuity.

Similarly, patients presented before 6 months had better post-operative logMAR BCVA at last follow-up which was statistically significant. (P=0.032, Spearman correlation). Table 4 shows post-operative VA and the duration of presenting symptoms.

At the last follow-up Gass classification of Stages II and III, FTMH had better visual outcome than Stage IV which was not statistically significant. (P=0.075, Kruskal–Wallis test). Table 5 shows the BCVA at the last visit with regard to MH grading as per Gass classification. Table 6 shows the correlation between hole indices and coefficient. MHI and HFF had positive but DHI had negative correlation with THI and all these variables were statistically significant.

Post-operative VA was better in the MHI group ≥ 0.5 compared to MHI group < 0.5 (Fig. 2). Post-operative VA was comparatively better in the HFF group ≥ 0.9 compared to HFF group < 0.9 (Fig. 3). Post-operative logMAR BCVA for

CMT $\geq 300 \mu\text{m}$ showed better visual outcome compared to CMT group $< 300 \mu\text{m}$ (Fig. 4).

Discussion

OCT analysis provides a better understanding of the geometry and features of MH. This study has evaluated the relationship between preoperative OCT parameters and indices in diagnosing and staging of MHs and predicting the postoperative visual outcome following surgery. The study has also considered other variables such as age, gender, duration of symptoms, and pre-operative VA.

Better pre-operative VA, younger age with shorter duration of symptoms showed better postoperative BCVA in the present study which is similar to the observations by Suda et al.^[28] and Kusuhara et al.^[23] Impaired neuro-regeneration, alterations in calcium homeostasis, reduced N-cadherin-dependent retinal regeneration and accumulation of macrophages in the sub-retinal or retinal pigment epithelium layers accounts for poor visual outcomes in ageing population.^[28]

Evaluation of MH configuration and sub-foveal macular thickness with OCT has provided useful information re-

Table 3. Pre-operative and post-operative vision according to the WHO VA category

WHO VA category	Pre-op BCVA group	Post-op BCVA at last follow up (6 months) visit
	n (%)	n (%)
6/6–6/18	0 (0)	4 (15.4)
6/24–6/60	12 (46.2)	17 (65.4)
5/60–3/60	5 (19.2)	5 (19.2)
2/60–1/60	9 (34.6)	0 (0)
Total	26 (100)	26 (100)

WHO: World health organization; VA: Visual acuity; BCVA: Best corrected visual acuity.

Table 6. Correlation between THI and other hole indices

Hole indices	Coefficient	P-value (Spearman correlation)
MHI	0.778	<0.001
HFF	0.654	<0.001
DHI	-0.433	0.027

THI: Traction hole index; MHI: Macular hole index; HFF: Hole form factor; DHI: Diameter hole index.

Table 4. Post-operative logMAR BCVA according to duration of symptoms groups

Duration of symptoms groups	BCVA at last follow-up at 6 months (logMAR unit)							Number of patients
	0.00	0.30	0.60	0.80	1.00	1.10	1.30	
<6 months	1	3	2	4	0	0	2	12
≥ 6 months	0	0	2	4	5	1	2	14
Total patient	1	3	4	8	5	1	4	26

logMAR: Logarithm of minimum angle of resolution; BCVA: Best corrected visual acuity.

Table 5. Post-operative logMAR BCVA according to Gass staging

Gass staging	LogMar BCVA at last follow-up visit							Number of patients
	0.00	0.30	0.60	0.80	1.00	1.10	1.30	
Grade II	1	1	1	1	1	0	0	5
Grade III	0	2	3	4	3	0	2	14
Grade IV	0	0	0	3	1	1	2	7
Total patient	1	3	4	8	5	1	4	26

logMAR: Logarithm of minimum angle of resolution; BCVA: Best corrected visual acuity.

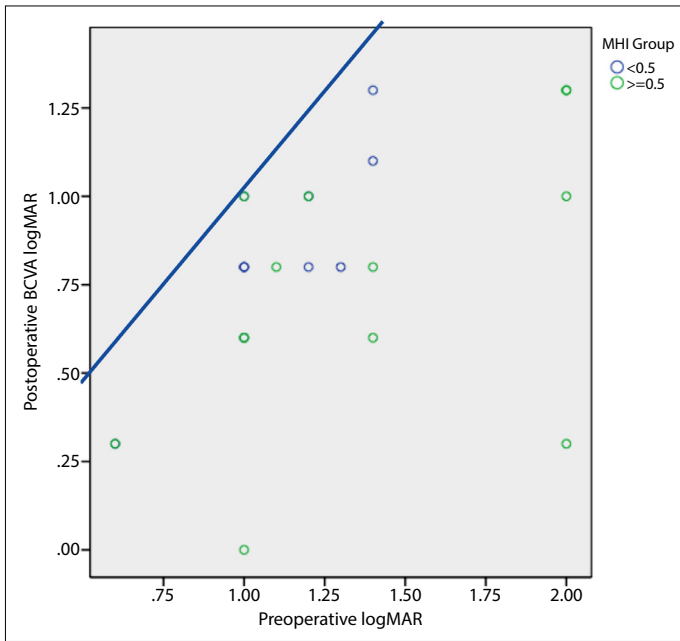


Fig. 2. Scatter plot demonstrates the relationship of pre-operative and post-operative log MAR BCVA (6 months) after macular hole surgery with MHI groups.

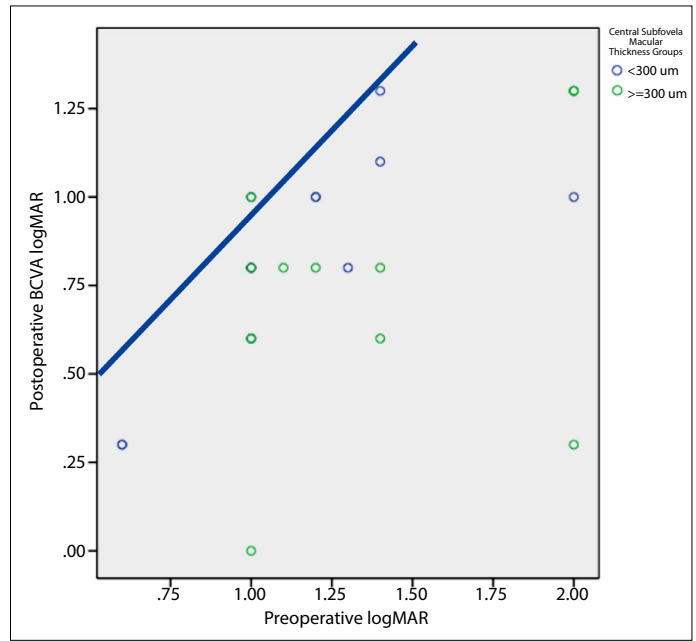


Fig. 4. Scatter plot demonstrates the relationship of pre-operative and post-operative log MAR BCVA (6 months) after macular hole surgery with central subfoveal macular thickness groups.

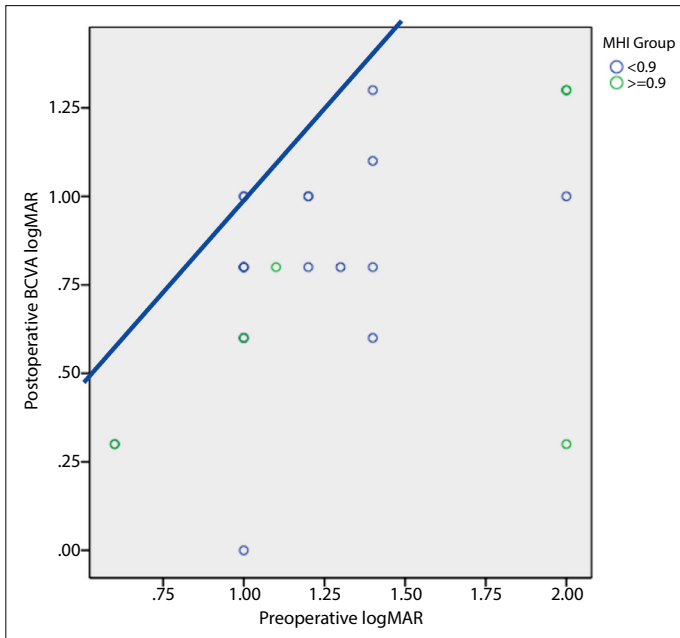


Fig. 3. Scatter plot demonstrates the relationship of pre-operative and post-operative log MAR BCVA (6 months) after macular hole surgery with HFF groups.

garding visual prognosis, which is supported by various other studies.^[4,11,19,23] We proposed MH indices such as MHI, HFF, THI, DHI, and central subfoveal macular thickness (CMT) that reflects the pre-operative macular deformation which could be used to predict the post-operative visual outcome.

This study showed that MHI values of ≥ 0.5 experienced a better postoperative VA compared to MHI values of < 0.5 which is comparable to the results by Kusuhara et al.^[23] Holes with greater MHI values represent eyes with limited preoperative macular deformation which can be benefited mostly from a PPV.

Puliafito et al.^[29] first created HFF and found 80% anatomical success rate in patients with HFF > 0.9 . In the study by Ullrich et al.,^[11] all patients with an HFF > 0.9 were operated successfully in the first approach with better anatomical success rate. In this study, post-operative VA was better in HFF ≥ 0.9 compared to HFF < 0.9 .

Shpak et al.^[30] revealed that the preoperative central subfield retinal thickness directly reflects the volume of tissues required to restore the foveal anatomy after surgery and is a strong predictor of anatomical results of MH surgery. It could predict both the anatomical closure of the hole and the restoration of the outer retinal structure. In our study, better post-operative VA was acquired by the patient whose CMT was $\ge 300 \mu\text{m}$ as compared to those with CMT $< 300 \mu\text{m}$. Hence, the reduction below this “reserve” volume is a significant unfavorable prognostic sign.

THI represents the relationship between the two tractional forces (antero-posterior vitreomacular traction and tangential traction) responsible for causation of MH and could be correlated closely with postoperative BCVA.^[28] In this study, a significant positive correlation was found between

THI, MHI, and HFF whereas a significant negative correlation was found with DHI. It indicates the strong role of tangential traction in MH formation and is directly related to the MD of the MH.

The limitation of this study are many; among them small sample size, short follow-up period following surgery and retrospective nature of the study are the major ones. Other shortcomings are a single center-based study and inclusion of surgery by a single surgeon with single technique. We believe that a study with larger population and different centers could help us support the statement for prognostic factors.

Conclusion

OCT facilitates an accurate diagnosis and staging of MH and based on its parameters it also helps in determining the anatomical outcome and functional prognosis preoperatively.

Several pre-operative factors such as younger age, early presentation, better pre-operative VA, and early Gass staging along with pre-operative measurement of MH parameters such as MHI ≥ 0.5 , HFF ≥ 0.9 , and CMT ≥ 300 μm on hole configuration calculated from macular OCT act as a prognostic factor for better post-operative visual outcome after MH surgery. Knowledge of these visual prognostic factors help the operating surgeon to counsel the patient in effective way with expectation of more realistic post-operative visual outcome.

Acknowledgement

We would like to express our very great appreciation to Gyanendra Lamichhane, M.D, Reeta Rajbhandari, M.D, Hari Thapa, Mahesh Aryal for their help in writing the manuscript.

Ethics Committee Approval: This study was approved by Lumbini Eye Institute Ethics Committee (date: 23.11.2019; number: 03/018/19).

Peer-review: Externally peer-reviewed.

Authorship Contributions: Concept: S.P.; Design: S.P.; Supervision: S.S., S.G.; Resource: S.P., B.B.T., S.G.; Materials: S.P., S.S.; Data Collection and/or Processing: S.P.; Analysis and/or Interpretation: S.P., B.B.T.; Literature Search: S.P., J.G., S.K.; Writing: S.P., J.G., S.K.; Critical Reviews: S.P., S.S., J.G., S.K., B.B.T., S.G.

Conflict of Interest: None declared.

Financial Disclosure: The authors declared that this study received no financial support.

References

- Smiddy WE, Glaser BM, Thompson JT, Sjaarda RN, Flynn HW Jr., Hanham A, et al. Transforming growth factor-beta 2 significantly enhances the ability to flatten the rim of subretinal fluid surrounding macular holes. Preliminary anatomic results of a multicenter prospective randomized study. *Retina* 1993;13:296–301. [\[CrossRef\]](#)
- Wendel RT, Patel AC, Kelly NE, Salzano TC, Wells JW, Novack GD. Vitreous surgery for macular holes. *Ophthalmology* 1993;100:1671–6. [\[CrossRef\]](#)
- Ryan EH Jr., Gilbert HD. Results of surgical treatment of recent-onset full-thickness idiopathic macular holes. *Arch Ophthalmol* 1994;112:1545–53. [\[CrossRef\]](#)
- Freeman WR, Azen SP, Kim JW, el-Haig W, Mishell DR 3rd, Bailey I. Vitrectomy for the treatment of fullthickness stage 3 or 4 macular holes. Results of a multicentered randomized clinical trial. Vitrectomy for treatment of macular hole study group. *Arch Ophthalmol* 1997;115:11–21. [\[CrossRef\]](#)
- DeBustos S. Vitrectomy for prevention of macular holes. Results of a randomized multicenter clinical trial. Vitrectomy for prevention of macular hole study group. *Ophthalmology* 1994;101:1055–9.
- Haritoglou C, Gass CA, Schaumberger M, Ehrt O, Gandorfer A, Kampik A. Macular changes after peeling of internal limiting membrane in macular hole surgery. *Am J Ophthalmol* 2001;132:363–8. [\[CrossRef\]](#)
- Brooks HL Jr. Macular hole surgery with and without internal limiting membrane peeling. *Ophthalmology* 2000;107:1939–49. [\[CrossRef\]](#)
- Haritoglou C, Gass CA, Schaumberger M, Gandorfer A, Ulbig MW, Kampik A. Long-term follow-up after macular hole surgery with internal limiting membrane peeling. *Am J Ophthalmol* 2001;134:661–6. [\[CrossRef\]](#)
- Rodrigues EB, Meyer CH. Meta-analysis of chromovitrectomy with indocyanine green in macular hole surgery. *Ophthalmologica* 2008;222:123–9. [\[CrossRef\]](#)
- Tognetto D, Grandin R, Sanguinetti G, Minutola D, Di Nicola M, Di Mascio R, et al. Internal limiting membrane removal during macular hole surgery: Results of a multicenter retrospective study. *Ophthalmology* 2006;113:1401–10. [\[CrossRef\]](#)
- Ullrich S, Haritoglou C, Gass C, Schaumberger M, Ulbig MW, Kampik A. Macular hole size as a prognostic factor in macular hole surgery. *Br J Ophthalmol* 2002;86:390–3. [\[CrossRef\]](#)
- Chang E, Garg P, Capone A Jr. Outcomes and predictive factors in bilateral macular holes. *Ophthalmology* 2013;120:1814–9.
- Gupta B, Laidlaw DA, Williamson TH, Shah SP, Wong R, Wren S. Predicting visual success in macular hole surgery. *Br J Ophthalmol* 2009;93:1488–91. [\[CrossRef\]](#)
- Kim JW, Freeman WR, Azen SP, el-Haig W, Klein DJ, Bailey IL. Prospective randomized trial of vitrectomy or observation for stage 2 macular holes. Vitrectomy for macular hole study group. *Am J Ophthalmol* 1996;121:605–14. [\[CrossRef\]](#)
- Roth DB, Smiddy WE, Feuer W. Vitreous surgery for chronic macular holes. *Ophthalmology* 1997;104:2047–52. [\[CrossRef\]](#)
- Mester U, Becker M. Prognostic factors in surgery of macular holes. *Ophthalmologie* 1998;95:158–62. [\[CrossRef\]](#)

17. Kumagai K, Ogino N, Demizu S, Atsumi K, Kurihara H, Iwaki M, et al. Factors related to initial success in macular hole surgery. [Article in Japanese]. *Nippon Ganka Gakkai Zasshi*. 2000;104:792–6.
18. Gander IC, Senn P, Luthi M, Schipper I. Prognostic factors and results after surgical treatment of idiopathic macular holes, stage 2 and 3. *Klin Monbl Augenheilkd* 2000;216:272–7.
19. Ip MS, Baker BJ, Duker JS, Reichel E, Baumal CR, Gangnon R, et al. Anatomical outcomes of surgery for idiopathic macular hole as determined by optical coherence tomography. *Arch Ophthalmol* 2002;120:29–35. [\[CrossRef\]](#)
20. Kang S, Ahn K, Ham D. Types of macular hole closure and their clinical implications. *Br J Ophthalmol* 2003;87:1015–9. [\[CrossRef\]](#)
21. Massin P, Vicaut E, Haouchine B, Erginay A, Paques M, Gaudric A. Reproducibility of retinal mapping using optical coherence tomography. *Arch Ophthalmol* 2001;119:1135–42. [\[CrossRef\]](#)
22. Simura M, Yasuda K, Nakazawa T, Kano T, Ohta S, Tamai M. Quantifying alteration of macular thickness before and after panretinal photocoagulation in patients with severe diabetic retinopathy and good vision. *Ophthalmology* 2003;110:2386–94. [\[CrossRef\]](#)
23. Kusuhara S, Escaño MF, Fujii S, Nakanishi Y, Tamura Y, Nagai A, et al. Prediction of postoperative visual outcome based on hole configuration by optical coherence tomography in eyes with idiopathic macular holes. *Am J Ophthalmol* 2004;138:709–16.
24. Nukada K, Hangai M, Ooto S, Yoshikawa M, Yoshimura N. Tomographic features of macula after successful macular hole surgery. *Invest Ophthalmol Vis Sci* 2013;54:2417–28. [\[CrossRef\]](#)
25. Chen H, Chen W, Zheng K, Peng K, Xia H, Zhu L. Prediction of spontaneous closure of traumatic macular hole with spectral domain optical coherence tomography. *Sci Rep* 2015;5:12343.
26. Matsumiya W, Kusuhara S, Shimoyama T, Honda S, Tsukahara Y, Negi A. Predictive value of preoperative optical coherence tomography for visual outcome following macular hole surgery: Effects of imaging alignment. *Jpn J Ophthalmol* 2013;57:308–15. [\[CrossRef\]](#)
27. Kusuhara S, Michael F, Escano T, Fujii S, Nakanishi Y, Tamura Y, Nagai A, et al. Prediction of postoperative visual outcome based on hole configuration by optical coherence tomography in eyes with idiopathic macular holes. *Am J Ophthalmol* 2004;138:709–16. [\[CrossRef\]](#)
28. Suda K, Hangai M, Yoshimura N. Axial length and outcomes of macular hole surgery assessed by spectral-domain optical coherence tomography. *Am J Ophthalmol* 2011;151:118–27.
29. Puliafito R, Hee MR, Lin CP, Reichel E, Schuman JS, Duker JS, et al. Imaging of macular diseases with optical coherence tomography (OCT). *Ophthalmology* 1995;102:217–29. [\[CrossRef\]](#)
30. Shpak AA, Shkvorchenko DO, Sharafetdinov I, Yukhanova OA. Predicting anatomical results of surgical treatment of idiopathic macular hole. *Int J Ophthalmol* 2016;9:253–7.