












A MEN-2A Case Developing Transient Adrenal Insufficiency after Unilateral Pheochromocytoma Surgery

 Mahsum Ozan,¹  İhsan Solmaz,¹  Jehat Kılıç,¹  Nurettin Ay,³  Salim İlksen Başçeken,³
 Süleyman Özçaylak,¹  Firdevs Acer,¹  Başak Bolayır,²  Hikmet Soylu,²  Sedat Çetin,²
 Halit Diri²

¹Department of Internal Diseases, Diyarbakır Gazi Yaşargil Training and Research Hospital, Diyarbakır, Türkiye

²Department of Endocrinology, Diyarbakır Gazi Yaşargil Training and Research Hospital, Diyarbakır, Türkiye

³Department of General Surgery, Diyarbakır Gazi Yaşargil Training and Research Hospital, Diyarbakır, Türkiye



Cite this article as:

Ozan M, Solmaz İ, Kılıç J, Ay N, Başçeken Sİ, Özçaylak S, et al. A MEN-2A Case Developing Transient Adrenal Insufficiency after Unilateral Pheochromocytoma Surgery. J Clin Pract Res; 45(5): 517–20.

Address for correspondence:

Halit Diri,
Diyarbakır Gazi Yaşargil
Training and Research Hospital,
Department of Endocrinology,
Diyarbakır, Türkiye
Phone: +90 412 258 00 71
E-mail: halitdiri@yahoo.com

Submitted: 20.12.2022

Revised: 23.02.2023

Accepted: 24.03.2023

Available Online: 09.06.2023

©Copyright 2023 by Erciyes
University Faculty of Medicine -
Available online at www.jcpres.com



This work is licensed under
a Creative Commons
Attribution-NonCommercial
4.0 International License.

ABSTRACT

Background: This case report provides detailed experiences of a patient with Multiple Endocrine Neoplasia type 2A (MEN-2A) who underwent surgery for pheochromocytoma and medullary thyroid cancer (MTC).

Case Report: A 58-year-old male patient with resistant hypertension, despite triple anti-hypertensive drug therapy, was diagnosed with pheochromocytoma after investigation into the underlying etiology. Although the adrenalectomy performed was unilateral rather than bilateral, and there were no signs of Cushing's syndrome or adrenal insufficiency before the operation, temporary adrenal insufficiency developed after the excision of the large adrenal mass. Additionally, the biochemical diagnosis of MTC was primarily established using a calcium stimulation test (CST) rather than basal calcitonin levels.

Conclusion: In cases where unilateral adrenalectomy is performed for a large adrenal mass, postoperative hypotension resistant to conservative therapy should raise suspicion of adrenal insufficiency. Furthermore, when basal calcitonin levels fall within the gray zone, a CST may be necessary for the diagnosis of MTC.

Keywords: Adrenal insufficiency, cancer, medullary thyroid cancer, MEN-2A, pheochromocytoma.

INTRODUCTION

An uncommon familial cancer syndrome, known as multiple endocrine neoplasia type-2A (MEN-2A), primarily affects the thyroid, adrenal, and parathyroid glands. MEN-2A is a rare neoplasia syndrome with an estimated prevalence of approximately 1:30,000.¹ Patients with MEN-2A typically exhibit medullary thyroid cancer (MTC) (>90%), pheochromocytoma (50%), and primary hyperparathyroidism (20%–30%), with the presence of two of these three features being sufficient for diagnosis.²

MEN syndromes are associated with the Rearranged during Transfection (RET) protooncogene, which encodes a transmembrane tyrosine kinase.^{1,3} Therefore, it is important to evaluate MTC and primary hyperparathyroidism in every patient with pheochromocytoma, and investigate pheochromocytoma in every patient with MTC due to their genetic linkages. If both MTC and pheochromocytoma are present, the adrenal gland should be operated first, followed by the thyroid gland. In this case report, we aim to share our experiences with an index MEN-2A case. Written informed consent was obtained from the patient for this report.

CASE REPORT

A 58-year-old male patient presented to the emergency department complaining of nausea, vomiting, and diarrhea. Upon discovering elevated serum urea and creatinine levels, he was diagnosed with prerenal acute kidney injury and admitted to the internal medicine clinic for further testing and treatment. During a systemic examination, severe dryness was observed in the oral mucosa and tongue, reduced skin turgor, and multiple nodules were detected in the thyroid gland. The patient had a one-year history of diabetes mellitus (DM), hypertension (HT) and coronary artery disease (CAD). Despite receiving the highest dosages of triple anti-hypertensive medication therapy, his blood pressure remained elevated at 200/110 mmHg. Additionally, his blood sugar levels remained high despite a daily dosage of 70 units of basal-bolus insulin.

Metanephrine and normetanephrine levels in 24-hour urine sample were found to be significantly elevated, consistent with a diagnosis of pheochromocytoma (metanephrine: 10315 mcg/24 hours, normal range: 50–250 mcg/24-h; normetanephrine: 9486 mcg/24-h, normal range: 100–500 mcg/24-h). Basal cortisol and adrenocorticotropic hormone (ACTH) levels were measured at 17.3 µg/dL and 38.9 pg/mL, respectively. Following a 1 mg dexamethasone suppression test, cortisol level decreased to 1.61 µg/dL. Abdominal ultrasound (USG) revealed a well-circumscribed, hypoechoic, heterogeneous adrenal mass with cystic areas, measuring approximately 91x104x112 mm in size.

Thyroid function tests indicated subclinical hyperthyroidism, and thyroid USG revealed several abnormal thyroid nodules, with the largest measuring 22x39x36 mm in size, along with cervical lymphadenopathies. As pheochromocytoma was identified, further investigation into MTC was conducted. Plasma calcitonin levels were found to be somewhat elevated (34 pg/mL, normal range: <8.4 pg/mL). Thyroid fine needle aspiration biopsy (TFNAB) was postponed until after the pheochromocytoma operation. Primary hyperparathyroidism was ruled out as serum parathormone and calcium levels were within normal limits (45.7 pg/mL and 9.6 mg/dL, respectively).

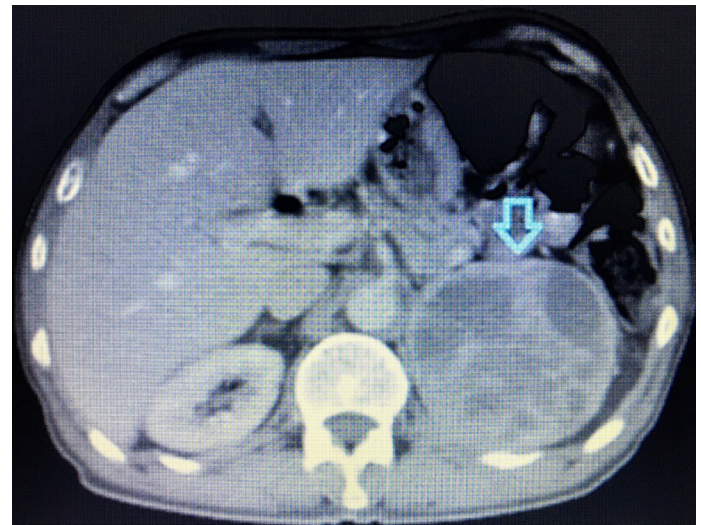


Figure 1. Left adrenal mass image on positron emission tomography (indicated arrow).

In ⁶⁸Ga-DOTATATE positron emission tomography performed to rule out metastasis of pheochromocytoma, a 93x90 mm adrenal mass lesion compatible with pheochromocytoma was observed in the left adrenal gland location, but no metastasis or surrounding tissue invasion was detected (Fig. 1). Preoperative hypertension was initially controlled with doxazosin tablets, and additional medications such as metoprolol and amlodipine were added. Intravenous hydration with 3L/day of isotonic NaCl was initiated three days prior to the operation. Infusion therapy with phentolamine was administered intraoperatively to regulate blood pressure. The patient underwent successful complete adrenalectomy on the left side, and the diagnosis was confirmed by the pathology report.

Despite receiving 3 L/day of isotonic NaCl support, the patient developed hypotension, fatigue, and nausea in the early postoperative phase, suggestive of adrenal insufficiency. Furthermore, although insulin therapy was discontinued, the patient's glucose values remained within normal range, and early morning blood cortisol levels were measured at 4.75 and 3.81 µg/dL, indicating adrenal insufficiency. Consequently, the patient received intravenous methylprednisolone at a dose of 40 mg/day for three days, which alleviated the symptoms of hypotension, fatigue, and nausea. Subsequently, the methylprednisolone medication was gradually tapered and completely discontinued three weeks later. Forty-eight hours after stopping methylprednisolone therapy, the basal cortisol and ACTH levels were measured at 17.1 µg/dL and 25.08 pg/mL, respectively, confirming the resolution of adrenal insufficiency.

Following the pheochromocytoma removal, TFNAB was performed, revealing a follicular neoplasm. The calcitonin level was found to be somewhat elevated (34 pg/mL), prompting

a calcium stimulation test (CST) which showed a peak calcitonin level of 546 pg/mL. Consequently, the case was classified as MTC stage-4A due to pathological neck lymphadenopathies, and thyroid surgery was performed two months after the pheochromocytoma operation. Pathological examination confirmed the presence of metastatic MTC.

Thus, MEN-2A syndrome was suspected, and genetic testing for RET mutation was ordered. Unfortunately, RET mutation was not detected in the patient's genetic test. Since all types of RET mutations were not studied at our hospital, family screening and genetic counseling were recommended.

DISCUSSION

While MTC is typically the main component of MEN-2A disease, pheochromocytoma may be identified in 13–27% of patients.⁴ Since pheochromocytoma can be the initial manifestation of MEN-2A, it is crucial to conduct further examinations to identify other components of the syndrome.⁵ In our case, pheochromocytoma was detected first, followed by the diagnosis of MTC, leading to the clinical diagnosis of MEN-2A. Although RET mutation was not identified in the genetic study, it is important to note that 2.4% of MEN patients may have RET mutations that differ from the previously known mutations.⁶

A direct diagnosis of MTC can be made when basal plasma calcitonin levels exceed 100 pg/mL.⁵ However, a CST is necessary when calcitonin levels range from 20 to 100 pg/mL.⁷ In our case, the basal calcitonin level (34 pg/mL) was insufficient for a direct diagnosis, and the TFNAB did not support the diagnosis of MTC. However, the CST revealed a significant peak calcitonin level (546 pg/mL) consistent with MTC.

Although the adrenalectomy performed was unilateral rather than bilateral, and there were no signs of Cushing's syndrome or adrenal insufficiency before the operation, temporary adrenal insufficiency developed after the removal of the large adrenal mass. It is hypothesized that the intact adrenal gland on the opposite side might have had relatively reduced activity compared to the side with the large mass, resulting in higher cortisol secretion. Constantinescu et al.⁸ reported that patients with pheochromocytoma had higher plasma cortisol levels than patients with primary hypertension, and adrenalectomy led to significant decreases in cortisol levels.

In the presented case, the rapid decrease in extremely high plasma catecholamine levels following surgery, along with the development of adrenal insufficiency due to the removal of the massive adrenal mass, likely contributed to the postoperative hypotension. In such cases, persistent hypotension despite conservative therapy should raise suspicion of adrenal insufficiency.⁹ Kahramangil et al.¹⁰ observed adrenal insufficiency in

37% of their 223 patients who underwent unilateral adrenalectomy for non-cortisol-secreting tumors. However, only 3.6% of those patients required steroid treatment for hypocortisolemia.

CONCLUSION

In conclusion, further research is needed to understand the issue of adrenal insufficiency that arises following the removal of massive adrenal masses. Additionally, it is important to evaluate the presence of MTC and primary hyperparathyroidism in patients with pheochromocytoma. For patients with pheochromocytoma and basal calcitonin level ranging from 20 to 100 pg/mL, a CST is necessary for the diagnosis of MTC.

Peer-review: Externally peer-reviewed.

Informed Consent: Written informed consent was obtained from the patient who participated in this study.

Author Contributions: Concept – MO; Design – İS, JK; Supervision – NA; Resource – FA; Materials – SÖ; Data Collection and/or Processing – SiB, BB; Analysis and/or Interpretation – HS; Literature Search – SÇ; Writing – HD, NA; Critical Reviews – BB.

Conflict of Interest: The authors have no conflict of interest to declare.

Financial Disclosure: The authors declared that this study has received no financial support.

REFERENCES

1. Marini F, Falchetti A, Del Monte F, Carbonell Sala S, Tognarini I, Luzi E, et al. Multiple endocrine neoplasia type 2. *Orphanet J Rare Dis* 2006; 1: 45. [\[CrossRef\]](#)
2. Eng C. Multiple endocrine neoplasia Type 2. In: Adam MP, Mirzaa GM, Pagon RA, editors. *Molecular Genetics of Cancer*. University of Washington, Seattle; 2001.p.218.
3. Siqueira DR, Ceolin L, Ferreira CV, Romitti M, Maia SC, Maciel LM, et al. Role of RET genetic variants in MEN2-associated pheochromocytoma. *Eur J Endocrinol* 2014; 170(6): 821–8.
4. Rodriguez JM, Balsalobre M, Ponce JL, Ríos A, Torregrosa NM, Tebar J, et al. Pheochromocytoma in MEN 2A syndrome. Study of 54 patients. *World J Surg* 2008; 32(11): 2520–6. [\[CrossRef\]](#)
5. Wells SA Jr, Asa SL, Dralle H, Elisei R, Evans DB, Gagel RF, et al; American Thyroid Association Guidelines Task Force on Medullary Thyroid Carcinoma. Revised American Thyroid Association guidelines for the management of medullary thyroid carcinoma. *Thyroid* 2015; 25(6): 567–610. [\[CrossRef\]](#)
6. Romei C, Mariotti S, Fugazzola L, Taccaliti A, Pacini F, Opocher G, et al; ItaMEN network. Multiple endocrine neoplasia type 2 syndromes (MEN 2): results from the ItaMEN network analysis on the prevalence of different genotypes and phenotypes. *Eur J Endocrinol* 2010; 163(2): 301–8.

7. Karges W. Calcitonin determination for early diagnosis of medullary thyroid cancer. [Article in German]. *Chirurg* 2010; 81(7): 620–6. [\[CrossRef\]](#)
8. Constantinescu G, Langton K, Conrad C, Amar L, Assié G, Gimenez-Roqueplo AP, et al. Glucocorticoid Excess in Patients with Pheochromocytoma Compared with Paraganglioma and Other Forms of Hypertension. *J Clin Endocrinol Metab* 2020; 105(9): e3374–83. [\[CrossRef\]](#)
9. Juszczak K, Drewa T. Adrenergic crisis due to pheochromocytoma - practical aspects. A short review. *Cent European J Urol* 2014; 67(2): 153–5. [\[CrossRef\]](#)
10. Kahramangil B, Montorfano L, Gutierrez D, Erten O, Zhou K, Li D, et al. Biochemical assessment of adrenal insufficiency after adrenalectomy for non-cortisol secreting tumors: clinical correlation and recommendations. *Surg Endosc* 2022; 36(10): 7638–46. [\[CrossRef\]](#)