

## Effect of Omeprazole on Fracture Healing in the Random-Patterned Rat Tibial Fracture Model: An Experimental Study

Mustafa Kinas,<sup>1</sup> Ökkeş Bilal,<sup>2</sup> Aybars Kıvrak<sup>3</sup>

<sup>1</sup>Department of Orthopedics and Traumatology, Royal Hospital, Balıkesir, Türkiye

<sup>2</sup>Department of Orthopedics and Traumatology, Kahramanmaraş Sütçü İmam University, Kahramanmaraş, Türkiye

<sup>3</sup>Department of Orthopedics and Traumatology, Avrupa Hospital, Adana, Türkiye

### ABSTRACT

**Objective:** Fractures represent one of the most common pathologies encountered in orthopedic practice. Various factors can impact fracture healing, both negatively and positively. This study aimed to investigate the influence of omeprazole, a proton pump inhibitor prescribed to mitigate the side effects of non-steroidal anti-inflammatory drugs (NSAIDs) used for pain management post-fracture treatment and for deep vein thrombosis (DVT) prophylaxis, on fracture union through an animal experiment.

**Materials and Methods:** The study utilized 40 male Wistar-Albino rats obtained from the Experimental Research Laboratory. Employing the simple randomization method, the animals were divided into experimental and control groups, with tibia fractures induced and subsequently fixed intramedullarily. At the conclusion of the sixth week, comprehensive histological, radiological, and biomechanical assessments were conducted to compare fracture union and bone biomechanical strength with the control group.

**Results:** Histological and radiological evaluations were conducted on the tibias of 40 male Wistar-Albino rats. In terms of biomechanical analysis, 14 tibias from the control group and 16 tibias from the study group were examined. Remarkably, the study group exhibited superior union compared to the control group both histologically ( $p=0.033$ ), radiologically (AP1 view;  $p=0.040$ , AP2 view;  $p=0.036$ , LAT1 view;  $p=0.081$ , LAT2 view;  $p=0.03$ ), and biomechanically ( $p=0.047$ ), following omeprazole use.

**Conclusion:** The administration of omeprazole as a proton pump inhibitor following fracture treatment contributes positively to the process of fracture healing.

**Keywords:** Omeprazole, fracture healing, proton pump inhibitor.



#### Cite this article as:

Kinas M, Bilal Ö, Kıvrak A.  
Effect of Omeprazole on  
Fracture Healing in the Random-  
Patterned Rat Tibial Fracture  
Model: An Experimental Study.  
J Clin Pract Res 2023; 45(5):  
447–55.

#### Address for correspondence:

Aybars Kıvrak.  
Department of Orthopedics and  
Traumatology, Avrupa Hospital,  
Adana, Türkiye  
**Phone:** +90 322 206 00 00  
**E-mail:** aybarskivrak@gmail.com

**Submitted:** 23.03.2023

**Revised:** 24.04.2023

**Accepted:** 08.08.2023

**Available Online:** 29.08.2023

Erciyes University Faculty of  
Medicine Publications -  
Available online at [www.jcpr.com](http://www.jcpr.com)

### INTRODUCTION

Fracture healing stands as one of the most extensively studied subjects within the realm of orthopedics worldwide. The seamless and swift healing of fractures remains the paramount objective for orthopedists and trauma surgeons engaged in fracture treatment.<sup>1</sup> The escalating incidence



This work is licensed under  
a Creative Commons  
Attribution-NonCommercial  
4.0 International License.

of high-energy accidents in our progressing society, coupled with the advent of innovative implants boasting distinct properties and novel drugs with their attendant effects, had notably focused the attention of researchers on this domain.

Omeprazole, a benzimidazole derivative and benzimidazole sulfoxide prodrug, exerts robust inhibition on gastric acid secretion.<sup>2</sup> It effectively suppresses both basal and stimulated acid secretion in a dose-dependent manner, achieving nearly complete inhibition. The interaction between hydrogen ion feedback and gastrin secretion leads to the removal of inhibition, consequently increasing gastrin secretion from the stomach into the bloodstream, which subsequently elevates plasma gastrin levels. The suppression of gastric acidity commences within the first hour following a single dose of omeprazole, peaking within two hours. Roughly half of the maximum effect persists after 24 hours, and some degree of suppression may endure for up to three days. Partial recovery of acid secretion occurs within three to five days after discontinuation of the drug, although full recovery might necessitate weeks.<sup>3</sup>

In studies conducted to examine the effects of increased serum gastrin levels in the body, the relationship between serum gastrin levels and serum Heparin-Binding Epidermal Growth Factor (HB-EGF) levels has been investigated. It has been demonstrated that gastrin contributes to increased angiogenesis by elevating HB-EGF levels. Notably, HB-EGF is recognized to promote neovascularization *in vivo*.<sup>4</sup> Moreover, a direct correlation between enhanced vascularity in ischemic and necrotic regions surrounding a tumoral structure and HB-EGF, indirectly linked to gastrin, has been established.<sup>5</sup> The potential positive impact of omeprazole on fracture healing was hypothesized due to its indirect influence on angiogenesis by inducing hypergastrinemia. The decision to undertake this study stemmed from the absence of research regarding the favorable effects of proton pump inhibitors (PPIs) on fracture healing in existing literature. To this end, the study aimed to investigate the impact of parenteral administration of omeprazole on fracture healing using an experimentally induced tibia fracture model in rats.

## MATERIALS AND METHODS

### Experiment and Subjects

The study was conducted with the necessary permissions obtained from the local ethics committee prior to initiation (Kahramanmaraş Sütçü İmam University Faculty of Medicine Animal Experiments Local Ethics Committee, dated 01.12.2015, 2015/06 session, decision no 12). Our investigation took place within the experimental research laboratory from August to September 2016. For this study, 40 male Wistar-Albino rats

were utilized, procured from the Experimental Research Laboratory. The average age of the rats involved was four months, with a mean weight of 421 grams (ranging between 366–476 grams). The animals were divided into experimental and control groups through the utilization of the simple randomization method, facilitated by the [www.random.org](http://www.random.org) website. They were housed in eight separate cages of appropriate sizes, accommodating five rats in each cage. Labels indicating the presence of experimental and control groups were affixed to the respective cages. These rats were housed within the rat shelter located in the physiology laboratory, maintained under uniform laboratory conditions featuring an average constant temperature of 22 degrees Celsius, with a 12-hour light-dark cycle. Throughout the study, the rats were provided with a consistent diet of pellet rat chow and ad libitum access to tap water (as much as they desired). All surgical procedures were performed under general anesthesia. No animals within any of the groups perished during the course of the experimental period. At the conclusion of the sixth week, rats belonging to both the drug-administered and control groups were euthanized using high-dose ketamine.

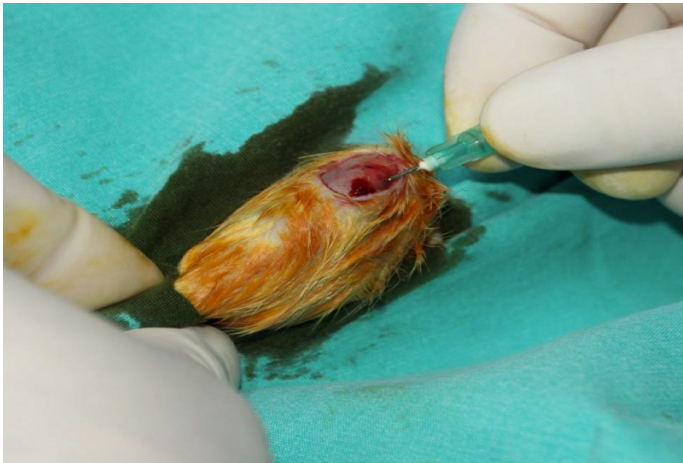### Fracture Model Creation

#### Anesthesia

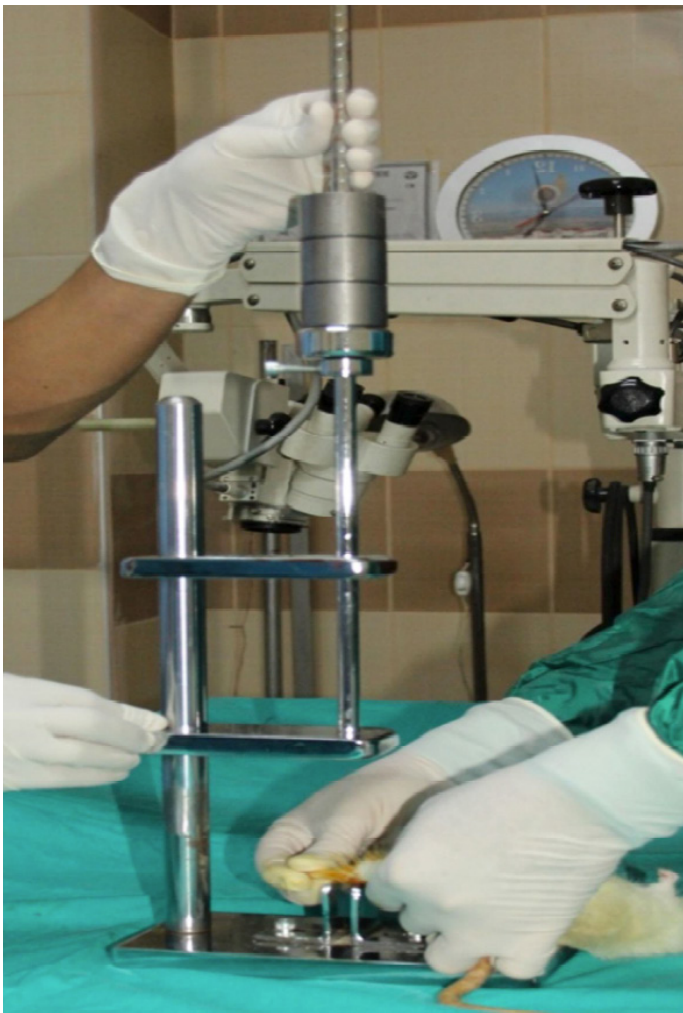To prevent respiratory tract obstruction, the rats utilized in the study received 0.18mg/kg Atropine sulfate (atropine amp., Biosel™, Istanbul) intramuscularly (IM) as well as anesthetic premedication. Prior to the procedure, an intraperitoneal administration of 50 mg/kg cefazolin sodium (Cefazol vial, Mustafa Nevzat™, Istanbul) was conducted for prophylactic antibiotherapy. For the operative anesthesia, an intraperitoneal injection of 50 mg/kg Ketamine hydrochloride (Ketalar vial, Parke 26 Davis™, Istanbul) was administered. The anesthesia state was monitored based on the response elicited by squeezing the rat's skin every five minutes. Subsequently, morphine HCL (Morphine HCL ampoule, Biosel™, Istanbul) was subcutaneously administered at a dosage of 10 mg/kg for post-procedure analgesia.

#### Fracture Model Creation and Fixation Method

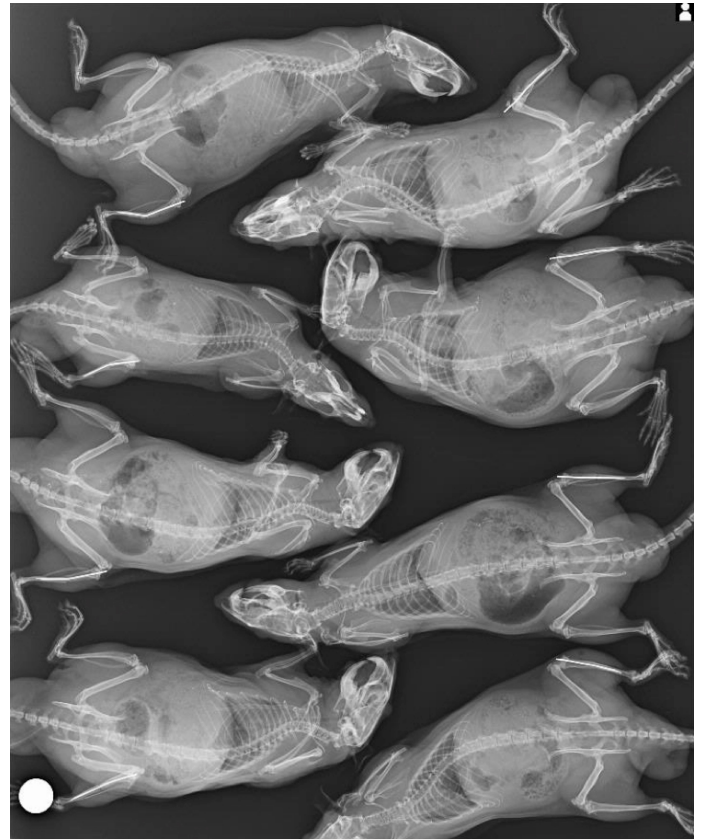
After the appropriate anesthesia was induced, the local area was cleaned with a Betadine scrub (10% povidone-iodine) solution, establishing a sterile field on the rats. A longitudinal incision of 0.5 cm was made anteromedially from the anterior surface of the tibial plateau. Using a 0.7 mm needle (21 gauge), the needle was introduced into the tibia through this incision point (Fig. 1). The needle tip was excised beneath the skin using a side cutter. The incision was irrigated with sterile 10 cc saline, and the skin was sutured with silk 3/0 sutures. Subsequently, the wound was treated with povidone iodide. To cre-



**Figure 1.** Tibia fixation using a 0.7 mm needle.



**Figure 2.** Fracture following the three-point principle after intramedullary fixation of the tibia.



**Figure 3.** X-ray verification after tibia fracture.


ate a consistent fracture with an identical force (12.26N) from the same location on the tibia shaft, following the anesthesia, a specially designed mechanism was employed. This mechanism adhered to the 3-point principle in bone and generated a tibial shaft fracture (Fig. 2). Post-surgery, control radiographs were obtained for assessment. Immediately after the procedure, the fracture sustained by each subject was radiologically verified through direct radiographs. Radiographs confirmed a fractured right tibia with intramedullary fixation in all rats (Fig. 3).

#### **Drug Administration**

The same standardized procedures were applied to all rats in the experimental group. Intraperitoneal injections of 10 mg/kg omeprazole commenced for the study group rats four days prior to the operation, following daily local area cleansing with betadine solution. omeprazole administration persisted until the time of sacrifice at the end of the sixth week. In the control group, beginning one day post-operation, intraperitoneal saline solution (SF) was administered daily following local site cleansing with betadine solution. For the study group rats, intraperitoneal injections of 10 mg/kg omeprazole continued on a daily basis after local site cleansing with betadine solution.

**Table 1.** Lane-Sandhu Classification

0	No callus
1	Minimal callus
2	Callus evident but healing incomplete
3	Callus evident with stability expected
4	Complete healing with bone remodeling

**Figure 4.** Induction of a rat tibia fracture.

## EVALUATION OF RESULTS

### Radiological Evaluation

For the radiological assessment, after sacrificing the rats at the end of the sixth week and removing the intramedullary wires, the tibias were isolated and the surrounding soft tissues were meticulously cleaned. Subsequently, the tibias were fixed using formalin before being transported to the radiology department. Direct radiographs were captured using a conventional radiography device. For the X-ray imaging, 20 rat legs were positioned for anteroposterior radiographs based on their respective groups. One large X-ray cassette was utilized per group. Evaluation of the radiographs was performed by two radiologists who were unaware of each other's evaluations and remained blinded to the group assignments. The results were evaluated in accordance with the Lane-Sandhu classification (Table 1).<sup>6</sup> Notably, in the control group, it was observed that the intramedullary wire remained within one rat. This wire was subsequently removed prior to conducting the biomechanical test.

### Biomechanical Evaluation

During the biomechanical evaluation in our study, the forces applied to break the tibias of the rats were measured using a Zwick/Roell Mechanical Tester (Fig. 4). To ensure accurate outcomes, particular attention was given to breaking the tibias of all rats from the same point during the fracture procedure. For this purpose, we utilized specially designed clamps of our own creation.

For the biomechanical evaluation, after the rats were sacrificed at the 6-week mark and radiographs were taken, an experiment was conducted with the aid of our own designed special clamps. This experiment aimed to apply a three-point bending test to the tibia. By exerting force on the callus region, we measured and compared the resistance forces of each group's elements against bending in Newtons.

### Histopathological Evaluation

For histopathological assessment, samples were obtained from the fracture site of the rats' bone tissues. The collected bone tissue samples were fixed in 10% neutral formaldehyde and preserved in 5% formic acid. Following routine histopathological preparations, the materials embedded in paraffin blocks were sectioned into 3.5-micron slices using a Leica Rotary microtome. These sections were stained with Hematoxylin-Eosin and Masson Trichrome, then subjected to analysis. A pathologist evaluated tissue micrographs using a digital camera-mounted binocular research microscope. All preparations were assessed based on the proportions of fibrous tissue, cartilage, new bone, and mature bone, using the scale proposed by Oda et al.<sup>7</sup>

### Statistical Analysis

Statistical analyses were conducted using the Statistical Package for the Social Sciences (SPSS) software version 20. The variables were examined through visual methods (histograms, probability plots) and analytical techniques (Kolmogorov-Smirnov/Shapiro-Wilk's test) to determine their distribution. Descriptive analyses were presented using means and standard deviations for normally distributed variables. The Student's t-test and Chi-square test (or Fisher's exact test when assumptions of the Chi-square test were not met due to low expected cell counts) were employed, where applicable, for parameter comparisons. A p-value less than 0.05 was considered indicative of statistical significance.

## RESULTS

### Radiological Findings

The evaluation of the control group and study group by the first and second radiologists is presented in Table 2 and Table 3. No disparity was noted in the lateral radiograph assessment by the first radiologist, whereas a noteworthy distinction emerged in the other three independent evaluations ( $p < 0.05$ ).

### Biomechanical Findings

Following the sixth week since the commencement of the study, subsequent to the sacrifice of both the study and control groups, they underwent the three-point bending test (Fig. 4). While the study group saw the sacrifice of two rats, the execution of the three-point bending test was hindered due to the

**Table 2.** Distribution of study and control groups based on anteroposterior (AP) X-ray values - first radiologist and second radiologist

AP X-ray	Control group		Study group		Total		X <sup>2</sup>	p
	n	%	n	%	n	%		
Pseudoarthrosis formation	4 (4)	100 (100)	0 (0)	0 (0)	4 (4)	100 (100)	10.018 (10.286)	0.040 (0.036)
Incomplete cartilaginous union	4 (4)	100 (100)	0 (0)	0 (0)	4 (4)	100 (100)		
Complete cartilaginous union	2 (1)	40 (33.3)	3 (2)	60 (66.7)	5 (3)	100 (100)		
Incomplete bony union	4 (5)	36.4 (33.3)	7 (10)	63.6 (66.7)	11 (15)	100 (100)		
Complete bony union	6 (6)	37.5 (42.9)	10 (8)	62.5 (57.1)	16 (14)	100 (100)		
Total	20 (20)	50 (50)	20 (20)	50 (50)	40 (40)	100 (100)		

AP: Anteroposterior; N: Number.

**Table 3.** Distribution of study and control groups according to the lateral X-ray values - first radiologist and second radiologist

Lateral X-ray	Control group		Study group		Total		X <sup>2</sup>	p
	n	%	n	%	n	%		
Pseudoarthrosis formation	6 (4)	100 (100)	0 (0)	0 (0)	6 (4)	100 (100)	8.307 (10.751)	0.081 (0.030)
Incomplete cartilaginous union	2 (3)	66.7 (100)	1 (0)	33.3 (0)	3 (3)	100 (100)		
Complete cartilaginous union	1 (0)	25 (0)	3 (3)	75 (100)	4 (3)	100 (100)		
Incomplete bony union	3 (5)	37.5 (38.5)	5 (8)	62.5 (61.5)	8 (13)	100 (100)		
Complete bony union	8 (8)	42.1 (47.1)	11 (9)	57.9 (52.9)	19 (17)	100 (100)		
Total	20 (20)	50 (50)	20 (20)	50 (50)	40 (40)	100 (100)		

N: Number.

separation of the tibias of two rats during the biomechanical test. Similarly, within the control group, three rats were sacrificed, and the three-point bending test could not be conducted due to the separation of the tibias of three rats during the biomechanical test. The resistance of the callus tissues formed in all groups against bending was quantified and graphed. Table 4 illustrates the breaking forces in Newtons derived from all groups at the culmination of the biomechanical study.

**Histopathological Findings**

All preparations were evaluated based on the proportions of fibrous tissue, cartilage, new bone, and mature bone, utilizing the scale proposed by Oda et al.<sup>7</sup> Upon examination by the pathologist, the control group exhibited 4 cases of cartilage healing accompanied by fibrous tissue, 14 cases of incomplete bone healing, and 2 cases of complete bone healing. In contrast, the study group showed no instances of fibrous tissue and cartilage healing, with 13 cases of incomplete bone healing and 7 cases of complete bone healing reported. Upon statistical analysis, a significant discrepancy was observed (p<0.05).

**Table 4.** Bending strength (Newton)

Sample	Study group	Control group
1	57.8	97.7
2	91.4	55.8
3	102	45.7
4	65.6	43.7
5	33.3	53
6	67.6	47.7
7	108	80
8	81.9	35
9	69.5	51.8
10	67.3	55.8
11	56.1	37.5
12	63.6	36.6
13	35.3	52.4
14	47.4	48.4
15	58.1	
16	77	

## DISCUSSION

Drug utilization for post-fracture DVT prophylaxis is quite common, and NSAIDs are often employed for pain palliation. The utilization of these drugs, however, is associated with an elevated risk of gastric bleeding. Employing PPIs, such as omeprazole, in conjunction with these drugs can positively contribute to fracture healing.

Bone, being a metabolically active and dynamic tissue, offers skeletal support for organisms while continually renewing itself throughout life.<sup>8</sup> Fractures, stemming from traumatic, stress-related, and pathological origins, compromise the anatomical and functional integrity of bone and rank among the most frequent injuries in orthopedic and traumatology clinics. The process of fracture healing is intricate, encompassing not only the bone itself, but also the encasing periosteum, surrounding soft tissues, and cellular and biochemical processes with the marrow.<sup>9</sup> Unlike healing in other tissues, fracture healing showcases a unique ability to regenerate in a manner closely resembling the original structure, minimizing scar tissue formation.<sup>10</sup> Various factors have been identified that impact the process of fracture healing. Among these are the nature of trauma, the chosen approach to fracture treatment, the fixation method employed, and systemic issues.<sup>11</sup> The medications used also play the role in influencing bone fracture healing. Proton pump inhibitors, widely utilized in clinical practice, represent one such factor affecting fracture healing. In our study, following thorough histological, radiological, and biomechanical investigations, we found that the omeprazole molecule yielded positive outcomes in promoting fracture healing.

NSAIDs are commonly prescribed to alleviate pain and curb inflammation following conservative management of fractures and extremity surgeries. This is crucial for mitigating pain and quelling aseptic inflammatory reactions in tissues post-trauma.<sup>12</sup> The clinical investigation by Forrest et al.<sup>13</sup> highlighted that following major surgical procedures, NSAIDs administered for pain management led to acute gastric bleeding at a rate of 0.04%. A retrospective cohort study conducted by Dahl et al.<sup>14</sup> unveiled a 1.5% incidence of bleeding in the upper gastrointestinal tract within 30 days of NSAID usage. PPIs are administered to prevent gastrointestinal bleeding resulting from NSAID use for postoperative pain management in orthopedic surgery. Since the elevated risk of deep vein thrombosis (DVT) in patients immobilized for extended periods due to substantial bone fractures, prophylactic drugs are used to mitigate the occurrence of pulmonary embolism and, consequently, reduce mortality rates.<sup>15</sup> A study by Eriksson et al.<sup>16</sup> comparing recombinant hirudin and low molecular weight heparin to prevent thromboembolic complications after total hip replacement revealed a reported incidence of bleeding at 2%.

These medications act as agents that exacerbate bleeding, and proton pump inhibitors are frequently administered to safeguard patients from gastrointestinal bleeding. Upon reviewing the literature, it becomes evident that while the effects of proton pump inhibitors on various tissues have been explored, their impact on bone healing remains relatively limited. Existing studies have primarily focused on bone turnover within the context of hypergastrinemia.<sup>17</sup>

PPIs exhibit a range of side effects. One of the most notable among these is the assumption that they carry an increased risk of bone fracture.<sup>18</sup> Enhanced osteoclastic bone resorption is among the factors attributed to this risk. In a study by Histing et al.,<sup>18</sup> involving pantoprazole in an animal model, fracture healing was found to be adversely affected. Moreover, Karsdal et al.<sup>19</sup> highlighted that bafilomycin, a selective proton pump blocker, not only completely inhibits osteoclastic bone resorption but can even increase the count of osteoclasts. Another study demonstrated that PPIs can lead to a reduction in bone mineral density and exert a negative influence on biomechanical properties.<sup>20</sup> Unlike other PPIs within the same drug group, the application of omeprazole in our study yielded a positive effect on bone healing.

In experimental studies involving fracture healing in rats, the tibia and femur are commonly employed as bone models due to their suitability for fracture induction, ease of fixation, and straightforward preparation of histopathological specimens.<sup>12,21</sup>

Taking these factors into consideration, we selected the tibia as our model. Female mammals undergo metabolic instability due to cyclic hormonal fluctuations. Hence, for reasons of stability, adult male rats were chosen as subjects for this study. In our study, intramedullary fixation was initially implemented, followed by the creation of the fracture. When examining the methods of fracture formation, it becomes evident that various techniques have been employed in the literature. Among these, methods such as forming fractures using bending pliers and inducing fractures through the impact of a blunt guillotine's falling weight have been documented.<sup>12</sup> As for the fracture formation technique, a specially crafted blunt guillotine, which ensures consistent force and standardized fracture generation, was chosen based on our design.

In the process of creating the fracture model, open and closed methods for inducing fractures can be used. The closed fracture model has been extensively covered in numerous studies within the literature. Nevertheless, this technique is not employed in cases of open osteotomy fractures due to the associated risks of delayed union, heightened infection rates, and a predisposition to nonunion. Nonetheless, there are studies in the literature advocating for the open osteotomy technique, especially for comparative analysis of treatment methods.<sup>21</sup>

Examining the existing literature, it becomes apparent that a frequently adopted model involves the use of intramedullary nails before inducing fractures and osteotomy at a later stage.<sup>22</sup>

In our study, we employed a closed fracture technique with the assistance of a device designed in-house. This device operates on the principle of fixation followed by three-point bending, achieved by accessing the knee joint. This method was chosen for its ability to offer fixation through an injector and ease of application. Furthermore, it facilitates non-rigid fixation, promoting healing of secondary fractures and callus tissue.

In the literature, it was observed that fractures occurred when a weight of 220 grams was dropped from a distance of 195 mm, and a weight of 650 grams was dropped from a distance of 150 mm.<sup>23</sup> These disparities were believed to be influenced by rat size and device characteristics. In our trials, we noted fractures occurring with a weight of 1,250 grams dropped from a distance of 150 mm using the device we employed. We attributed the higher weights in our experiments to the larger size of the rats used and the occurrence of fractures while the intramedullary nail was in place.

Furthermore, no additional fixation or immobilization from the outside, such as casting, was implemented beyond intramedullary fixation after the fracture. While this fixation might initially seem disadvantageous due to its lack of rigidity, it eventually presented an advantage in our evaluation due to the enhanced development of callus tissue in a non-rigid fixation environment. Although consensus is lacking regarding the optimal timeframe for fracture healing studies, it has been commonly observed that sacrifice was most frequently performed at the sixth week.<sup>10</sup> Accordingly, our study was concluded at the end of the sixth week.

Upon reviewing the literature concerning radiological assessment of fracture healing, a diverse array of methods came to light. Some studies examined the bridging status between fracture ends using direct radiographs. Callus sizes were quantified through varying measurement techniques, often accompanied by scoring systems.<sup>24</sup>

However, it can be said that all these evaluations are not objective enough to assess fracture healing, and the evaluation differs from person to person. For this reason, two different radiologists, who were unaware of each other's evaluations, were engaged during the radiological assessment. We asked them to evaluate the fractures according to the Lane and Sandhu Scoring system, which is easier to apply and we anticipate there will be less variance between individuals.<sup>6</sup> The average scores from these radiologists were compiled. It was understood that these results could solely provide supplementary support for our histological and biomechanical evaluations.

In certain studies within the literature, the histological evaluation scale introduced by Huo et al.<sup>25</sup> was used. This scale involves scoring fibrous tissue, cartilage tissue, immature and mature bone ratios within the healing area formed on the proximal and distal sides of the fracture line as indicators of healing. In other studies, the assessment scale described by Vasconcelos et al.<sup>26</sup> was adopted. This scale employs a 0-4 scoring system to indicate the stage of the healing tissue. Given the ease and comprehensibility of this scoring approach, it was chosen for histological evaluation in our study.

In the literature, the impact of PPIs on osteoclasts and osteoblasts was investigated through histological examinations.<sup>27</sup> In the histopathological analysis conducted by Histing et al.,<sup>18</sup> it was noted that bone tissue was diminished in the pantoprazole group by the end of the fifth week. Another study indicated a significantly lower quantity of bone tissue in pantoprazole-treated animals at two and five weeks post-fracture healing.<sup>28</sup> In our study, unlike other compounds discussed in the literature, the histopathological evaluation revealed significantly enhanced bone healing in the group treated with omeprazole.

The effect of omeprazole on fracture healing can be elucidated through various mechanisms. Its impact on calcium metabolism can influence absorption in the gastrointestinal tract. Furthermore, an alternative mechanism could be linked to omeprazole's influence on granulocytes. Granulocytes accumulate in the callus tissue during the early stage of bone repair. These cells play a crucial role in fracture healing by releasing angiogenic factors.<sup>29</sup> Nevertheless, the effects of omeprazole mentioned in the literature remain a subject of controversy.<sup>30</sup>

There are certain limitations to our study. The study lacked various types of subjects, where different durations and doses were examined. This has led to deficiencies, including the inability to study scintigraphic and biochemical markers. Conducting experiments with a larger number of subjects, varied doses, and time-dependent analyses on different species is necessary. Furthermore, we believe that incorporating biochemical markers to demonstrate vascularity in conjunction with scintigraphic studies will result in more meaningful and robust research.

## CONCLUSION

In conclusion, when analyzing the data obtained from radiological, histopathological, and biomechanical tests in our study, we have concluded that omeprazole may have positive effects on fracture healing. It is important to note that both NSAID drugs and medications used for DVT prophylaxis can lead to gastrointestinal bleeding after a fracture. We believe that omeprazole could be a more suitable option if proton pump inhibitors are to be administered to patients.

**Peer-review:** Externally peer-reviewed.

**Ethics Committee Approval:** The Kahramanmaraş Sütçü İmam University Faculty of Medicine Animal Experiments Local Ethics Committee granted approval for this study (date: 01.12.2015, number: 12).

**Author Contributions:** Concept – MK, ÖB, AK; Design – MK, ÖB, AK; Supervision – ÖB; Resource – MK, ÖB, AK; Materials – MK; Data Collection and/or Processing – MK, ÖB; Analysis and/or Interpretation – MK, ÖB; Literature Search – MK, ÖB; Writing – MK, ÖB, AK; Critical Reviews – MK, ÖB, AK.

**Conflict of Interest:** The authors have no conflict of interest to declare.

**Financial Disclosure:** The authors declared that this study has received no financial support.

## REFERENCES

1. Arazi M. School of Basic Sciences and Research Fracture Repair: TOTEK; 2013.p.193–204.
2. Melzer E, Bruck R, Krepel Z, Bar-Meir S. Lack of effect of omeprazole on rat hepatic blood flow. *Isr J Med Sci* 1989; 25(12): 722–3.
3. Mistik S, Başaran AÖ, Yurci A, Gürsoy Ş, Ulusoy HB. Evaluation of the efficacy of five proton pump inhibitors in gastroesophageal reflux disease using symptom indices and quality of life questionnaires. *Eurasian J Fam Med* 2016; 5(1): 33–40.
4. Abramovitch R, Neeman M, Reich R, Stein I, Keshet E, Abraham J, et al. Intercellular communication between vascular smooth muscle and endothelial cells mediated by heparin-binding epidermal growth factor-like growth factor and vascular endothelial growth factor. *FEBS Lett* 1998; 425(3): 441–7. [CrossRef]
5. Shweiki D, Neeman M, Itin A, Keshet E. Induction of vascular endothelial growth factor expression by hypoxia and by glucose deficiency in multicell spheroids: implications for tumor angiogenesis. *Proc Natl Acad Sci U S A* 1995; 92(3): 768–72.
6. Pazarcı Ö, Gumus E, Taş A, Keklikcioğlu Çakmak N, Kılınç S, Yıldız ŞN, et al. An investigation of the effect of acrylamide on fracture healing in rats. *Ulus Travma Acil Cerrahi Derg* 2022; 28(5): 570–8. [CrossRef]
7. Oda T, Niikura T, Fukui T, Oe K, Kuroiwa Y, Kumabe Y, et al. Transcutaneous CO<sub>2</sub> application accelerates fracture repair in streptozotocin-induced type I diabetic rats. *BMJ Open Diabetes Res Care* 2020; 8(2): e001129. [CrossRef]
8. Buckwalter JA, Glimcher MJ, Cooper RR, Recker R. Bone biology. I: Structure, blood supply, cells, matrix, and mineralization. *Instr Course Lect* 1996; 45: 371–86.
9. Einhorn TA. The cell and molecular biology of fracture healing. *Clin Orthop Relat Res* 1998; 355(Suppl): S7–21.
10. Einhorn TA. Enhancement of fracture-healing. *J Bone Joint Surg Am* 1995; 77(6): 940–56. [CrossRef]
11. ElHawary H, Baradaran A, Abi-Rafeh J, Vorstenbosch J, Xu L, Efanov JI. Bone healing and inflammation: Principles of fracture and repair. *Semin Plast Surg* 2021; 35(3): 198–203.
12. Sevimli R, Uzel M, Sayar H, Kalender AM, Dökmeci O. The effect of dexketoprofen trometamol on the healing of diaphysis fractures of rat tibia. *Acta Orthop Traumatol Turc* 2013; 47(6): 423–9. [CrossRef]
13. Forrest JB, Camu F, Greer IA, Kehlet H, Abdalla M, Bonnet F, et al; POINT Investigators. Ketorolac, diclofenac, and ketoprofen are equally safe for pain relief after major surgery. *Br J Anaesth*. 2002; 88(2) :227–33. [CrossRef]
14. Dahl JB, Kehlet H. Non-steroidal anti-inflammatory drugs: Rationale for use in severe postoperative pain. *Br J Anaesth* 1991; 66(6): 703–12. [CrossRef]
15. Wang T, Guo J, Long Y, Yin Y, Hou Z. Risk factors for preoperative deep venous thrombosis in hip fracture patients: A meta-analysis. *J Orthop Traumatol* 2022; 23(1): 19. [CrossRef]
16. Eriksson BI, Wille-Jørgensen P, Kålebo P, Mouret P, Rosencher N, Bösch P, et al. A comparison of recombinant hirudin with a low-molecular-weight heparin to prevent thromboembolic complications after total hip replacement. *N Engl J Med* 1997; 337(19): 1329–35. [CrossRef]
17. Şen H, Oruç M, Işık VM, Sadiç M, Sayar H, Çitil R, et al. The effect of omeprazole usage on the viability of random pattern skin flaps in rats. *Ann Plast Surg* 2017; 78(6): e5–9.
18. Histing T, Stenger D, Scheuer C, Metzger W, Garcia P, Holstein JH, et al. Pantoprazole, a proton pump inhibitor, delays fracture healing in mice. *Calcif Tissue Int* 2012; 90(6): 507–14.
19. Karsdal MA, Henriksen K, Sørensen MG, Gram J, Schaller S, Dzięgiel MH, et al. Acidification of the osteoclastic resorption compartment provides insight into the coupling of bone formation to bone resorption. *Am J Pathol* 2005; 166(2): 467–76. [CrossRef]
20. Mester A, Apostu D, Ciobanu L, Piciu A, Lucaciu O, Campian RS, et al. The impact of proton pump inhibitors on bone regeneration and implant osseointegration. *Drug Metab Rev* 2019; 51(3): 330–9. [CrossRef]
21. Jackson RA, McDonald MM, Nurcombe V, Little DG, Cool SM. The use of heparan sulfate to augment fracture repair in a rat fracture model. *J Orthop Res* 2006; 24(4): 636–44.
22. Nunamaker DM. Experimental models of fracture repair. *Clin Orthop Relat Res* 1998; 355 (Suppl): S56–65. [CrossRef]
23. Schmidmaier G, Wildemann B, Melis B, Krummrey G, Einhorn TA, Haas NP, et al. Development and characterization of a standard closed tibial fracture model in the rat. *European J Trauma* 2004; 30(1): 35–42. [CrossRef]



24. Radomsky ML, Aufdemorte TB, Swain LD, Fox WC, Spiro RC, Poser JW. Novel formulation of fibroblast growth factor-2 in a hyaluronan gel accelerates fracture healing in nonhuman primates. *J Orthop Res* 1999; 17(4): 607–14. [\[CrossRef\]](#)
25. Huo MH, Troiano NW, Pelker RR, Gundberg CM, Friedlaender GE. The influence of ibuprofen on fracture repair: biomechanical, biochemical, histologic, and histomorphometric parameters in rats. *J Orthop Res* 1991; 9(3): 383–90.
26. Vasconcelos JW, Leite LMDS, Vasconcelos GA, Araujo IMSM, Ferro LSG. Evaluation of simvastatin in the process of fracture healing in tibiae of rats. *Rev Bras Ortop* 2013; 48(2): 191–5. [\[CrossRef\]](#)
27. Thong BKS, Ima-Nirwana S, Chin KY. Proton pump inhibitors and fracture risk: A review of current evidence and mechanisms involved. *Int J Environ Res Public Health* 2019; 16(9): 1571. [\[CrossRef\]](#)
28. Menger MM, Bremer P, Scheuer C, Rollmann MF, Braun BJ, Herath SC, et al. Pantoprazole impairs fracture healing in aged mice. *Sci Rep* 2020; 10(1): 22376. [\[CrossRef\]](#)
29. Al Subaie A, Emami E, Tamimi I, Laurenti M, Eimar H, Abdallah MN, et al. Systemic administration of omeprazole interferes with bone healing and implant osseointegration: an *in vivo* study on rat tibiae. *J Clin Periodontol* 2016; 43(2): 193–203. [\[CrossRef\]](#)
30. Gul M, Dundar S, Bozoglan A, Ozcan EC, Tekin S, Yildirim TT, et al. Evaluation of the effects of the systemic proton pump inhibitor-omeprazole on periimplant bone regeneration and osseointegration: An experimental study. *J Oral Biol Craniofac Res* 2022; 12(3): 381–4. [\[CrossRef\]](#)