

# Pain During Mammography: A Prospective Cohort Study

✉ **Muhammet Ahmet Karakaya**<sup>1,2</sup>, ✉ **Kamil Darçın**<sup>2,3</sup>

<sup>1</sup>Department of Anesthesiology and Reanimation, Acıbadem Ataşehir Hospital, İstanbul, Türkiye

<sup>2</sup>Department of Anesthesiology and Reanimation, Medipol University Hospital, İstanbul, Türkiye

<sup>3</sup>Department of Anesthesiology and Reanimation, Koç University Hospital, İstanbul, Türkiye

## ABSTRACT

**Objective:** Breast cancer is the most common malignancy in women. Mammography screening is crucial for early detection. However, breast compression can cause pain and may impact patients' participation. In this study, we aimed to determine the pain level perceived by patients during mammography examination with the visual analog scale (VAS).

**Materials and Methods:** The study included a total of 140 consecutive patients (all female, mean age of 51±9, between 35 and 89) who applied to the Radiology Department of a tertiary hospital and underwent mammography for screening or diagnostic purposes. Cases undergoing mammography-guided interventional procedures were not included. Immediately, after mammography, patients were asked to rate their pain levels under the compression effect of mammography on the VAS in a face-to-face interview with an anesthesiologist. A statistical analysis was performed to determine the association between the breast pattern, applied pressure, the results of the mammogram, and the VAS score.

**Results:** About 66% of the patients stated that they felt 4 or more pain during mammography compression. The median VAS was 5 (interquartile range: 4). Breast patterns affected the VAS score. The VAS score of 57% of the patients with fatty breasts and 77% of the patients with dense breasts reported pain with a VAS of 4 and above (Pearson Chi-square,  $p=0.01$ ). Applied pressure ( $p=0.07$ ) or the mammography results ( $p=0.31$ ) did not affect the VAS score.

**Conclusion:** Mammography is a moderately painful procedure. It is necessary to use pain-relieving strategies to stop women from avoiding mammography. All appropriate medical interventions, including algology, should be used in this situation.

**Keywords:** Breast cancer, breast pattern, mammography, pain, visual analogue scale

**How to cite this article:** Karakaya MA, Darçın K. Pain During Mammography: A Prospective Cohort Study. CM 2023;15(4):320-5

## INTRODUCTION

The most common cause of malignant tumors in women is breast cancer. The level of participation in screening program is crucial to its effective prevention.<sup>[1]</sup> On the other hand, breast compression is a crucial component of the mammography examination and is accomplished by lowering a compression paddle onto the breast.<sup>[2]</sup> Current mammography equipment only gives compression force and breast thickness as parameters to assess the degree of compression.<sup>[3]</sup>

Depending on the size of the breasts, this causes a very variable impression of discomfort or even pain throughout the process. It has been demonstrated that having pain during

a screening mammogram has a negative impact on subsequent attendance at screening programs.<sup>[4]</sup> In addition, some patients report pain lasting for days. Determining the associations of this pain will be the most important step in focusing on the solution to the problem.

Recognition and management of pain not only by imaging technicians and radiologists but also by algologists or anesthesiologists will be an important step in preventing leaks that may occur in screening programs. In this study, an anesthesiologist interviewed the patient and used a visual analog scale (VAS) to measure the level of pain that patients experienced during the mammogram and figure out possible associations.



**Address for Correspondence:** Muhammet Ahmet Karakaya, Department of Anesthesiology and Reanimation, Acıbadem Ataşehir Hospital, İstanbul, Türkiye

**E-mail:** muhammetahmetkarakaya@hotmail.com **ORCID ID:** 0000-0001-8026-4783

**Received date:** 21.08.2023

**Revised date:** 06.09.2023

**Accepted date:** 08.09.2023

**Online date:** 13.10.2023



## MATERIALS and METHODS

The investigation was conducted in the mammography unit of the Medipol University Hospital between October and November 2019. The study was carried out in accordance with the Declaration of Helsinki's guidelines, and the Ethical Committee approved the study (July 24, 2017-40/17). Each patient provided her consent without any obligation. The STROBE statement was used for reporting.

### Patient Population

This prospective cohort study included 140 consecutive ASA 1–2 patients who were referred to the mammography unit for screening or diagnostic mammography. Just after their mammograms, the patients spoke with an anesthesiologist (MAK or KD) and used the VAS to rate how much pain they had felt. At this point, informed consent was acquired. Patients undergoing mammography-guided interventional procedures were not included.

The patients were asked to rate their level of pain from mammography compression immediately after the procedure using a VAS. The VAS consists of a horizontal line with a value from 0 to 10, with 0 denoting no discomfort and 10 denoting the greatest conceivable pain.<sup>[5]</sup> Age, gender, maximum compression force (Newton-N), breast pattern, and mammography results were the data collected through DICOM data or interpretation reports.

### Statistical Analysis

We found that a sample size of at least 128 patients was required to achieve statistical significance with a power of 95% and a significance level of 0.05 based on power analysis. SPSS 22.0 software (IBM BM Corp., New York, NY; formerly SPSS Inc., Chicago, IL, US) was used for the statistical analysis. Categorical data are reported as counts and percentages, while continuous variables are shown as the mean and standard deviation. The Kolmogorov-Smirnov test was used to verify the data's distribution. A statistical analysis was done to determine the association between the breast pattern, applied pressure, the results of the mammogram, and the VAS score by Chi-square or Fisher's Exact Test. All analyses were two-tailed, and  $p < 0.05$  was considered statistically significant.

## RESULTS

140 female patients (mean age of  $51 \pm 9$ , between 35 and 89) referred to our mammography unit for screening or diagnostic mammography were enrolled.

### Maximum Compression Force

The mean compression force for all mammograms in the study was  $188 \pm 5$  N and ranged from 170 N to 199 N. There was no significant difference in VAS scores between those who had a compression force  $\geq 188$  N and those with a compression force  $< 188$  N when we used the mean value of 188 N as the threshold ( $p = 0.07$ , Table 1 and Fig. 1).

### Breast Pattern

Based on the American Radiology College classification, 30 women (22%) had type A (fatty) breast patterns, 44 (31%) B (fatty), 58 (41%) C (dense), and 8 (6%) D (dense) breast patterns. There was a significant difference in VAS scores between those who had a fatty breast pattern and those with a dense breast ( $p = 0.01$ , Table 1 and Fig. 1). 77 percent of women with dense breasts reported a VAS score of 4 or higher, compared to 57% of women with fatty breasts who reported a VAS score of 4 or higher.

### Mammography Results

There was no significant difference in VAS scores among the patients with benign (BI-RADS 1, 2, 3) and suspicious (BI-RADS 4, 5) mammography results ( $p = 0.31$ , Table 1 and Fig. 1). 67% of patients in the benign group who received mammograms reported pain of 4 or more on the VAS scale, compared to 50% of the women who received suspicious results who reported pain of 4 or more on the same scale.

### Pain Experienced During Mammography

66% of the patients stated that they felt 4 or more pain during mammography compression. The median VAS was 5 (interquartile range: 4). Breast patterns affected the VAS score (Fig. 2). Women with denser breasts experienced more painful examinations than those with fatty breasts (77% vs. 57%) with a VAS of 4 and above (Pearson Chi-square,  $p = 0.01$ ). Applied pressure ( $p = 0.07$ ) or the results of the mammogram ( $p = 0.31$ ) did not affect the VAS score.

## DISCUSSION

This study showed that mammography is a moderately painful procedure, and the breast structure of the woman affects the pain felt.

One of the most common malignancies in the world is breast cancer. Early identification and treatment using screening techniques like self-examination, clinical examination, and mammography can increase survival rates and lower mortality. While routine breast screening is necessary to identify breast cancer in its earliest stages, not all women follow this

**Table 1. Statistical results**

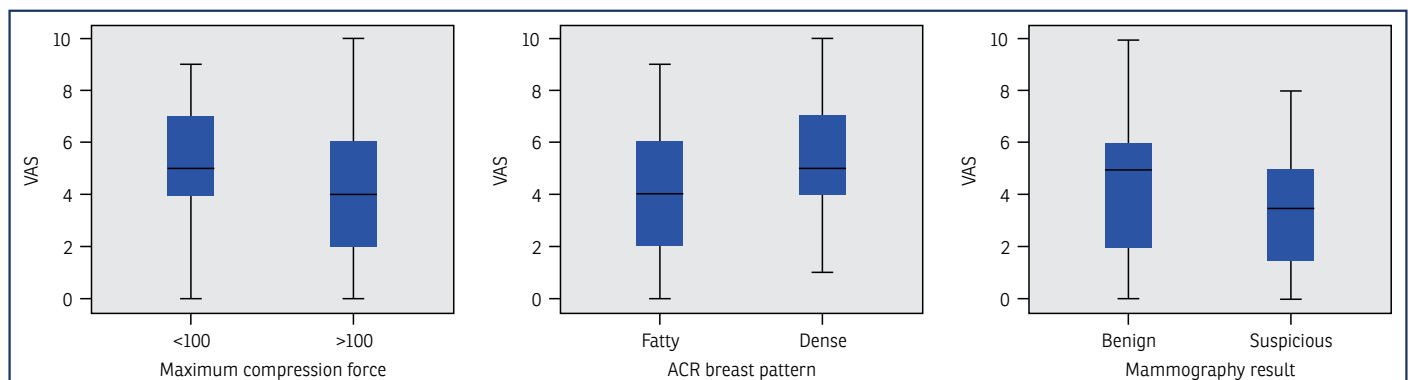
140 female patients (mean age of 51±9, between 35 and 89)	VAS				p
	<4		≥4		
	n	%	n	%	
Maximum compression force mean: 188±5 N (170 N–199 N)					
<188 N	11	23	36	77	0.07*
≥188 N	36	39	57	61	
Breast pattern					
Fatty type A:30 (22%) type B: 44 (31%)	32	43	42	57	0.01**
Dense type C: 58 (41%) type D: 8 (6%)	15	23	51	77	
Mammography results					
Benign	43	33	89	67	0.31***
Suspicious	4	50	4	50	

\*: Pearson Chi-square; \*\*: Significant result; \*\*\*: Fisher’s exact test. VAS: Visual analogue scale

regimen.<sup>[6,7]</sup> Personal factors (knowledge, sociodemographic factors, cost and insurance, cultural factors, belief, attitudes, fear, pain, embarrassment, self-efficacy, religious, psychological factors, time constraints, fatalism), professional factors (professional recommendations, communication), and social factors (social support, access) are potential barriers to breast cancer screening compliance.<sup>[8,9]</sup> A study on women who refuse recall for additional mammography assessment after screening found that the pain of the procedure is one reason why women opt out.<sup>[10]</sup> In addition, women could be less eager to screen because of the discomfort of getting mammograms.<sup>[11]</sup> Therefore, there may be a tendency for examinations in which there is no pain caused by compression

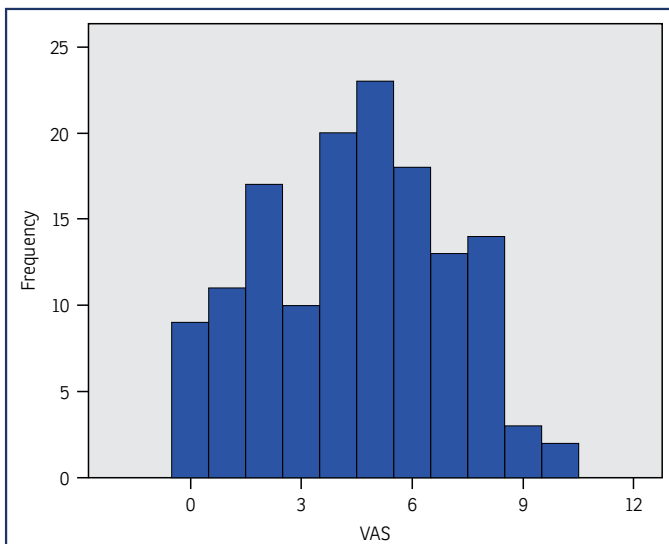
or avoidance of screening. However, mammography is an essential component of breast cancer screening. It is crucial that all relevant professionals, including general practitioners, radiologists, and algologists, identify the potential sources of pain, raise awareness of this issue among physicians, and develop a strategy to combat it to prevent screening programs from being disrupted.<sup>[9]</sup>

The breast can be evaluated with its anatomical integrity on mammography. Additionally, it is the only mammography that can consistently reveal calcifications that could be associated with early breast cancer. With successive follow-ups over time, mammography makes it possible to de-



**Figure 1.** The box plot shows the distribution of visual analogue scale scores based on maximum compression force, ACR breast pattern, and mammography results

VAS: Visual analog scale; ACR: American College of Radiology



**Figure 2.** Distribution of visual analog scale scores in the study population

VAS: *Visual analog scale*

tect silent abnormalities.<sup>[12]</sup> All these are possible with high image quality. Image quality cannot be high enough without compression either. By compression, radiation dose and scatter are reduced, the superimposition of breast tissues is diminished, and contrast is improved. However, compression leads to pain as well. Painful mammography can influence screening practices even in the absence of breast cancer symptoms<sup>[13]</sup> and discourage women from getting mammograms.<sup>[14,15]</sup> In this study, it was found that the pain felt did not change with the applied compression force. Although this is an interesting result, it may be an indication of cooperation with the patient during the examination. We think that this is not due to a lack of standardization but to the lack of a standard normal anatomy of the breast in women. The volume and composition of the breast show significant individual differences. The fact that the compression force does not affect pain may be an indication that it is used appropriately in this changing anatomy, contrary to the literature.<sup>[16]</sup> Similarly, a study comparing the mammography experience of patients using a manually controlled self-compression tool with their previous experience based on technician-performed compression showed that the manually controlled self-compression decreased the pain and anxiety of women during mammography.<sup>[17]</sup>

Mammography-derived pain varies in studies. It varies between studies from 6% to 32%.<sup>[18]</sup> Actually, we did not find any study on the association between breast pattern and

pain resulting from mammography examination. The breast composition or pattern caused a change in the pain felt in this study. More severe pain was felt in the dense breasts. The tissue that is sensitive to pressure in the breast tissue could be the milk glands and ducts, which are hormone sensitive. Therefore, it is an expected result that the pain is felt more in the dense breast pattern, where it is proportionally higher. In a study that examined pain experience and breast compression mechanics in mammography in two ways as a function of breast size, progression in the time proposed two possible approaches for pain-preventing strategies: personalized compression by using a target pressure and a shorter clamping phase.<sup>[19]</sup> In our clinical practice, we use some arrangements. To lessen the pain experienced during compression, the patient should be examined by mammography after the 4<sup>th</sup> or 5<sup>th</sup> day of the menstrual cycle. Pain should be tolerated, especially in the mornings. Therefore, morning hours are preferred for women with pain. The amount of discomfort experienced will be lessened if the compression is not applied solely to the breast but also partially to the chest wall, including the breast areas at the rear. In addition, an algology consultation may be an alternative to help the patient feel better if the discomfort lasts longer than a few days. A climate of trust can be established just by the patient's consultation, preventing the mammography-related pain from developing into a trauma.

Mammography interpretation results have no impact on the discomfort of the procedure in this study. This might be because there weren't as many patients in the suspicious group. In this limited group, there are also no benign or malignant inflammatory disorders. There were also some other limitations. The influence of breast size and/or menstrual cycle on breast pain and discomfort was not taken into account. Other factors include a small sample size and possible population bias. In addition, the duration of the pain was not taken into consideration. No duration of the pain and no pain perception during the mammography examination were measured. No information about the evaluation of the pain level was given before the procedure. No anesthesiologist accompanied the procedure. A standard examination was applied. The interview occurred immediately after the procedure. For us, this research served as an initial impetus for paying more attention to this problem. In particular, our next task is to find more, and especially preventable, frequent causes of pain, follow up with patients and, if necessary, treat pain following the procedure, and contribute to screening as anesthesiologists or algologists in the rising incidence of breast cancer by preventing mammography opposition.

There aren't many articles that claim mammography harms the body. In a case report from 2016, a lady in her 60s experienced ongoing pain and a hematoma following mammography. However after carefully reading the report, it became clear that this situation belonged to a massive (11 cm) interval cancer.<sup>[20]</sup> In addition, cutaneous bruising following mammography has been documented in the past. In this paper, the source of this has simply been the radiographers' enthusiasm for obtaining high-quality films.<sup>[21]</sup> It is well acknowledged that mammography does not result in severe physical harm. Mammography-related pain is an acute, temporary, self-limiting pain that often disappears within 10 min.<sup>[22]</sup> Patient-controlled compression, Diffraction Enhanced Imaging, which does not require breast compression, and pharmaceutical pain treatment on the day of the mammogram, – which includes sedatives or painkillers – have all received attention. However, large series and randomized-controlled research is required to address these issues.<sup>[22]</sup>

## CONCLUSION

In conclusion, getting a mammogram is a moderately painful procedure. Pain-decreasing and relieving techniques must be employed to prevent women from avoiding mammography. In this context, all acceptable means of medicine, even algology, should be used.

## Disclosures

**Acknowledgement:** We would like to thank Prof. Irmak Durur Subaşı and Assist. Prof. Abdulkadir Eren from Medipol Mega University Hospital, Department of Radiology, Breast Imaging Unit for their scientific support.

**Ethics Committee Approval:** The study was approved by the Ethical Committee (No: 40/17, Date: 24/07/2017).

**Informed Consent:** Written informed consent was obtained from all patients.

**Peer-review:** Externally peer reviewed.

**Authorship Contributions:** Concept: M.A.K., K.D.; Design: M.A.K., K.D.; Supervision: M.A.K., K.D.; Funding: M.A.K., K.D.; Materials: M.A.K., K.D.; Data Collection or Processing: M.A.K., K.D.; Analysis or Interpretation: M.A.K., K.D.; Literature Search: M.A.K., K.D.; Writing: M.A.K., K.D.; Critical review: M.A.K., K.D.

**Conflict of Interest:** No conflict of interest was declared by the authors.

**Financial Disclosure:** The authors declared that this study received no financial support.

## REFERENCES

1. Montoro CI, Alcaraz MDC, Galvez-Sánchez CM. Experience of pain and unpleasantness during mammography screening: a cross-sectional study on the roles of emotional, cognitive, and personality factors. *Behav Sci (Basel)* 2023;13:377. [\[CrossRef\]](#)
2. Hertel M, Makvandi R, Kappler S, Nanke R, Bildhauer P, Saalfeld S, et al. Towards a biomechanical breast model to simulate and investigate breast compression and its effects in mammography and tomosynthesis. *Phys Med Biol* 2023;68. [\[CrossRef\]](#)
3. Hertel M, Liu C, Song H, Golatta M, Kappler S, Nanke R, et al. Clinical prototype implementation enabling an improved day-to-day mammography compression. *Phys Med* 2023;106:102524. [\[CrossRef\]](#)
4. Moshina N, Sagstad S, Holen ÅS, Backmann HA, Westermann LC, Hofvind S. Experience of pain during mammographic screening by three different compression paddles. *Radiography (Lond)* 2023;29:903–10.
5. Haefeli M, Elfering A. Pain assessment. *Eur Spine J* 2006;15(Suppl 1):S17–24. [\[CrossRef\]](#)
6. Bakarman M, Kalthoum D, Wahby Salem I, Alshuaibi RO, Almohammadi TA, Beser RA, et al. Barriers to using breast cancer screening methods among adult females in Jeddah, Saudi Arabia: a cross-sectional study. *Cureus* 2023;15:e41739. [\[CrossRef\]](#)
7. Jones T, Wisdom-Chambers K, Freeman K, Edwards K. Barriers to mammography screening among black women at a community health center in South Florida, USA. *Med Res Arch* 2023;11. [\[CrossRef\]](#)
8. Ponce-Chazarri L, Ponce-Blandón JA, Immordino P, Giordano A, Morales F. Barriers to breast cancer-screening adherence in vulnerable populations. *Cancers (Basel)* 2023;15:604. [\[CrossRef\]](#)
9. Momenimovahed Z, Tiznobaik A, Taheri S, Hassanipour S, Salehiniya H. A review of barriers and facilitators to mammography in Asian women. *Ecancermedicalscience* 2020;14:1146. [\[CrossRef\]](#)
10. Sung WY, Yang HC, Liao IC, Su YT, Chen FH, Chen SL. Experiences of women who refuse recall for further investigation of abnormal screening mammography: a qualitative study. *Int J Environ Res Public Health* 2022;19:1041. [\[CrossRef\]](#)
11. Kuo CP, Li PC, Chuang HL, Lee SH, Liao WC, Lee MS. The effect of multimedia health education on pain and anxiety in women undergoing mammography in Taiwan. *Taiwan J Obstet Gynecol* 2021;60:1084–9.
12. Durur Subasi I. Breast imaging for non-radiologists. *Erciyes Med J* 2022;44:129–37. [\[CrossRef\]](#)
13. Petro-Nustas W. Young Jordanian women's health beliefs about mammography. *J Community Health Nurs* 2001;18:177–94. [\[CrossRef\]](#)
14. Straughan PT, Seow A. Attitudes as barriers in breast screening: a prospective study among Singapore women. *Soc Sci Med* 2000;51:1695–703.
15. Kang HS, Thomas E, Kwon BE, Hyun MS, Jun EM. Stages of change: Korean women's attitudes and barriers toward mammography screening. *Health Care Women Int* 2008;29:151–64. [\[CrossRef\]](#)
16. Waade GG, Sebuødegård S, Hogg P, Hofvind S. Breast compression across consecutive examinations among females participating in BreastScreen Norway. *Br J Radiol* 2018;91:20180209. [\[CrossRef\]](#)
17. Ulus S, Kovan Ö, Arslan A, Elpen P, Arıbal E. A new technical mode in mammography: self-compression improves satisfaction. *Eur J Breast Health* 2019;15:207–12. [\[CrossRef\]](#)
18. Miller D, Livingstone V, Herbison P. Interventions for relieving the pain and discomfort of screening mammography. *Cochrane Database Syst Rev* 2008;2008:CD002942. [\[CrossRef\]](#)
19. de Groot JE, Broeders MJ, Grimbergen CA, den Heeten GJ. Pain-preventing strategies in mammography: an observational study of simultaneously recorded pain and breast mechanics throughout the entire breast compression cycle. *BMC Womens Health* 2015;15:26. [\[CrossRef\]](#)

20. van Netten JP, Hopton Cann S, Thornton I, Finegan R. Growing concern following compression mammography. *BMJ Case Rep* 2016;2016:bcr2016216889. [\[CrossRef\]](#)
21. Hugh TB. Cutaneous bruising after mammography. *Med J Aust* 1991;154:712.
22. Sapir R, Patlas M, Strano SD, Hadas-Halpern I, Cherry NI. Does mammography hurt? *J Pain Symptom Manage* 2003;25:53–63. [\[CrossRef\]](#)