



Spuriously High Levels in a Patient After Total Parathyroidectomy with Forearm Auto-Transplantation

Total Paratiroidektomi ve Önkol Ototransplantasyonu Yapılan Bir Hastada Sahte Yüksek Düzeyler

Özge Kama Başçı,¹ Nilüfer Özdemir,² Zeliha Hekimsoy²

ABSTRACT

Primary hyperparathyroidism is an endocrine disease characterized by hypercalcemia-specific symptoms and signs with elevated parathormone (PTH). It can be accompanied by one or more adenomas, hyperplasia, or rarely parathyroid carcinoma. Parathyroidectomy is commonly used for treatment. Post-operative hypocalcemia or recurrent hyperplasia may develop so patients should be closely monitored. In this case report, a patient with isolated elevation of PTH levels, 2 years after total parathyroidectomy and forearm auto-transplantation, is presented. Detection of spuriously elevated PTH levels in the transplanted forearm may lead to misdiagnosis of recurrent hyperparathyroidism. If PTH levels remain high in patients with forearm auto-transplantation, it is essential to measure PTH levels in both arms.

Keywords: Forearm auto-transplantation; Parathyroid adenoma; Primary hyperparathyroidism.

ÖZET

Primer hiperparatiroidizm; parathormon yüksekliği ile birlikte hiperkalsemiye özgü semptom ve bulgularla seyreden bir endokrin hastalıktır. Bir veya daha fazla adenom, hiperplazi ya da nadiren paratiroid karsinomu eşlik edebilir. Tedavide yaygın olarak paratiroidektomi uygulanır. Operasyon sonrası hipokalsemi ya da nöks hiperplazi gelişebilir. Bu nedenle hastalar yakından izlenmektedir. Bu olgu sunumunda total paratiroidektomi ve ön kol ototransplantasyonundan 2 yıl sonra parathormonda izole yükseklik saptanan bir hasta sunuldu. Nakil yapılmış ön koldan alınan kanda yalancı yüksek parathormon düzeylerinin saptanması, rekürren hiperparatiroidizm yanlış tanısına yönlendirebilir. Bu yazıda parathormon düzeylerinin, ön kol ototransplantasyonu yapılan hastalarda yüksek seyretmesi halinde her iki koldan ölçüm yapılması vurgulanmaktadır.

Anahtar sözcükler: Primer hiperparatiroidizm; paratiroid adenomu; ön kol ototransplantasyonu.

Hyperparathyroidism (HPTH) is a common disorder characterized by enlargement in one or more parathyroid glands and consequent overproduction of parathormone (PTH). It is classified as primary, secondary, and tertiary. It is commonly seen with an adenoma in one (80%) or more glands (10–15%), accompanied with elevated PTH levels and hypercalcemia.^[1] Primary HPTH may be familial in 5% of cases,

within the MEN-1, MEN-2A, and familial isolated HPTH syndromes.^[2] HPTH is seen in almost 75% of MEN-1 cases and 25% of MEN-2A cases.^[3]

The patients with mild HPTH are at higher risk for kidney stones, cortical bone loss, and fractures. For diagnosis, serum calcium, serum phosphorus, intact parathyroid hormone, 25-hydroxyvitamin D level, glomerular filtration rate, 24-h urinary calcium excretion, and bone min-

¹Department of Internal Medicine, Balıkesir State Hospital, Balıkesir, Türkiye
²Department of Endocrinology and Metabolism, Faculty of Medicine, Celal Bayar University, Manisa, Türkiye

Cite this article as:

Kama Başçı Ö, Özdemir N, Hekimsoy Z. Spuriously High Levels in a Patient After Total Parathyroidectomy with Forearm Auto-Transplantation. Bosphorus Med J 2023;10(1):54–58.

Received: 09.08.2022

Revision: 12.09.2022

Accepted: 13.09.2022

Correspondence:

Dr. Özge Kama Başçı, Balıkesir Devlet Hastanesi, İç Hastalıkları Kliniği, Balıkesir, Türkiye

Phone:

+90 266 243 24 00

e-mail:

ozgee.kama@gmail.com

OPEN ACCESS



This work is licensed under a Creative Commons Attribution-NonCommercial 4.0 International License.

eral densitometry are used. Renal imaging may be requested to evaluate for nephrolithiasis.^[4] Ultrasound, Tc99M sestamibi, and 4-dimensional CT are used to determine the localization. Surgical treatment is performed in asymptomatic patients meeting the proper criteria and cases with symptomatic hypercalcemia. One of these surgical procedures, parathyroidectomy with parathyroid tissue auto-transplantation, is an important technique to prevent permanent hypoparathyroidism.

High success rate (55–100%) is provided with parathyroid tissue implantation to sternocleidomastoid or brachioradial muscles in patients with HPTH that require total/subtotal parathyroidectomy.^[5] After this procedure, recurrent hyperplasia or hypoparathyroidism in graft tissues can be rarely seen.^[6] Contradictory results in both laboratory and imaging can occur in differential diagnosis of graft tissue in the etiology of recurrent HPTH after auto-transplantation. In this report, the patient who developed parathyroid hormone elevation, without clinical and imaging findings after three and half gland parathyroidectomised and half of one gland forearm auto-transplantation is presented.

Case Report

A 40-year-old female patient was diagnosed with gastric ulcer at another health center and applied to our polyclinic after calcium (Ca) and PTH elevations were detected. The laboratory tests were revealed the diagnosis of hypercalcemia and

HPTH (Table 1). The neck ultrasonography revealed parathyroid adenoma of 19x8x20 mm in thyroid parenchyma in the left lobe and inferior parathyroid adenoma of 8x7x6 mm in the right lobe. Tc-99m MIBI parathyroid scintigraphy showed an image compatible with four parathyroid adenomas in superior and inferior of both lobes of the thyroid gland (Fig. 1). Total parathyroidectomy and forearm auto-transplantation were performed. In the follow-up examination after auto-transplantation, Chvostek and Trousseau signs were positive. Low Ca and PTH levels were observed.

Calcitriol and oral calcium supplementation therapy was started. During this process, the patient was investigated in terms of MEN-1 due to gastric ulcer history and primary HPTH development at a young age. Non-atrophic gastritis, lobulation in the anterior lobe of the pituitary gland, which may be

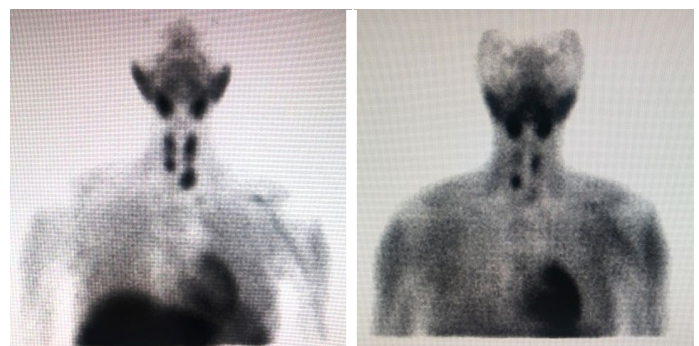

Figure 1. Tc-99m MIBI parathyroid scintigraphy images showing 4 parathyroid adenomas before surgery.

Table 1. Pre-operative and post-operative examinations of the patient for control purposes

Time	PTH (pg/ml)	Ca (mg/dl)	p (mg/dl)	Vitamin D 25-OH (ng/ml)	24-h urinary Calcium (mg/24 h)	Albumin
PRE-OPERATIVE	1031	11.8	2.6	12	681.6	4
POST-OPERATIVE						
Day 1	<2.5	7.8	1.1	12		3.3
Month 2	8	6	6.5	35	83.6	4.2
Month 3	-	7.7	6	-	92.4	4.5
Month 4	8	8.4	6.1	13	-	4.3
Month 5	-	9.4	4.9	-	124.8	4.8
Month 8	-	8.4	5.5	18	-	4.6
Month 10	9	9	5.8	12	-	4.1
Month 13	14	8.8	5.1	17	-	4.28
Month 15	134	8.4	4.6	10	208	4.1
Month 20	538	8.45	4.1	5	200.6	4.3
Month 20	1340	9.7	4.2			
Month 31	1435	10.1	2.9	4.5	195.5	4.1
Month 33	2819	9.7	3.3	15	-	4.2
Month 34	974	10.3	1.8	-	602.8	4.1

due to adenoma, and heterozygous MEN-1 mutation positivity were detected. However, the gastrin level was under 200 pg/mL. The patient was evaluated for pituitary hormones. All of the hormones were within normal range. According to the medical history, there was no history of HPTH in first-degree relatives. The children of the patient were examined for adenoma and HPTH. No positive sign has been found.

Twenty months after surgery, PTH was measured as 1340 pg/dl, and laboratory and imaging tests were collected (Table 1). Vitamin D replacement was started. While 25-OH-Vitamin D levels could be increased from <5 ng/mL to 15 ng/mL, PTH levels increased from 1340 pg/mL to 2819 pg/mL. Because of this unexpected increase, imaging was considered for concomitant recurrence. USG and scintigraphy imaging of the neck and parathyroid tissue in the transplanted forearm showed no signs of parathyroid hyperplasia or adenoma. Measured by double-energy X-ray absorptiometry, the bone mineral density of distal radius, femur hip, and spine was normal. The patient's neck was evaluated with magnetic resonance imaging and 4-dimensional computed tomography to detect recurrent adenomas. No adenoma was observed. She was admitted to the Endocrinology and Metabolic Diseases Service for further examination and treatment.

For the elevated PTH levels, hyperplasia of the gland transplanted to the forearm and MEN-1 was considered. During the patient's hospitalization, blood samples were taken simultaneously from both arms and the PTH levels were studied. There was a statistically significant difference between the PTH levels of the two arms. The PTH level was 1350 pg/mL in the blood sample taken from the parathyroid gland transplanted arm; however, it was 13.4 pg/mL in the sample taken from the contralateral arm (Fig. 2). Oral calcium treatment was discontinued because of the patient's normocalcemic

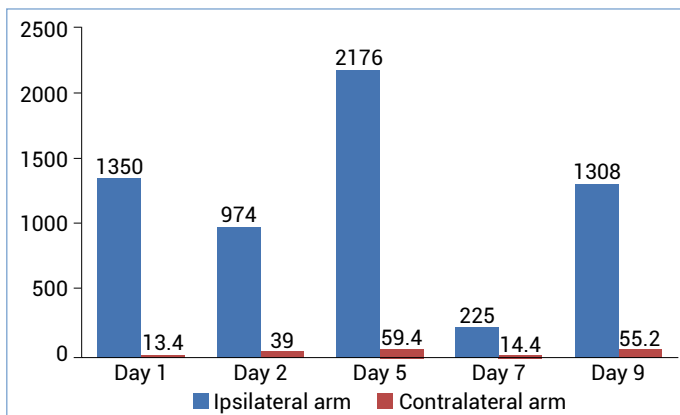


Figure 2. Comparison of PTH (ng/dL) levels between ipsilateral and contralateral arms of the parathyroid gland graft.

status. Two weeks after cessation of treatment, 24-h urinary Ca excretion, Ca and P levels were normal, but PTH levels were 974 pg/ml (Table 1). Serum gastrin level was 200 pg/ml. Prolactin was found to be 39 ng/ml (3.34–26.72 ng/ml) (Table 2). Calcium level was in the normal range in blood tests. No parathyroid adenoma was observed in the ultrasonography of the neck and left forearm (Fig. 3). Microadenoma of 7×5 mm was observed in the pituitary MRI (Fig. 4). No gastrointestinal or pancreatic tumor lesion was detected.

Table 2. Pituitary hormone levels

Hormone	Level	Normal range
FSH	9.55	4.54–22.51 mIU/mL
LH	7.97	1.20–12.86 mIU/mL
TSH	2.78	0.38–5.33 uU/mL
GH	<0.05	0.01–10 ng/ml
IGF-1	120	109–284 ng/ml
Prolactine	39	3.34–26.72 ng/ml

FSH: Follicle-Stimulating Hormone; LH: luteinizing hormone; TSH: Tiroit Stimule Edici Horman; GH: Growth hormon; IGF-1: Insulin-like growth factor 1.

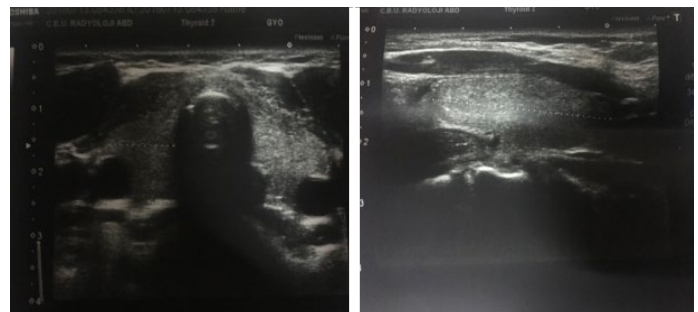


Figure 3. Ultrasonography of the neck and the grafted left front arm.

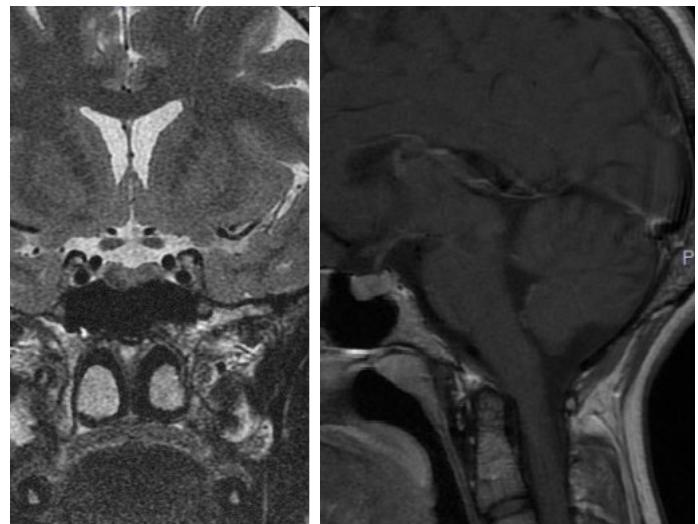


Figure 4. MRI showed a 7×5 mm microadenoma located in the adenohypophysis.

Discussion

HPTH is one of the most common endocrine disorders. The secondary HPTH findings such as renal failure, Vitamin D deficiency, and gastrointestinal diseases should be ruled out in patients with hypercalcemia and elevated PTH levels.^[7] In patients who require surgically removal of the parathyroid gland(s), close post-surgery follow-up is crucial. In this case, the presence of concomitant Vitamin D deficiency and normocalcemia in post-operative follow-up initially suggested HPTH secondary to Vitamin D deficiency. However, the unexpected increase in PTH levels in the follow-up despite replacement caused us to rush to investigate the accompanying recurrence. To exclude secondary HPTH, the case could have been followed with maintenance therapy until the Vitamin D level was above 30 ng/mL.^[8]

Recurrent elevated PTH levels after surgery may develop in the following conditions: Insufficient tissue removal, ectopic parathyroid gland, familial HPTH (MEN-1 syndrome and isolated familial HPTH), and hyper function of auto-transplant tissue.^[9,10] In our case, we first suspected MEN-1 because of a history of gastric ulcer at a young age, adenoma in all four parathyroid glands, and microadenoma in the pituitary gland.^[11] However, serum gastrin levels were not found to be significant for gastrinoma, no gastrointestinal or pancreatic tumor was observed, and no significant increase was observed in anterior pituitary hormones.

Follow-up of the patient showed normal calcium levels. In the ultrasonography of the neck and left forearm, neither differentiation and mass lesion at the incision site nor lesion compatible with parathyroid adenoma was observed (Fig. 4). A 7×5 mm microadenoma was observed in pituitary MRI. No gastrointestinal or pancreatic tumor lesion was detected. Therefore, the diagnosis of MEN-1 was excluded for the time being.

Studies about pituitary adenomas show that microadenomas can be seen in up to 10% of the healthy population.^[12] The PRL levels are expected to be above 100 ng/ml in microprolactinomas and above 200 ng/ml in macroprolactinomas.^[13]

In the literature, various methods are reported to reveal hyperfunction of the implanted tissue in the patients with high PTH levels after auto-transplantation. The most common methods are collecting blood samples simultaneously from both arms to compare PTH levels, and forearm ultrasonography and scintigraphy to show hyperplasia from the

implanted tissue.^[14]

Asymptomatic and isolated high PTH levels can be rarely seen in some post-operative patients. Although there are several hypotheses about the physiopathology of this condition, the literature still lacks articles regarding the mechanism. In the literature, only one report similar to our case was found.^[5]

One of our limitations was that we evaluated the patient with ultrasound and scintigraphy before performing systemic evaluation by taking a blood sample away from the graft site as stated in the literature. Our other limitation is that we could not achieve adequate levels of Vitamin D due to patient non-compliance and we could not exclude HPTH secondary to concomitant Vitamin D deficiency.

In patients with isolated high PTH levels after auto-transplantation, PTH levels should be measured from the graft sites and compared with the other arm. Reporting this kind of cases is important to prevent unnecessary and time-consuming laboratory examinations of the patients due to misleading positive results. Besides, unnecessary surgery of auto-transplanted patients after parathyroidectomy who were diagnosed with false recurrent HPTH can be prevented.

Disclosures

Informed consent: Written informed consent was obtained from the patient for the publication of the case report and the accompanying images.

Peer-review: Externally peer-reviewed.

Conflict of Interest: None declared.

Authorship Contributions: Concept – Ö.K.B., N.Ö.; Design – Z.H., Ö.K.B.; Supervision – Z.H., Ö.K.B.; Materials – N.Ö.; Data collection &/or processing – Ö.K.B., N.Ö.; Analysis and/or interpretation – N.Ö., Z.H.; Literature search – Ö.K.B.; Writing – Ö.K.B., N.Ö., Z.H.; Critical review – Ö.K.B., N.Ö., Z.H.

References

1. Madkhali T, Alhefthi A, Chen H, Elfenbein D. Primary hyperparathyroidism. *Ulus Cerrahi Derg* 2016;32:58–66.
2. Felger EA, Kandil E. Primary hyperparathyroidism. *Otolaryngol Clin North Am* 2010;43:417–32.
3. Bibik EE, Eremkina AK, Knyazeva OA, Mokrysheva NG. Sporadic primary hyperparathyroidism with multiple parathyroid adenomas. *Probl Endokrinol (Mosk)* [Article in Russian] 2021;67:31–8.
4. Insogna KL. Primary hyperparathyroidism. *N Engl J Med* 2018;379:1050–9.
5. Khalil D, Kerr PD. PTH monitoring after total parathyroidectomy with forearm auto-transplantation: Potential for spuriously high levels from grafted forearm. *J Otolaryngol Head Neck Surg*

- 2017;46:49.
6. Lo CY. Parathyroid autotransplantation during thyroidectomy. *ANZ J Surg* 2002;72:902–7.
 7. Holt EH, Inzucchi SE. Physiology and pathophysiology of the parathyroid glands and preoperative evaluation. In: Oertli, D., Udelsman, R. editors. *Surgery of the Thyroid and Parathyroid Glands*. Berlin, Heidelberg: Springer; 2007. p.235–43.
 8. Cipriani C, Pepe J, Colangelo L, Minisola S. Vitamin D and secondary hyperparathyroid states. *Front Horm Res* 2018;50:138–48.
 9. Conti-Freitas LC, Foss-Freitas MC, Lucca LJ, da Costa JA, Mamede RC, Foss MC. Dynamics of parathyroid hormone secretion after total parathyroidectomy and autotransplantation. *World J Surg* 2009;33:1403–7.
 10. Messa P, Alfieri CM. Secondary and tertiary hyperparathyroidism. *Front Horm Res* 2019;51:91–108.
 11. Balsalobre Salmeron M, Rodriguez Gonzalez JM, Ríos A, Febrero B, Parrilla Paricio P. Primary hyperparathyroidism associated with MEN 1: Experience in 71 cases. *Cir Esp (Engl Ed)* 2018;96:627–33.
 12. Langlois F, Fleseriu M. What to do with incidentally discovered pituitary abnormalities? *Med Clin North Am* 2021;105:1081–98.
 13. Leca BM, Mytilinaiou M, Tsoli M, Epure A, Aylwin SJB, Kaltsas G, et al. Identification of an optimal prolactin threshold to determine prolactinoma size using receiver operating characteristic analysis. *Sci Rep* 2021;11:9801.
 14. Li JG, Xiao ZS, Hu XJ, Li Y, Zhang X, Zhang SZ, et al. Total parathyroidectomy with forearm auto-transplantation improves the quality of life and reduces the recurrence of secondary hyperparathyroidism in chronic kidney disease patients. *Medicine (Baltimore)* 2017;96:e9050.