



Ocular Surface Squamous Neoplasia in Renal Transplant Patients

Anil Kaplan,¹ Taner Akalin,² Melis Palamar¹

¹Department of Ophthalmology, Ege University, Izmir, Türkiye

²Department of Pathology, Ege University, Izmir, Türkiye

Abstract

Transplantation surgery becomes more widespread with time worldwide; organ transplantation increases the risk of developing malignancies. This phenomenon is primarily due to immunosuppressive treatment which is one of the mainstay approaches to prevent transplant rejection. It is aimed to describe clinical signs and symptoms of histologically proven ocular surface squamous neoplasia (OSSN) in renal transplant patients. Three patients, who previously underwent renal transplant surgery, diagnosed with OSSN are presented. The histopathological examination results were conclusive for squamous cell neoplasia in all cases. No recurrence in any patients was observed after total surgical excision, cryotherapy, and reconstruction with amniotic membrane. Solid organ transplant patients undergo intense immunosuppressive treatment to prevent transplant rejection. That immunosuppressive treatment increases the risk of developing secondary malignancies including OSSN. It is important to inform all transplant patients about these risks. Even though OSSN is known to be a relatively benign acting tumor that rarely metastasizes to distant organs, the clinical course might change if it develops in an immunocompromised patient. For this reason, these patients should be monitored for any formation of a mass on the ocular surface. Surgical management through complete excision can result in the complete resolution of a tumor.

Keywords: Cornea, Eye, ocular surface squamous neoplasia, ocular surface, renal transplant

Introduction

Ocular surface squamous neoplasia (OSSN) is a spectrum of diagnoses ranging from intraepithelial neoplasia to invasive squamous cell carcinoma (SCC). OSSN prevalence has been documented as 0.03 cases per 100,000 people in the US and 1.9 cases per 100,000 people in Australia (1,2).

Organ transplantation increases the risk of developing malignancies. This phenomenon is primarily due to the immunosuppressive treatment which is one of the mainstay approaches to prevent transplant rejection. The risk of developing malignancies is increased 100 times in organ transplant patients, who are taking immunosuppressive treatment, compared to the general population (3).

Herein, three cases of OSSN in renal transplant patients are reported. Informed consent was taken from all cases for publication of their results and the study adheres to the tenets of the Helsinki Declaration. The study was approved by the Ethics Committee at Ege University (23-9T/14).

Case Report

Case 1 – A 52-year-old male presented with a mass on the left eye surface that developed 1 month ago. The best corrected visual acuity in the affected eye was 1.0 (Snellen). Slit lamp examination revealed a nasally located fluffy whitish vascularized conjunctival mass on the left eye extending to the cornea (Fig. 1).

How to cite this article: Kaplan A, Akalin T, Palamar M. Ocular Surface Squamous Neoplasia in Renal Transplant Patients. *Beyoglu Eye J* 2024; 9(3): 161-164.

Address for correspondence: Melis Palamar, MD. Department of Ophthalmology, Ege University, Izmir, Türkiye

Phone: +90 232 388 14 69 **E-mail:** melispalamar@hotmail.com

Submitted Date: January 08, 2024 **Revised Date:** May 01, 2024 **Accepted Date:** May 30, 2024 **Available Online Date:** September 01, 2024

Beyoglu Eye Training and Research Hospital - Available online at www.beyoglueye.com

OPEN ACCESS This is an open access article under the CC BY-NC license (<http://creativecommons.org/licenses/by-nc/4.0/>).



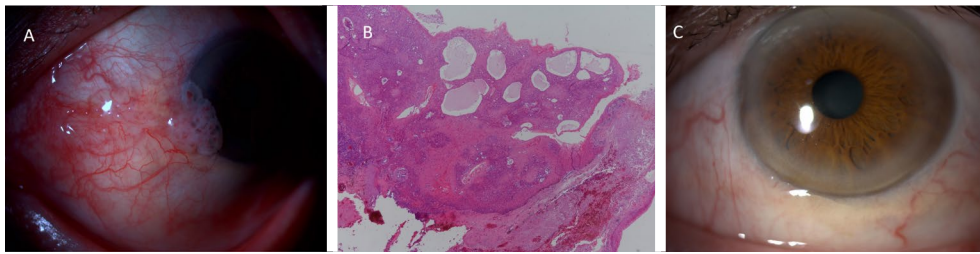


Figure 1. (a) Biomicroscopic photograph of the nasally located squamous cell carcinoma in situ in case. (b) Histopathological examination revealed an acanthotic epidermis with enlarged atypical keratinocytes and mitotic figures that reach full-thickness atypia namely squamous cell carcinoma in situ. (c) Anterior segment of the eye at the last visit.

Case 2 – A 66-year-old female presented to the clinic with itching and redness in the left eye. The best corrected visual acuity was 1.0 (Snellen) in the affected eye. Slit lamp examination of the left eye revealed a whitish, and vascularized conjunctival lesion extending to the cornea (Fig. 2).

For Case 1 and Case 2, total excision with adjunctive cryotherapy to the remaining conjunctival borders was performed. The cornea was scraped after alcohol application. The wound was primarily closed with 8/0 vicryl sutures. For both cases, histopathological examination revealed an acanthotic epidermis with enlarged atypical keratinocytes and mitotic figures that reach full-thickness atypia and SCC in situ was diagnosed (Fig. 1b). The surgical margins were clear. Follow-up visits were uneventful, and no recurrence was detected in a follow-up of 4 years (Fig. 1c) in Case 1 and for 5 years in Case 2.

For Case 1, the leukocyte numbers were in the normal range. However, when the blood counts of the last 3 years before the diagnosis of OSSN were examined, lymphocytosis, 30–35%, was predominantly detected for both Case 1 and Case 2. CD4 counts were not available.

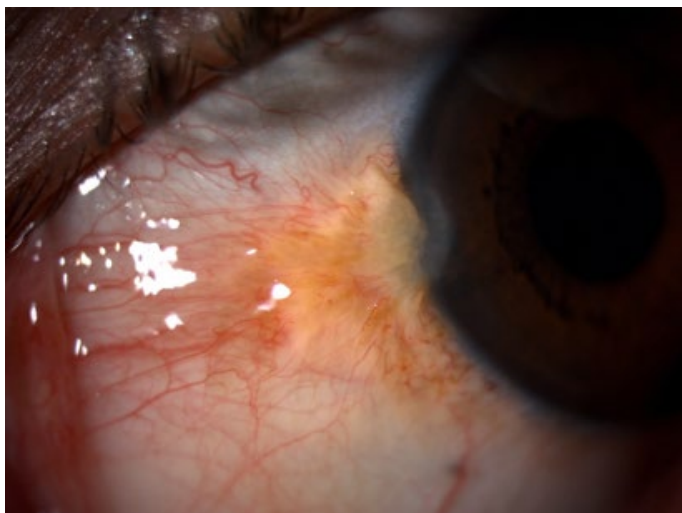


Figure 2. Nasally located whitish lesion in Case 2.

Case 3 – A 56-year-old male presented with redness and low vision in the left eye for 8 months. The visual acuity in the left eye was 0.2 (Snellen). On slit lamp examination a mass on the nasal perilimbal region extending through almost the whole cornea was detected (Fig. 3a). On anterior segment optic coherence tomography evaluation of the lesion epithelial thickening on both the conjunctival and corneal parts which were suggestive of OSSN was detected (Fig. 3b). Total excision of the lesion, corneal epitheliectomy with alcohol, cryotherapy to the conjunctival borders, and adjunctive ocular surface reconstruction with amniotic membrane under local anesthesia were performed (Fig. 3c). Histopathologic examination revealed maturation and misalignment of keratinocytes with moderate atypia in the squamous epithelium (Figs. 4a and b). Focal proliferative activity increase in keratinocytes (Fig. 4c, Ki-67) and p53 positivity (Fig. 4d). Findings were compatible with squamous intraepithelial neoplasia II-III. The visual acuity increased to 0.8 1 month after the surgery. No recurrence was detected in a follow-up of 9 months.

All 3 cases had a history of renal transplant and accordingly, they all underwent immunosuppressive treatment with corticosteroid 7.5 mg/day, mycophenolate mofetil 1 × 1, tacrolimus 1 × 1. None of the cases needed topical mitomycin C or 5-fluorouracil treatment in the post-operative period. Since all the surgical margins were free of tumor cells, the patients did not receive any topical treatment such as interferon. In addition, no change has been made to the systemic treatment of these patients after the diagnosis and the surgeries.

Discussion

Many risk factors have been identified for OSSN development. UV-B light, xeroderma pigmentosum, HIV, HPV, chronic irritants, smoking, vitamin A deficiency, fair skin, topical voriconazole use, and immune suppression due to pharmacotherapy are the known risk factors for the development of an OSSN (4,5).

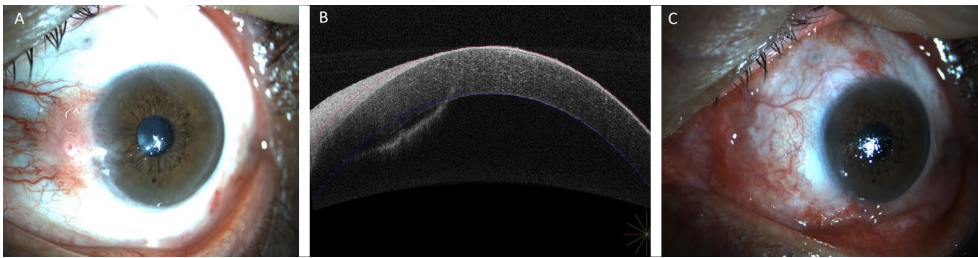


Figure 3. (a) Nasally located limbal mass extending to the cornea. (b) Anterior segment optic coherence tomography of the lesion demonstrating hyperreflective epithelial lesion on the cornea and on the conjunctiva. (c) Early postoperative photograph of the eye.

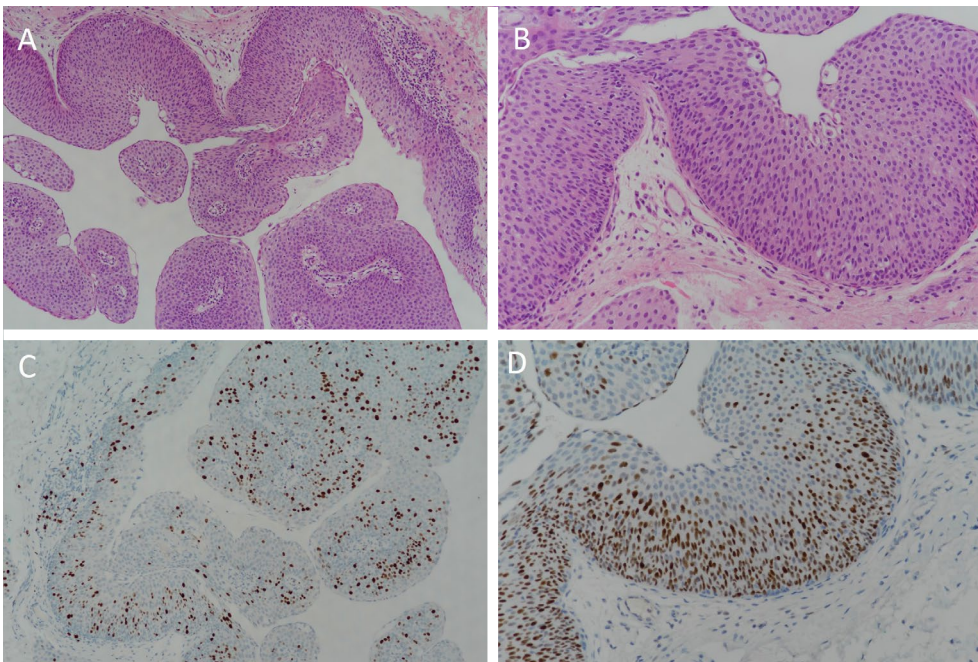


Figure 4. (a, b) Histopathologic examination revealed maturation and misalignment of keratinocytes with moderate atypia in the squamous epithelium. (c) Focal proliferative activity increases in keratinocytes (Ki-67). (d) p53 positivity is evident.

The development of OSSN in transplant patients has been documented in both liver and kidney transplant patients (6,7). The exact mechanism of OSSN development in transplant patients is still not completely understood. However, chronic immunosuppression due to pharmacotherapy, direct carcinogenic effects of immunosuppressive drugs such as azathioprine and tacrolimus, and chronic antigenic stimulation caused by transplanted organs are the hypothesized mechanisms to explain any tumor development in transplant patients (6).

Apart from OSSN, the prevalence of many other malignancies increases with any transplantation method. Among them, non-melanoma skin cancer is the most common malignancy in solid organ transplant patients. The risk is 60–250 times that of the general population (8). In addition to skin cancers, the risk of developing non-Hodgkin lymphoma, lung, liver, and kidney cancers also increases in transplant patients

(8,9). This higher risk is due to the immunosuppressive treatment given to prolong graft survival through preventing graft rejection. The same mechanism applies to corneal penetrating keratoplasty (PKP) as well and as a result, the risk of OSSN development is more likely in corneal PKP patients (2,5).

Malignancies developing in solid organ transplant patients are known to have a worse clinical prognosis than the general population (7). Secondary cancers in hematopoietic cell transplant (HCT) patients are responsible for 5–10% of deaths of those who live 2 years or longer after HCT (10).

OSSN is known to be a relatively benign acting tumor that rarely metastasizes to distant organs (11). Parallel to the literature, the presented three cases had benign clinical courses. However, it should always be kept in mind that the clinical course might change in an immunocompromised patient. For example, Shelil et al. reported a case of conjunc-

tival SCC in a liver transplant patient invading the brain and causing death even an orbital exenteration was performed (12). Moreover, the presented cases developed OSSN from a single focus. However, even if multifocality is a rare manifestation of OSSN, it was shown that OSSN in a renal transplant patient could be multifocal (13).

As transplantation surgery becomes more widespread with time, an increase in the development of OSSN is also expected. A close follow-up of the ocular symptoms of transplant patients is necessary in order not to miss a diagnosis of OSSN since it has a more aggressive clinical course compared to the general population (11).

Conclusion

In summary, patients undergoing solid organ transplant surgery should be informed about this incidence and they should be examined accordingly. Any lesion on the ocular surface of these patients should be handled with care and prompt treatment should be performed.

Disclosures

Informed consent: Written informed consent was obtained from the patients for the publication of the case report and the accompanying images.

Peer-review: Externally peer-reviewed.

Conflict of Interest: None declared.

Use of AI for Writing Assistance: Not declared.

Authorship Contributions: Concept – M.P., T.A., A.K.; Design – M.P., T.A., A.K.; Supervision – M.P.; Resource – M.P., T.A., A.K.; Materials – T.A.; Data Collection and/or Processing – A.K.; Analysis and/or Interpretation – M.P., T.A., A.K.; Literature Search – A.K., M.P.; Writing – M.P., T.A., A.K.; Critical Reviews – M.P., A.K.

References

1. Lee GA, Hirst LW. Ocular surface squamous neoplasia. *Surv Ophthalmol* 1995;39:429–50. [\[CrossRef\]](#)
2. Ramasubramanian A, Shields CL, Sinha N, Shields JA. Ocular surface squamous neoplasia after corneal graft. *Am J Ophthalmol* 2010;149:62–5. [\[CrossRef\]](#)
3. Yunus M, Aziz T, Mubarak M. Posttransplant malignancies in renal transplant recipients: 22-years experience from a single center in Pakistan. *Asian Pac J Cancer Prev* 2012;13:575–8.
4. Shah KJ, Mogilishetty G, Holland EJ. Ocular surface squamous neoplasia in a living-related conjunctival limbal allograft. *Cornea* 2016;35:274–6. [\[CrossRef\]](#)
5. Palamar M, Egrilmez S, Yilmaz SG, Polat SH, Gunduz OU. Does topical voriconazole trigger dysplastic changes on the ocular surface? *J Chemother* 2015;27:111–3. [\[CrossRef\]](#)
6. Macarez R, Bossis S, Robinet A, Le Callonnec A, Charlin JF, Colin J. Conjunctival epithelial neoplasias in organ transplant patients receiving cyclosporine therapy. *Cornea* 1999;18:495–7.
7. Pournaras JA, Chamot L, Uffer S, Zografos L. Conjunctival intraepithelial neoplasia in a patient treated with tacrolimus after liver transplantation. *Cornea* 2007;26:1261–2. [\[CrossRef\]](#)
8. Doshi MD. Cancer in solid organ transplantation. In: *Oncology Curriculum*. Ch. 16. American Society of Nephrology. Washington, DC; 2016. p. 11–92. [\[CrossRef\]](#)
9. Hall EC, Pfeiffer RM, Segev DL, Engels EA. Cumulative incidence of cancer after solid organ transplantation. *Cancer* 2013;119:2300–8. [\[CrossRef\]](#)
10. Majhail NS. Long-term complications after hematopoietic cell transplantation. *Hematol Oncol Stem Cell Ther* 2017;10:220–7. [\[CrossRef\]](#)
11. Fasina O. Ocular surface squamous neoplasia at a tertiary eye facility, Southwestern Nigeria: A 10-year review. *Int Ophthalmol* 2021;41:3325–31. [\[CrossRef\]](#)
12. Shelil AE, Shields CL, Shields JA, Eagle RC Jr. Aggressive conjunctival squamous cell carcinoma in a patient following liver transplantation. *Arch Ophthalmol* 2003;121:280–2. [\[CrossRef\]](#)
13. Shome D, Honavar SG, Manderwad GP, Vemuganti GK. Ocular surface squamous neoplasia in a renal transplant recipient on immunosuppressive therapy. *Eye (Lond)* 2006;20:1413–4. [\[CrossRef\]](#)