



# A Multicentric Cross-Sectional Observational Study to Analyze the Effects of Moderate High Altitude on Ocular Health

Vibhuti Maria,<sup>1</sup> Sanat Kumar Khanna,<sup>2</sup> Richa Chaudhary,<sup>3</sup> Saurabh Maheshwari<sup>4</sup>

<sup>1</sup>Department of Ophthalmology, Military Hospital Shimla, Shimla, India

<sup>2</sup>Department of Surgery, Military Hospital Shimla, Shimla, India

<sup>3</sup>Department of Ophthalmology, Command Hospital Chandigarh, Chandigarh, India

<sup>4</sup>Department of Radiodiagnosis and Imaging, Military Hospital Shimla, Shimla, India

## Abstract

**Objectives:** Prolonged exposure to hypoxia at high altitudes can affect the eyes through various mechanisms, culminating in reduced vision. Multiple studies on this subject have focused on the ocular effects of high altitude on intraocular pressure (IOP), corneal thickness, and the retina. However, there is a lack of literature on the effects of 'moderate high altitude (2000–3000 m)' on the eyes. Hence, we designed our study to determine the impact of moderate high altitude on the eyes.

**Methods:** We recruited two age and gender-matched groups of 250 research participants, each at moderate high altitude (Group A) and plains (Group B), respectively, to determine the effects of moderate high altitude on ocular health, if any.

**Results:** We found a statistically significant increase in dry eye in Group A. We also found four cases of central serous retinopathy and one case of central retinal vein occlusion in Group A. There was no statistically significant change in visual acuity, IOP, or central corneal thickness.

**Conclusion:** There is a vast lacuna in the literature on this particular altitude range, and further studies are required to confirm our findings. It is also recommended that lubricant eye drops be advised as a standard prophylactic measure for all individuals traveling and staying at moderate high altitude.

**Keywords:** Central retinal vein occlusion, central serous retinopathy, high altitude, military medicine, moderate high altitude, ocular health.

## Introduction

The eye is as susceptible to the effects of high altitude as multiple other organs of the human body (1), such as the lungs and brain. Prolonged exposure to hypoxia at high altitudes can affect the eyes through various mechanisms,

culminating in reduced vision (2). Multiple studies on this subject have focused on the ocular effects of high altitude on intraocular pressure (IOP), corneal thickness, and the retina.

However, there is a significant variation in the findings of various studies. For example, some groups have found an increase in IOP with a gain in altitude (3), whereas others have

**How to cite this article:** Maria V, Kumar Khanna S, Chaudhary R, Maheshwari S. A Multicentric Cross-Sectional Observational Study to Analyze the Effects of Moderate High Altitude on Ocular Health. *Beyoglu Eye J* 2024; 9(1): 48-54.

**Address for correspondence:** Vibhuti Maria, MD. Department of Ophthalmology, Military Hospital Shimla, Shimla, India  
**Phone:** 08967887449 **E-mail:** mariavibhuti@gmail.com

**Submitted Date:** June 22, 2022 **Revised Date:** March 09, 2023 **Accepted Date:** December 10, 2023 **Available Online Date:** March 01, 2024

*Beyoglu Eye Training and Research Hospital - Available online at [www.beyoglueye.com](http://www.beyoglueye.com)*

**OPEN ACCESS** This is an open access article under the CC BY-NC license (<http://creativecommons.org/licenses/by-nc/4.0/>).



shown a normal IOP (4,5), or even a decrease in IOP (6). There has even been a report of sudden transient reduction in IOP on the ascent to a high altitude of around 4300 m, which normalized during acclimatization (7). In contrast, there is broad agreement that hypoxia at high altitudes and extreme high altitudes leads to corneal swelling (2) and high altitude retinopathy (HAR). However, the incidence of HAR varies from 3.8% (8) to 90.5% (9) in different studies. In addition, there are other effects of high altitude on the eyes, including but not limited to dry eye, ultraviolet (UV) radiation damage, reduced night vision, reduced accommodation, and reduced visual field (10). It can also lead to pterygium and cataracts.

Most of the studies on this topic have been conducted (4,5,7) at “high altitude (3000–5500 m)” or “extreme high altitude (more than 5500 m)” (according to the classification in Table 1 proposed by Bärtsch et al.(11)). However, there is a lack of literature on the effects of “moderate high altitude (2000–3000 m)” on the eyes. Hence, we designed our study to determine the impact of moderate high altitude on the eyes.

## Methods

The authors conducted this cross-sectional observational study at two hospitals in Northern India. One hospital is located at an altitude of 2276 m, where the authors evaluated patients (Group A) from various altitudes ranging from 2100 to 2800 m. We selected an age and gender-matched control group at a second center located at plains (Group B) to compare the findings. Each group had 250 research participants, wherein a comprehensive ocular examination was done for 500 eyes (250 patients) in each group. Informed written consent was obtained from all the patients. Hence, we recruited two age and gender-matched groups of research participants at moderate high altitude and plains, respectively, to determine the effects of moderate high altitude on ocular health, if any.

The present study was approved by the ethical board of the hospital in which the study was performed. This study complied with the latest version of the Helsinki Declaration of 1964.

**Table 1.** Classification of high-altitude regions (Adopted from Bärtsch P, Saltin B, Dvorak J. Consensus statement on playing football at different altitudes. *Scandinavian journal of medicine and science in sports.* 2008 Aug; 18:96-9.)

Region	Definition (in terms of altitude)
Near sea level	0–500 m
Low altitude	500–2000 m
Moderate altitude	2000–3000 m
High altitude	3000–5500 m
Extreme altitude	More than 5500 m

In study Group A, we included subjects between 18 and 45 years of age. These subjects had varying degree of exposure to moderate high altitudes (2000–3000 m) for the first time in their life. We only included patients who had relatively prolonged exposure (at least for 1 year) to this altitude. In study Group B, we included age and gender-matched research participants who never had prolonged exposure to any type of high altitudes region. We excluded patients with pre-existing ocular symptoms, high refractive error, pre-existing glaucoma, ocular hypertension, uveitis, retinal or optic nerve disorders, or patients with a history of ocular trauma or surgery from both study groups. Native highlanders were excluded from the study.

A detailed history was recorded for all the patients, including the history of any ocular symptoms (reduced vision, eye strain, dry eye, redness of eyes, floaters, photophobia, increased tearing, and cloudy vision), duration of exposure to moderate high altitude, and any fresh ocular symptoms experienced in the high-altitude region. A general physical and systemic examination followed this to rule out comorbidities such as diabetes and hypertension. None of our patients were contact lens users.

The general ocular examination was followed by the measurement of best corrected visual acuity (BCVA), IOP measurement, and measurement of central corneal thickness. All patients were evaluated under slit-lamp, and dilated fundus examination was done. In addition, the patients were also evaluated for dry eye by performing the tear break-up time test and the Schirmer test. All 500 patients were evaluated between 900 and 1200 h to avoid the effect of diurnal variation on results.

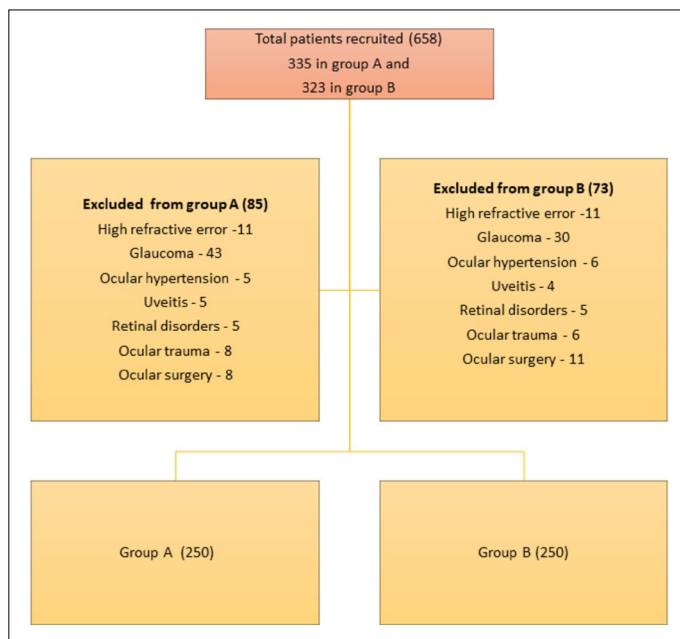
The IOP was measured using a non-contact tonometer, and the central corneal thickness was measured using a specular microscope. A mean of three readings was taken for each eye. Refraction was first measured using the auto refractometer for objective refractive error (a mean of three readings). The subjective assessment was then conducted using Snellen’s chart, trial lenses, and frame.

## Statistical Analysis

The authors performed statistical analysis using Statistical Package for the Social Sciences (SPSS) statistical software (SPSS, Chicago, IL, USA) Software Version 23.0. Descriptive statistics are presented in frequencies and percentages for categorical variables.

## Results

We included a total of 658 participants, out of which 335 were recruited in Group A, 323 were recruited in Group B. A total of 85 were excluded in Group A, and 73 were excluded in Group B due to various exclusion criteria. After the exclusion, Groups A and B had 250 participants each. This schema of the study is illustrated in Figure 1.

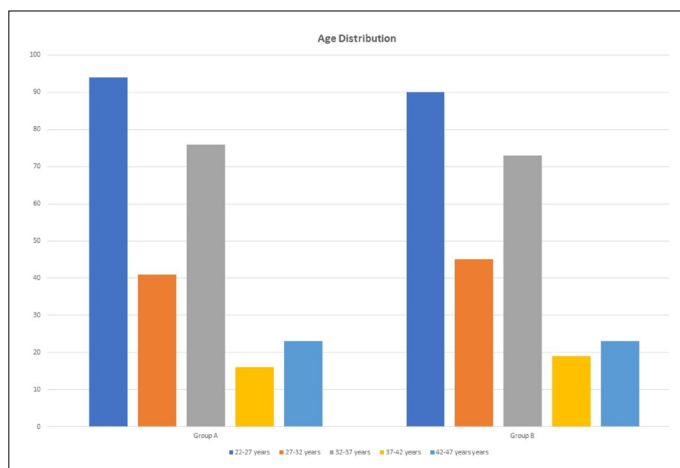


**Figure 1.** Scheme of the study.

Our study population ranged from 18 to 45 years of age, with the highest number of participants in the age group 22–27 years in both groups. These demographics are illustrated in Figure 2.

The mean duration of exposure to high altitude in subjects in Group A was 17 months (ranging from 12 months to 26 months). We collected history from the study participants in Group A for the occurrence of any acute ocular phenomenon previously reported in association with high altitude like acute angle-closure glaucoma or blurring of vision. There was no occurrence of retinal hemorrhages, cortical blindness, photoconjunctivitis, photophthalmia, or reduced color perception in the study population in Group A. There was a single case of conjunctivitis in the study population, which was likely to be viral in etiology as per the findings of clinical examination.

There was no significant difference in BCVA in Groups A



**Figure 2.** Age distribution in Group A and Group B.

and B. Similarly; there was no statistical difference in spherical or cylindrical refraction in the two groups.

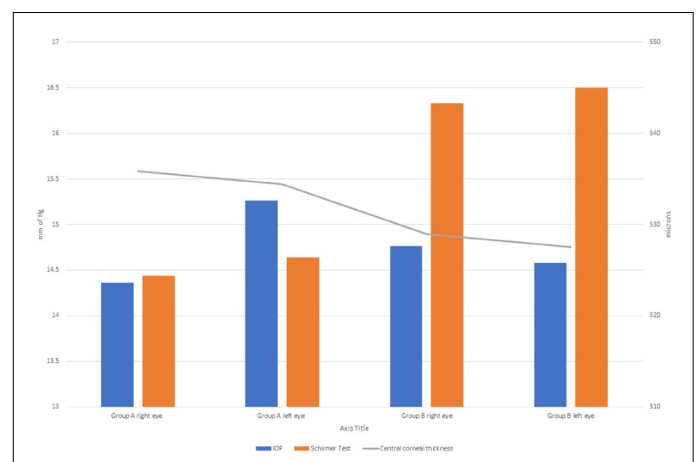
The mean IOP in Group A in the right eye was 14.36 mm of Hg (SD-2.83); in the left, it was 15.26 mm of Hg (SD-3.02). The mean IOP in Group B in the right eye was 14.76 mm of Hg (SD-2.55); in the left, it was 14.58 mm of Hg (SD-2.65). On analysis by paired t-test, there was no statistically significant difference between the two groups ( $p=0.45$ ).

The mean central corneal thickness in Group A in the right eye was 535.86 microns (SD-61.14); in the left, it was 534.43 microns (SD-20.11). The mean central corneal thickness in Group B in the right eye was 528.94 microns (SD-31.13), and in the left, it was 527.50 microns (SD-58.57). There was a mild increase in the corneal thickness in both eyes in Group A, which was not statistically significant ( $p=0.67$ ).

We found a statistically significant decrease in the value of Schirmer's test in Group A - suggesting an increase in dry eye. The mean value in Group A in the right eye was 14.44 s (SD-5.13); in the left, it was 14.64 s (SD-4.99). The mean value in Group B in the right eye was 16.33 s (SD-1.70); in the left, it was 16.50 (SD-1.65). This difference was significant, with a  $p<0.00001$ .

One of the interesting aspects of the study was that we found four cases of central serous retinopathy (CSR). These patients were aged between 25 and 32 years. They presented with complaints of blurring of vision and central scotoma in the central visual field. There was also one patient with central retinal vein occlusion (CRVO) who was 45 years old. He had presented with gross diminution of vision in the left eye. Although the literature shows an increased incidence of RVOs at high altitude 12, this particular patient was also found to have homocysteinemia, which might be a confounding factor for CRVO.

To summarize, the Student's paired t-test revealed a statistically significant increase in the dry eye in Group A. We also found four cases of CSR and one case of CRVO. There was no statistically significant change in visual acuity, IOP, or central corneal thickness. The results are summarized in Figure 3 and Table 2.



**Figure 3.** Comparison of key study parameters in Group A and B.

**Table 2.** Summary of results

	IOP (mm of Hg)	Schirmer test (mm)	Central corneal thickness (microns)
Group A right eye	14.36	14.44	535.86
Group A left eye	15.26	14.64	534.43
Group B right eye	14.76	16.33	528.94
Group B left eye	14.58	16.50	527.50
P-value between groups A and B	0.45	<0.00001	0.67

## Discussion

The adverse effects of high altitude on the eyes have been known for over a century, with a report published as early as 1918 (12). There has been a tremendous increase in exposure of the general population to high-altitude regions for mountaineering and adventure activities. There is also an increasing trend of lowlanders settling in high altitudes for various reasons. In addition, the topic is already vital to Armed Forces, which are more prone to these adverse effects due to their prolonged exposure and strenuous routine at high altitudes.

At near sea level, the fraction of inspired oxygen ( $FiO_2$ ) value is approximately 19.8–20.9%, which gradually decreases on the ascent to altitude such that it is around 14.8–16.7% at moderate high altitude of 2000–3000 m (13). This reduced  $FiO_2$  value represents natural stress. In addition, high solar UV radiation is also hazardous to the eyes at high altitudes (14). We have already emphasized that there is no data available on the effect of this moderate high altitude on the eyes, with most of the studies focusing on mountaineering expeditions working at very high and/or extreme altitudes.

### IOP

The IOP within the normal population ranges from 11 to 21 mm of Hg and varies with the time of day, heartbeat, blood pressure, and respiration (15). From a physiologic point of view, an active metabolic process (15) like aqueous humor secretion should reduce at high altitudes due to hypoxia and hypothermia. However, there is wide variation in the literature about change in IOP on the ascent to high altitude (3-6). However, various confounding factors may cause this variation, including but not limited to any physical exercise or the time of the day when IOP is measured. One of the trials on this topic found that IOP rises on arrival at altitude but reduces with time and returns to normal (16). The same study also proposes that increased episcleral venous pressure due to decreased oxygen saturation is the most likely cause of this transient increase in IOP. We did not find a significant change in IOP at moderate high altitude.

### The Cornea

It is well known that the cornea swells in response to hypoxia. This is most commonly associated with contact lens use. The normal human cornea swells by 7% per hour in an oxygen-free environment (17). There is also diurnal variation in central corneal thickness with a change of up to 3.9% overnight (18). The previous studies have shown a significant increase in corneal thickness with an increase in altitude (19). This is likely due to a combination of hypoxia and endothelial dysfunction (10). We did not find a significant change in central corneal thickness at moderate high altitude.

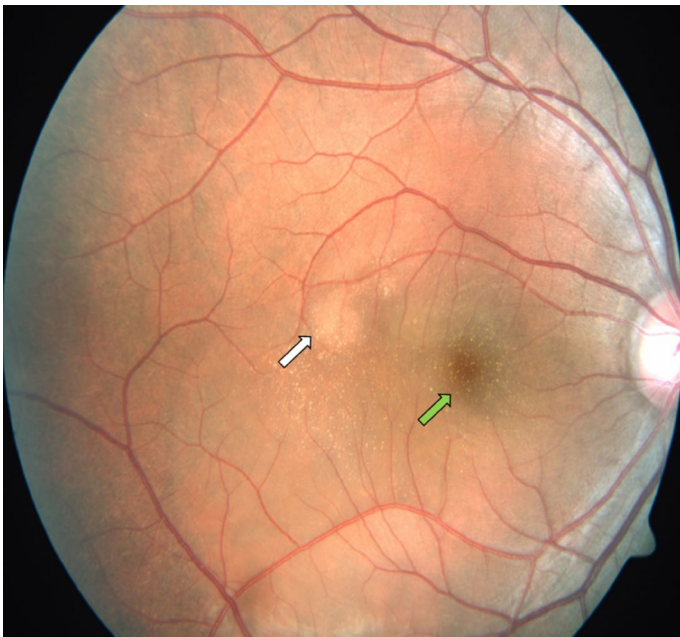
### HAR

The retinal vascular engorgement at high altitude was first described in 1918 by Wilmer and Berens (20). However, the first description of HAR is credited to Singh et al. (21) HAR is the pathological response of the retina to the hypoxia encountered at high altitude. This manifests as flame hemorrhages, cotton wool spots, dot and blot, and pre-retinal hemorrhages. It is usually asymptomatic, but a hemorrhage near the macula can cause vision disturbances, for which there are multiple case reports in the literature (22-24). These hemorrhages typically resolve without sequelae. Interestingly, there is a statistically significant correlation between HAR and high-altitude cerebral edema (9).

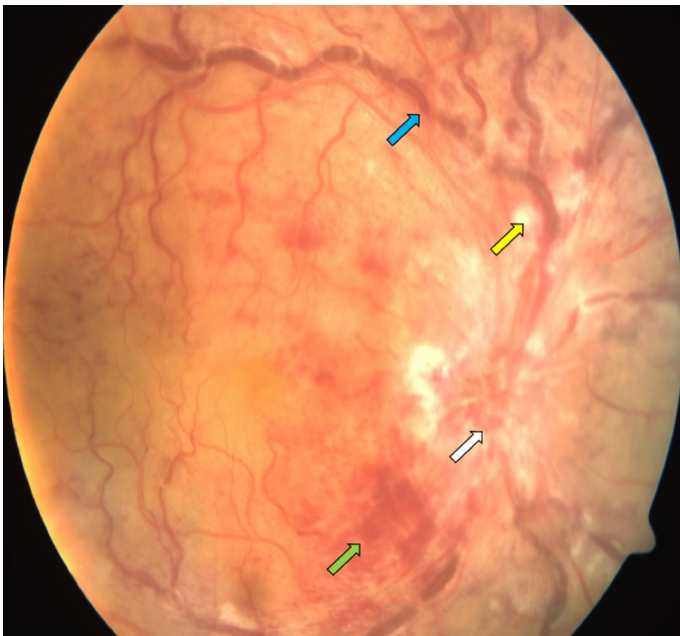
The incidence of HAR varies from 3.8%(8) to 90.5%(9) in different studies. The incidence increases with the maximum altitude attained (25). There are multiple theories for HAR's pathophysiology, including increased ocular blood flow, (24) increased IOP, (26) increased blood pressure, (5,26) raised intracranial pressure, (5,26) vascular dysregulation, (27) increased blood viscosity, (28) hypoxic endothelial decompensation, (29) and platelet microemboli (30).

We did not find any cases of HAR in our study. However, we found four cases of CSR and one case of CRVO in our study population. The association of CRVO (31) and CSR (32) with high altitude has been described in the literature (Figs. 4 and 5). However, this association requires further study.





**Figure 4.** Fundus photo shows subretinal fluid over macula (green arrow) and pigment epithelial detachment (white arrow). These findings are diagnostic of central serous retinopathy.



**Figure 5.** Fundus photo shows multiple blot hemorrhages (green arrow), exudates (yellow arrow), tortuous and dilated veins (blue arrow), and optic disc edema (white arrow). These findings are diagnostic of central retinal vein occlusion.

### Dry Eye Syndrome

The low humidity at the high-altitude results in increased tear film evaporation, resulting in increased tear film osmolarity and eventually dry eye disease. The harsh environmental factors like severe cold weather and wind chill factor can also lead to reduced tear film stability and increased tear

break-up. The previous studies have reported a prevalence of dry eye symptoms in 52.4–54% at extreme high altitude (33,34). Our study has also found a significant increase in dry eye syndrome at moderate high altitude.

### Effect of UV Radiation

The sunrays at high altitude are rich in UV radiation, which has short-term and long-term effects on the eyes. These effects partially depend on natural defenses (brow ridge, eyelashes, eyebrows, constriction of pupil, and the squinting of the eye) and artificial protection (hats and sunglasses). The short-term effects are photoconjunctivitis and photophthalmia. The photoconjunctivitis manifests as watering from the eyes with conjunctival congestion and is usually short-lived. Photophthalmia is a more severe condition that occurs 6–8 h after exposure in the form of pain, foreign body sensation, and photophobia. This is also a self-limited condition. We did not encounter either of these condition in our study participants.

The long-term effects include the formation of pterygium, climactic droplet keratopathy, and permanent endothelial morphological changes. Some studies show an increased risk of cortical cataract formation at high altitude (14). However, other trials refute this correlation (35).

### Visual Functions at High Altitude

There is no significant decrease in visual acuity and color perception in high-altitude regions (36,37). However, in a small study group, there was a reduction in the amplitude of convergence with preserved amplitude of accommodation on the ascent to high altitude. We did not study the effects of contact lens use in high altitudes due to the absence of their use in our study population.

### Conclusion

We found an increased incidence of dry eye syndrome at moderate high altitude. However, the moderate high altitude had no significant ocular effect on visual acuity, IOP, or central corneal thickness. We also found four cases of CSR and one case of CRVO in our study population. Due to the small sample size, the authors do not imply that exposure to high altitude resulted in CSR, and this association requires further evaluation. We also acknowledge that we could not establish a temporal correlation between the time spent in high-altitude region and the frequency of ophthalmic complications.

This is the first study on this subject at a moderate high altitude, and further studies are required to consolidate the present study's findings. Our study can act as a guideline for health advisories for deploying Armed Forces of various countries to moderate high altitude. This would also assist in planning long tourist expeditions in the hilly regions. In

addition, we also recommend that any symptoms of CSR or CRVO, like diminution of vision, blurring of vision, or central visual field defects, should be promptly evaluated by an ophthalmologist. There is a vast lacuna in the literature on this particular altitude range, and further studies are required to confirm our findings. It is also recommended that lubricant eye drops be advised as a standard prophylactic measure for all individuals traveling and staying at moderate high altitude.

#### Disclosures

**Ethics Committee Approval:** The present study was approved by the ethical board of the hospital in which the study was performed. This study complied with the latest version of the Helsinki Declaration of 1964.

**Peer-review:** Externally peer-reviewed.

**Conflict of Interest:** None declared.

**Authorship Contributions:** Concept – V.M.; Design – V.M.; Supervision – S.K.K.; Resource – S.K.K.; Materials – V.M., R.C.; Data Collection and/or Processing – S.M.; Analysis and/or Interpretation – V.M., S.M.; Literature Search – V.M., R.C.; Writing – S.K.K.; Critical Reviews – V.M., S.M.

#### References

- West J, Schoene R, Luks A, Milledge J. High Altitude Medicine and Physiology. 5th ed. United States: CRC Press; 2012. [CrossRef]
- Morris DS, Somner J, Donald MJ, McCormick IJ, Bourne RR, Huang SS, et al. The eye at altitude. Hypoxia and Exercise. Berlin: Springer; 2006. p. 249–70. [CrossRef]
- Carapanea M. Experimental and clinical hyperophthalmotony of high altitudes. Arch Ophthalmol (Paris) 1977;37:775–84.
- Bayer A, Yumuşak E, Şahin ÖF, Uysal Y. Intraocular pressure measured at ground level and 10,000 feet. Aviat Space Environ Med 2004;75:543–5.
- Clarke C, Duff J. Mountain sickness, retinal haemorrhages, and acclimatisation on Mount Everest in 1975. Br Med J 1976;2:495–7.
- Brinchmann-Hansen O, Myhre K. Blood pressure, intraocular pressure, and retinal vessels after high altitude mountain exposure. Aviat Space Environ Med 1989;60:970–6.
- Cymerman A, Rock PB, Muza SR, Lyons TP, Fulco CS, Mazzeo RS, et al. Intraocular pressure and acclimatization to 4300 M altitude. Aviat Space Environ Med 2000;71:1045–50.
- Hackett PH, Rennie D. Rales, peripheral edema, retinal hemorrhage and acute mountain sickness. Am J Med 1979;67:214–8.
- Wiedman M, Tabin GC. High-altitude retinopathy and altitude illness. Ophthalmology 1999;106:1924–7. [CrossRef]
- Jha KN. High altitude and the eye. Asia Pac J Ophthalmol 2012;1:166–9. [CrossRef]
- Bärtsch P, Saltin B, Dvorak J. Consensus statement on playing football at different altitude. Scand J Med Sci Sports 2008;18:96–9.
- Wilmer WH, Berens CV. The effect of altitude on ocular functions. J Am Med Assoc 1918;71:1394–8. [CrossRef]
- Sinex JA, Chapman RF. Hypoxic training methods for improving endurance exercise performance. J Sport Health Sci 2015;4:325–32. [CrossRef]
- Hu T-S, Zhen Q, Sperduto RD, Zhao JL, Milton RC, Nakajima A. Age-related cataract in the Tibet Eye Study. Arch Ophthalmol 1989;107:666–9. [CrossRef]
- Bowling B. Kanski's Clinical Ophthalmology. Scotland: Elsevier Edinburgh; 2016.
- Somner JE, Morris DS, Scott KM, MacCormick IJ, Aspinall P, Dhillon B. What happens to intraocular pressure at high altitude? Invest Ophthalmol Vis Sci 2007;48:1622–6. [CrossRef]
- Polse KA, Mandell RB. Critical oxygen tension at the corneal surface. Arch Ophthalmol 1970;84:505–8. [CrossRef]
- du Toit R, Vega JA, Fonn D, Simpson T. Diurnal variation of corneal sensitivity and thickness. Cornea 2003;22:205–9. [CrossRef]
- Morris DS, Somner JE, Scott KM, McCormick IJ, Aspinall P, Dhillon B. Corneal thickness at high altitude. Cornea 2007;26:308–11. [CrossRef]
- Wilmer W, Berens C Jr. Medical studies in aviation: V. The effect of altitude on ocular functions. 1918. Aviat Space Environ Med 1989;60:1018–23.
- Singh I, Khanna P, Srivastava M, Lal M, Roy SB, Subramanyam C. Acute mountain sickness. N Engl J Med 1969;280:175–84.
- Honigman B, Noordewier E, Kleinman D, Yaron M. Case report: High altitude retinal hemorrhages in a colorado skier. High Alt Med Biol 2001;2:539–44. [CrossRef]
- Tingay D, Tsimnadis P, Basnyat B. A blurred view from Everest. Lancet 2003;362:1978. [CrossRef]
- Wiedman M. High altitude retinal hemorrhage. Arch Ophthalmol 1975;93:401–3. [CrossRef]
- Brinchmann-Hansen O, Myhre K. Vascular response of retinal arteries and veins to acute hypoxia of 8,000, 10,000, 12,500, and 15,000 feet of simulated altitude. Aviat Space Environ Med 1990;61:112–6.
- Frayser R, Houston CS, Bryan AC, Rennie ID, Gray G. Retinal hemorrhage at high altitude. N Engl J Med 1970;282:1183–4.
- Müllner-Eidenböck A, Rainer G, Strenn K, Zidek T. High-altitude retinopathy and retinal vascular dysregulation. Eye (Lond) 2000;14:724–9. [CrossRef]
- Shults WT, Swan KC. High altitude retinopathy in mountain climbers. Arch Ophthalmol 1975;93:404–8. [CrossRef]
- Kramár PO, Drinkwater BL, Folinsbee LJ, Bedi JF. Ocular functions and incidence of acute mountain sickness in women at altitude. Aviat Space Environ Med 1983;54:116–20.
- Houston C, Mcfadden M. Long-term effects of altitude on the eye. Lancet 1979;314:49. [CrossRef]
- Gupta A, Singh S, Ahluwalia TS, Khanna A. Retinal vein occlusion in high altitude. High Alt Med Biol 2011;12:393–7. [CrossRef]
- Ide WW. Central serous chorioretinopathy following hypobaric chamber exposure. Aviat Space Environ Med 2014;85:1053–5.
- Lu P, Chen X, Liu X, Yu L, Kang Y, Xie Q, et al. Dry eye syn-

- 
- drome in elderly Tibetans at high altitude: A population-based study in China. *Cornea* 2008;27:545–51. [\[CrossRef\]](#)
34. Jha K. Tear break-up time in high altitude areas. *Med J Armed Forces India* 2009;65:2–3. [\[CrossRef\]](#)
35. Brilliant LB, Grasset NC, Pokhrel RP, Kolstad A, Lepkowski JM, Brilliant GE, et al. Associations among cataract prevalence, sunlight hours, and altitude in the Himalayas. *Am J Epidemiol* 1983;118:250–64. [\[CrossRef\]](#)
36. Miller R, Tredici T. Night Vision Manual for the Flight Surgeon. USAF Special Report AL-SR-1992-0002; 2013.
37. Leid J, Campagne JM. Colour vision at very high altitude. *Color Res Appl* 2001;26:S281–3. [\[CrossRef\]](#)