



Visual Outcomes, Endothelial Loss, and Complications Following Iris-Claw Intraocular Lens Implantation and Trocar-Assisted Sutureless Scleral Fixation of Intraocular Lenses

Ebubekir Durmus,¹ Veysel Aykut,¹ Mustafa Hepokur,² Fatma Sali,¹ Huseyin Avni Sanisoglu,³ Halit Oguz,¹ Fehim Esen¹

¹Department of Ophthalmology, Istanbul Medeniyet University, Istanbul, Türkiye

²Department of Ophthalmology, Goztepe Prof. Dr. Suleyman Yalçin City Hospital, Istanbul, Türkiye

³Department of Ophthalmology, Kadikoy Diabetes Hospital, Istanbul, Türkiye

Abstract

Objectives: Iris-claw intraocular lens (IC-IOL) implantation and sutureless scleral fixation of intraocular lenses (SSF-IOL) are two commonly preferred surgical approaches for the management of aphakic patients without sufficient capsular support. The aim of this study was to compare the outcomes of IC-IOL implantation and trocar-assisted SSF-IOL implantation.

Methods: The medical records of secondary IOL implantation patients were retrospectively reviewed. All patients had a detailed ophthalmological examination, including LogMAR best-corrected distance visual acuity (CDVA), intraocular pressure (IOP), and endothelial cell density (ECD) preoperatively and postoperatively. SPSS 21.0 software was used for the statistical analysis.

Results: There were 15 patients in the IC-IOL group and 12 patients in the SSF-IOL group. Age and gender distributions were similar between the groups ($p=0.456$ and $p=0.398$, respectively). Similarly, patients in both groups had similar CDVA preoperatively and postoperatively ($p=0.51$, $p=0.48$, respectively). Both IC-IOL and SSF-IOL implantation significantly increased CDVA ($p=0.001$ and $p=0.005$, respectively). IOP remained unchanged in both groups. However, ECD reduced significantly following both IC-IOL and SSF-IOL implantation ($p=0.001$ and $p=0.005$, respectively) and trocar-assisted SSF-IOL implantation resulted in significantly more endothelial loss compared to IC-IOL implantation (439.5 ± 89 vs. 164.4 ± 53 , $p=0.013$).

Conclusion: Both surgical approaches increased CDVA significantly and at similar levels. However, trocar-assisted SSF-IOL implantation resulted in significantly more endothelial loss compared to IC-IOL implantation. None of the patients developed bullous keratopathy, but this difference should be kept in mind, especially in patients with critically low ECD.

Keywords: Endothelial loss, implantation, iris-claw intraocular lens, secondary intraocular lens, sutureless scleral fixation.

How to cite this article: Durmus E, Aykut V, Hepokur M, Sali F, Sanisoglu HA, Oguz H, et al. Visual Outcomes, Endothelial Loss, and Complications Following Iris-Claw Intraocular Lens Implantation and Trocar-Assisted Sutureless Scleral Fixation of Intraocular Lenses. *Beyoglu Eye J* 2023; 8(4): 253-259.

Address for correspondence: Ebubekir Durmus, MD. Department of Ophthalmology, Istanbul Medeniyet University, Istanbul, Türkiye
Phone: +90 505 786 65 57 **E-mail:** dredurmus@hotmail.com

Submitted Date: March 11, 2023 **Revised Date:** July 19, 2023 **Accepted Date:** September 02, 2023 **Available Online Date:** December 01, 2023

Beyoglu Eye Training and Research Hospital - Available online at www.beyoglueye.com

OPEN ACCESS This is an open access article under the CC BY-NC license (<http://creativecommons.org/licenses/by-nc/4.0/>).



Introduction

Management of aphakic patients without sufficient capsular support is a relatively complex problem and intraocular lens (IOL) implantation is a challenge in these eyes. Various surgical approaches were developed to address this problem, and each technique has certain advantages over the other alternatives. These alternatives include implantation of angle-supported anterior chamber IOLs, pre-pupillary or retropupillary implantation of iris-claw IOLs, and scleral fixation of IOLs (1). Angle-supported anterior chamber IOLs are a relatively simpler surgical approach and have the highest complication rate compared to the other alternatives. Complications such as chronic endothelial loss, bullous keratopathy, and uveitis glaucoma hyphema syndrome are relatively common following the implantation of these lenses (2). Although more modern designs were developed to avoid these problems, chronic endothelial loss remains a significant problem following angle-supported anterior chamber IOL implantation (3). Therefore, these lenses are no longer preferred by many ophthalmologists. Iris-claw IOLs can be implanted both in anterior and posterior chambers, and both approaches deliver similarly good results (4). Implantation of these lenses requires an intact iris stroma and the absence of chronic ocular inflammatory conditions, such as uveitis (5). These contraindications are encountered in a very small number of patients, and these lenses remain a good alternative for most aphakic patients with insufficient capsular support.

Scleral fixation of IOLs is the most preferred surgical approach in these patients because of the relatively easy access to the wide variety of IOLs that can be fixated to the sclera. Besides, scleral fixation of IOLs results in an IOL position that is closer place to the physiological location of the crystalline lens and nodal point of the eye compared to anterior chamber IOLs (6). Scleral fixation of IOLs can be performed in many ways including suture scleral fixation of IOLs, glued scleral fixation of 3-piece foldable IOLs, sutureless scleral fixation (SSF) of 3-piece foldable IOLs, scleral fixation of IOLs with eyelets using flanged 5/0 Prolene sutures and SSF of special design 1-piece foldable IOLs (7,8). Suture scleral fixation of IOLs has certain limitations related to the structural problems of 10/0 polypropylene sutures that tend to erode over time and require repeated surgeries (9). SSF of the IOLs was developed to overcome suture-related long-term complications (10). Trocar-assisted SSF and Yamane techniques allow transconjunctival SSF of 3-piece IOLs (11,12). Transconjunctival SSF techniques are relatively new and practical approaches that are increasingly preferred by many surgeons, due to their relatively simple, less time-consuming nature (13). These surgeries can be performed using simple surgical tools and IOLs that are widely available in many centers.

This study aimed to compare the clinical outcome of a modern scleral fixation procedure (trocar-assisted SSF of IOLs) with a long-standing, practical surgical approach (iris-claw IOL implantation). Visual outcomes, complications, and endothelial loss following these procedures were compared in this study.

Methods

This study had a mixed cohort design. Medical records of 42 patients who had a secondary IOL implantation were retrospectively reviewed. All patients were invited for a final examination. Patients with other ocular pathologies that reduce visual acuity, including corneal pathologies (such as corneal scarring or bullous keratopathy), chronic retinal pathologies (such as diabetic retinopathy, age-related macular degeneration, macular scarring), and chronic uveitis were excluded. All patients (n=27) had at least 6 months of follow-up. The study protocol was approved by the institutional ethics review committee (Ethics review committee of Istanbul Medeniyet University Göztepe Training and Research Hospital, document no: 2021/0219) and written informed consent was obtained from all participants. The study protocol adhered to the tenets of the Declaration of Helsinki.

All of the invited patients had a detailed ophthalmological examination, including determination of corrected distance visual acuity (CDVA) with a Snellen chart, slit-lamp examination, indirect ophthalmoscopy, intraocular pressure measurement with pneumotometry (Topcon CT-IP computerized tonometer, Tokyo, Japan), and specular microscopy (Tomey EM4000, Tomey Corp, Japan) were recorded. These examination findings were also retrospectively collected for the pre-operative examination from the medical records of the patient. The cause of aphakia, intraoperative complications, and post-operative complications (such as broken haptics, IOL tilt, cystoid macular edema (CME), uveitis, and transient corneal edema) were specifically recorded. All patients had only anterior vitrectomy either during primary surgery or secondary IOL implantation. Corneal sutures (if present) were removed before the 6th month examination in all cases. All cases used similar topical treatments (antibiotics and steroid drops, 8 times a day in the 1st post-operative week followed by 4 times a day for 1 month) in the post-operative period.

Surgical Technique for Iris-claw Implantation

Two side port incisions were opened using a 20 MVR at 2 and 10 o'clock positions and a 6 mm clear corneal incision was performed using a 2.8 mm slit knife. Anterior vitrectomy was performed (if needed) and intracameral carbachol 0.01% (Miostat®; Alcon Laboratories, Inc., Fort Worth, TX, USA) was injected for pupillary miosis. The anterior chamber

was filled with a dispersive ophthalmic viscosurgical device (OVD) (Crowntisc® 3.0%, Miray Medikal, Bursa, Türkiye). A PMMA iris-claw IOL (Artisan® Aphakia model 205, Ophtec BV, Groningen, The Netherlands) was placed in the anterior chamber and rotated using a Sinsky hook to place its haptics at 3 and 9 o'clock positions. The IOL was stabilized by holding the optic with forceps, and the mid-peripheral iris tissue was tucked into the haptics using an enclavation needle. The clear corneal incision was sutured with a 10/0 monofilament nylon suture (Ethilon®, Johnson and Johnson Medical Ltd, Livingston, UK). We did not perform peripheral iridectomy in any of the cases as these patients were aphakic and had already had peripheral iridectomy. Intracameral antibiotic and subconjunctival steroid injections were performed at the end of the surgery.

Surgical Technique of Trocar-Assisted SSF

A 25G vitrectomy trocars were inserted into the sclera 2 mm away from the limbus, moved 3 mm parallel to the limbus, and inserted straight into the vitreous cavity perpendicular to the limbus. An anterior chamber maintainer was placed inferotemporal. Anterior vitrectomy was performed in case of remnant vitreous. A 2.8 mm clear corneal incision was performed and a 3-piece hydrophobic acrylic IOL (Alcon Acrisoft MA60AC; Alcon Laboratories, Fort Worth, Texas, USA) was injected into the anterior chamber. The leading haptic of the IOL was grasped using a vitreoretinal forceps and was transferred to the second vitreoretinal forceps that was inserted through the trocar at 3 o'clock position. The haptic was externalized simultaneously with the second vitreoretinal forceps and trocar. The tip of the haptic was flanged using a low-temperature cautery. This process was

repeated for the second haptic. Centralization of the IOL optic was achieved. A temporary safety suture was placed at the center of the scleral tunnel to surround and squeeze the scleral tunnel to prevent the movement of the IOL haptic inside the tunnel. Corneal incisions were closed with stromal hydration, and the surgery was completed with intracameral antibiotic and subconjunctival steroid injections.

Statistical Analysis

Statistical analysis was performed using SPSS 21 software (IBM Corp, Chicago, IL, USA). The distribution of the data was determined using the Shapiro–Wilk test. The data were presented as mean±SEM and median (interquartile range). Snellen visual acuities were converted to LogMAR before statistical analysis. Mann–Whitney U test was used for intergroup comparisons, and Wilcoxon test was used for repeated samples. $P < 0.05$ were accepted as statistically significant.

Results

Ocular comorbidities were quite common among secondary IOL implantation patients and only 27 cases (out of 42) qualified for the above-mentioned inclusion criteria. Fifteen patients had iris-claw IOL implantation (12 male, 3 female, median age: 69.0 years) and 12 patients had trocar-assisted SSF IOL implantation (7 male, 5 female, median age: 67.5 years). Age and gender distributions were similar between the groups ($p=0.456$ and $p=0.398$, respectively). Median follow-up time was longer in the SSF group compared to the iris-claw group (17.5 vs. 6 months, $p=0.014$). The most common indication for these surgeries was a previously complicated cataract surgery. The details of the demographic and clinical characteristics of the patients are given in Table 1.

Table 1. Demographic and clinical characteristics of the patients

	IC- IOL group (n=15)	SSF-IOL group (n=12)	p
Male	12	7	0.398*
Female	3	5	
Mean age, years±SD	67.0±17.5	61.2±19.8	0.456**
Follow up time, months±SD	8.0±2.9	15.4±6.8	0.014**
Etiology			
Surgical aphakia	7	11	
Nucleus drop	2		
IOL drop	2		
Lens subluxation	1		
IOL dislocation	2	1	
Trauma	1		

IC-IOL: iris-claw intraocular lens implantation; SSF-IOL: trocar-assisted sutureless scleral intraocular lens fixation; SD: standard deviation; *: Fisher Exact test; **: Mann Whitney U test.

Pre-operative CDVA was similar between the IC-IOL and SSF-IOL groups (1.64 ± 0.19 vs. 1.67 ± 0.30 , $p=0.51$). CDVA improved significantly at the post-operative 6th month in both IC-IOL and SSF-IOL groups ($p=0.001$ and $p=0.005$, respectively, Figures 1a and b). Post-operative CDVA was 0.38 ± 0.14 in the IC-IOL group and 0.35 ± 0.05 SSF-IOL group. There was also no significant difference between the post-operative CDVA results of the groups ($p=0.48$, Figures 1c and d). There was no significant change in intraocular pressure (IOP) in both IC-IOL (18.2 ± 1.3 vs. 16.7 ± 0.9 mmHg, $p=0.27$) and SSF-IOL groups (16.5 ± 2.2 mmHg vs. 16.3 ± 1.4 mmHg, $p=0.85$).

Endothelial cell loss is an important outcome for secondary IOL implantation surgeries because most of these surgeries are performed on patients who have a history of ocular trauma or complicated surgery and an already compromised endothelium. Endothelial cell counts declined postoperatively both in IC-IOL implantation (1875.6 ± 79.5

vs. $1711. \pm 57$, $p=0.001$, Fig. 2a) and SSF-IOL implantation (2199.5 ± 174.5 vs. 1760 ± 160.8 , $p=0.005$, Fig. 2b) groups. The mean endothelial cell loss was significantly lower in the IC-IOL group compared to the SSF-IOL group (164.4 ± 53.0 vs. 439.5 ± 89.0 , $p=0.013$, Fig. 2c). No serious intraoperative complications (such as corneal injury, IOL drop, and expulsive suprachoroidal hemorrhage) were observed in both groups. However, IOL haptic was broken in two cases in the SSF-IOL implantation group, and IOL exchange was performed in these cases without further complications. We did not observe post-operative IOL dislocation or tilt in both groups. A small iridodialysis developed in a case in the IC-IOL group, but it did not require further intervention since it was very small to cause any visual disturbance.

The most common post-operative complications included transient IOP elevation ($n=2$) and transient hypotony ($n=1$) in the SSF-IOL group. These transient changes could be managed medically and resolved without

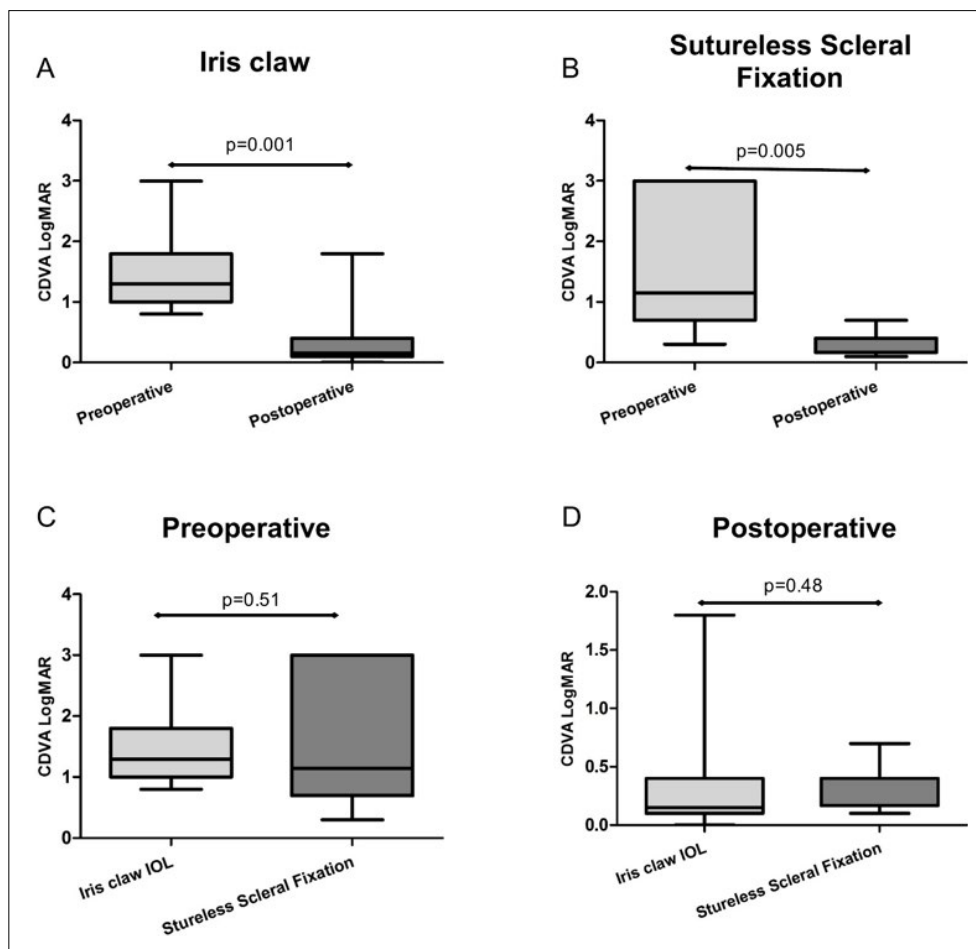


Figure 1. Pre-operative versus post-operative corrected distance visual acuity in the groups. Corrected distance visual acuity (CDVA) improved significantly both in iris-claw intraocular lens (IOL) implantation (a) and sutureless scleral fixation (SSF) of intraocular lenses (b). There was no significant difference between iris-claw IOL implantation and SSF groups for pre-operative CDVA (c) and CDVA at the post-operative 6th month (d).

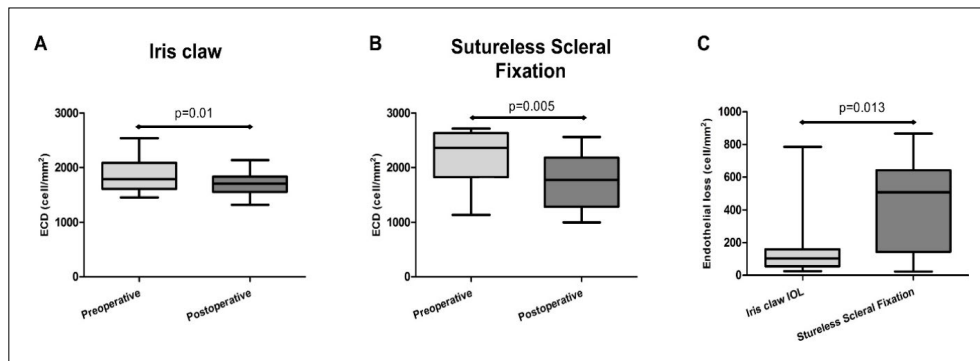


Figure 2. Endothelial loss in the groups. Endothelial cell counts decreased significantly following both iris-claw intraocular lens (IOL) implantation (a) and sutureless scleral fixation (SSF) of intraocular lenses (b). The endothelial loss was significantly more in the SSF group compared to iris-claw IOL implantation groups at the post-operative 6th month (c).

requiring further intervention. IOL dislocation developed during post-operative follow-up in a case following IC-IOL implantation, and IOL was surgically repositioned. CME developed in four cases (two cases in the IC-IOL group and two cases in the SSF-IOL group). Posterior sub-Tenon's injection of triamcinolone acetonide was performed in these cases and CME recovered in all four cases without requiring further intervention.

Discussion

SSF of the intraocular lenses was first described by Gabor and Pavlidis and this surgery became a very good alternative for suture scleral fixation of IOLs (14). This initial technique was rather complicated, and other alternatives to this technique were developed to simplify this surgical approach. Transconjunctival trocar-assisted SSF and Yamane techniques reduced surgical time and increased surgical comfort in these cases (15). Iris-claw IOLs are also a good alternative for the management of aphakic patients with insufficient capsular support. These lenses require an intact iris stroma and are contraindicated in patients with iris pathologies (including uveitis).

The primary outcome measure is the improvement of visual acuity in most of the secondary IOL implantation studies. Studies both with iris-claw IOLs and trocar-assisted SSF of IOLs reported a significant increase in CDVA following these surgeries (16). The current study confirmed previous observations, and CDVA significantly improved in both groups postoperatively. Both IOL implantation techniques delivered very good clinical results, and there was no statistically significant difference between the visual improvements with both techniques.

There was no change between the pre-operative and post-operative IOP values both in the SSF-IOL and IC-IOL groups in the long-term follow-up. However, transient IOP problems occurred only in the SSF-IOL group (3/12 patients).

Two patients had a transient rise in IOP probably due to retained OVD under the iris in the SSF-IOL group. We used 25G trocars during these surgeries and therefore scleral tunnels were relatively large in diameter. Aqueous humor could leak through this scleral tunnel in a case, probably because the safety suture could not sufficiently tighten the sclerotomy. Transient post-operative hypotony developed in this case, and it resolved spontaneously with the scleral wound healing response. Some authors prefer 27 G trocars for sclerotomies, but using smaller trocars can make surgical manipulations harder during haptic externalization (17).

Endothelial cell loss is a common complication of secondary IOL implantation surgeries and occurs, especially during the early post-operative period due to surgical trauma (18). This is especially important because these patients usually have a history of complicated cataract surgery and an already compromised endothelium (19). Primary causes of endothelial loss during the early post-operative period include extensive surgical manipulations that can physically damage endothelial cells, jet streams, and increase surgical time (18,20). Long-term endothelial loss occurs mostly due to chronic inflammation (18). Endothelial cell loss was significantly higher in the SSF-IOL group. We suspect that jet streams due to routine use of anterior chamber maintainer and excessive anterior segment manipulations in the SSF-IOL group might have increased endothelial loss in these cases. We also experienced that the maintainer deepens the anterior chamber, making manipulations difficult.

Post-operative IOL decentration or dislocation is an important complication of secondary IOL implantation surgeries. Post-operative IOL dislocation is reported in around 0–3% of iris-claw IOL implantation surgeries (4). The complete removal of the vitreous bands in the pupillary area, good centration, and firm enclavation of the IOL haptics to the mid-peripheral iris stroma are important to prevent IOL dislocation or IOL tilt following these surgeries (21). This

complication also occurs at a similar rate (0–12%) following trocar-assisted scleral fixation (22). Proper flanging of the IOL haptics and formation of symmetrical scleral tunnels are important to prevent IOL decentration or tilt. Many surgeons also use safety sutures to prevent dislocation of the IOL haptics inside the scleral tunnel to prevent IOL decentration and tilt in these cases (23). Another potential complication of SSF surgeries is the development of mild vitreous hemorrhage from the ciliary body or iris base (24). This complication especially occurs when the surgeon enters the vitreous cavity at a spot closer than 1.5–2.0 mm to the limbus and touches uveal tissue. In this study, all sclerotomies were formed 1.5–2.0 mm away from the limbus, and none of the patients developed vitreous hemorrhage.

Post-operative CME is a relatively common complication following secondary IOL implantation surgeries. It was reported around 0.8–7.7% of the iris-claw IOL implantation surgeries and 1.97–13.3% of SSF surgeries (25,26). The development of CME was also around these numbers in iris-claw IOL implantation (n=2, 7.6%) and SSF (n=2, 13.3%) groups in the current study. Posterior sub-Tenon's injection of triamcinolone acetonide was performed in all four cases and all patients responded well to this treatment and macular edema resolved successfully. Another rare complication was small asymptomatic iridodialysis in a patient during iris-claw IOL implantation, which did not require further intervention. IOL haptic broke in two cases during the haptic externalization step of SSF. A successful IOL exchange was performed in these cases, and the surgeries were completed without further complications.

This study has certain limitations worth mentioning. The retrospective component of the mixed cohort design was a limitation. We selected an aphakic patient population without other ocular conditions that can impair vision. Therefore, the number of the included patients was limited, and we could not perform detailed subgroup analyses. However, these numbers were still sufficient to demonstrate statistically significant differences between the groups. We also did a post hoc statistical power analysis using G-power software and the statistical power of the current study was above 0.95 to demonstrate significant endothelial loss. Corneal incision sites were not standardized, steep meridian was not chosen as an incision site in most of the cases. We believe that our data were not optimized to compare surgically induced astigmatism. IOL dislocation was quite rare in this study, and none of the patients developed haptic erosion. These are long-term complications of secondary IOL implantation that occur many years after the surgery (27–29). Therefore, this study was not suitable to compare the relatively rare, late complications of these surgeries.

Conclusion

Both secondary IOL implantation techniques delivered good optical results and improved CDVA significantly without any difference between the groups. However, there was significantly higher endothelial cell loss following the trocar-assisted SSF procedure, which might have been caused by the steeper learning curve of this technique or jet flows induced by the anterior chamber maintainer in this surgery. Therefore, specific care might be required in patients with low pre-operative endothelial cell counts.

Disclosures

Ethics Committee Approval: The study protocol was approved by the institutional ethics review committee (Ethics review committee of Istanbul Medeniyet University Göztepe Training and Research Hospital, document no: 2021/0219) and written informed consent was obtained from all participants. The study protocol adhered to the tenets of the Declaration of Helsinki.

Peer-review: Externally peer-reviewed.

Conflict of Interest: None declared.

Authorship Contributions: Concept – E.D., F.E., F.S.; Design – E.D., F.E., H.O.; Supervision – E.D., H.O.; Data collection and/or processing – M.H., F.S., V.A.; Analysis and/or interpretation – F.E., M.H.; Literature search – E.D., V.A., F.S.; Writing – E.D., F.E., V.A.; Critical reviews – H.O., V.A., M.H.

References

1. Vounotrypidis E, Schuster I, Mackert MJ, Kook D, Priglinger S, Wolf A. Secondary intraocular lens implantation: A large retrospective analysis. *Graefes Arch Clin Exp Ophthalmol* 2019;257:125–34. [CrossRef]
2. Walia S, Kashyap S, Bhaisare V, Rawat P, Kori N. Novel technique of sutureless glueless scleral fixated intraocular lens (SFIOL). *Indian J Ophthalmol* 2019;67:64–8. [CrossRef]
3. Tang Y, Xu J, Chen J, Lu Y. Long-term destiny of corneal endothelial cells in anterior chamber intraocular lens-implanted eyes. *J Ophthalmol* 2020;2020:5967509. [CrossRef]
4. Touriño Peralba R, Lamas-Francis D, Sarandeses-Diez T, Martínez-Pérez L, Rodríguez-Ares T. Iris-claw intraocular lens for aphakia: Can location influence the final outcomes? *J Cataract Refract Surg* 2018;44:818–26. [CrossRef]
5. Acar N, Kapran Z, Altan T, Kucuksumer Y, Unver YB, Polat E. Secondary iris claw intraocular lens implantation for the correction of aphakia after pars plana vitrectomy. *Retina* 2010;30:131–9. [CrossRef]
6. Veronese C, Maiolo C, Armstrong GW, Primavera L, Torrazza C, Della Mora L, et al. New surgical approach for sutureless scleral fixation. *Eur J Ophthalmol* 2020;30:612–5. [CrossRef]
7. Barca F, Caporossi T, de Angelis L, Giansanti F, Savastano A, Di Leo L, et al. Trans-scleral plugs fixated IOL: A new paradigm for sutureless scleral fixation. *J Cataract Refract Surg* 2020;46:716–20. [CrossRef]

8. Canabrava S, Canedo Domingos Lima AC, Arancibia AE, Bicalho Dornelas LF, Ribeiro G. Novel double-flanged technique for managing Marfan syndrome and microspherophakia. *J Cataract Refract Surg* 2020;46:333–9. [\[CrossRef\]](#)
9. Vote BJ, Tranos P, Bunce C, Charteris DG, Da Cruz L. Long-term outcome of combined pars plana vitrectomy and scleral fixated sutured posterior chamber intraocular lens implantation. *Am J Ophthalmol* 2006;141:308–12. [\[CrossRef\]](#)
10. Nb K, Kohli P, Pangtey BPS, Ramasamy K. Evaluation of sutureless, glueless, flapless, intrascleral fixated posterior chamber intraocular lens in children with ectopia lentis. *J Ophthalmol* 2018;2018:3212740. [\[CrossRef\]](#)
11. Totan Y, Karadag R. Trocar-assisted sutureless intrascleral posterior chamber foldable intra-ocular lens fixation. *Eye (Lond)* 2012;26:788–91. [\[CrossRef\]](#)
12. Yamane S, Sato S, Maruyama-Inoue M, Kadonosono K. Flanged intrascleral intraocular lens fixation with double-needle technique. *Ophthalmology* 2017;124:1136–42. [\[CrossRef\]](#)
13. Yamane S, Ito A. Flanged fixation: Yamane technique and its application. *Curr Opin Ophthalmol* 2021;32:19–24. [\[CrossRef\]](#)
14. Gabor SG, Pavlidis MM. Sutureless intrascleral posterior chamber intraocular lens fixation. *J Cataract Refract Surg* 2007;33:1851–4. [\[CrossRef\]](#)
15. Jacob S, Kumar DA, Rao NK. Scleral fixation of intraocular lenses. *Curr Opin Ophthalmol* 2020;31:50–60. [\[CrossRef\]](#)
16. Shuaib AM, El Sayed Y, Kamal A, El Sanabary Z, Elhilali H. Transscleral sutureless intraocular lens versus retropupillary iris-claw lens fixation for paediatric aphakia without capsular support: A randomized study. *Acta Ophthalmol* 2019;97:e850–9.
17. Diamint DV, Giambriuni JM. 27-gauge trocar-assisted transconjunctival sutureless intraocular lens scleral fixation. *Eur J Ophthalmol* 2021;31:NP65–9. [\[CrossRef\]](#)
18. Güell JL, Velasco F, Malecaze F, Vázquez M, Gris O, Manero F. Secondary artisan-veryise aphakic lens implantation. *J Cataract Refract Surg* 2005;31:2266–71. [\[CrossRef\]](#)
19. Narang P, Agarwal A. Triple procedure for pseudophakic bullous keratopathy in complicated cataract surgery: Glued IOL with single-pass four-throw pupilloplasty with pre-Descemet's endothelial keratoplasty. *J Cataract Refract Surg* 2019;45:398–403.
20. Hepokur M, Kizilay EB, Durmus E, Aykut V, Esen F, Oguz H. The influence of corneal incision size on endothelial cell loss and surgically induced astigmatism following phacoemulsification cataract surgery. *North Clin Istanb* 2022;9:385–90. [\[CrossRef\]](#)
21. Gonnermann J, Torun N, Klamann MK, Maier AK, von Sonneithner C, Rieck PW, et al. Posterior iris-claw aphakic intraocular lens implantation in children. *Am J Ophthalmol* 2013;156:382–6.e1. [\[CrossRef\]](#)
22. Czajka MP, Frajdenberg A, Stopa M, Pabin T, Johansson B, Jakobsson G. Sutureless intrascleral fixation using different three-piece posterior chamber intraocular lenses: A literature review of surgical techniques in cases of insufficient capsular support and a retrospective multicentre study. *Acta Ophthalmol* 2020;98:224–36. [\[CrossRef\]](#)
23. Aykut V, Esen F, Sali F, Oguz H. Refractive outcome of trocar-assisted sutureless scleral fixation with 3-piece intraocular lenses. *Int Ophthalmol* 2021;41:2689–94. [\[CrossRef\]](#)
24. Jujo T, Kogo J, Sasaki H, Sekine R, Sato K, Ebisutani S, et al. 27-gauge trocar-assisted sutureless intraocular lens fixation. *BMC Ophthalmol* 2021;21:8. [\[CrossRef\]](#)
25. Bedda AM, ElGoweini HF, Abdelhadi AM, Elhady AM. Evaluation of suturless scleral fixation with posterior chamber foldable intraocular lens implantation. *Int J Ophthalmol* 2019;12:1283–9. [\[CrossRef\]](#)
26. De Silva SR, Arun K, Anandan M, Glover N, Patel CK, Rosen P. Iris-claw intraocular lenses to correct aphakia in the absence of capsule support. *J Cataract Refract Surg* 2011;37:1667–72.
27. Kansal V, Onasanya O, Colleaux K, Rawlings N. Outcomes of using sutureless, scleral-fixated posterior chamber intraocular lenses. *Semin Ophthalmol* 2019;34:488–96. [\[CrossRef\]](#)
28. Thulasidas M. Retropupillary iris-claw intraocular lenses: A literature review. *Clin Ophthalmol* 2021;15:2727–39. [\[CrossRef\]](#)
29. Stem MS, Wa CA, Todorich B, Woodward MA, Walsh MK, Wolfe JD. 27-gauge sutureless intrascleral fixation of intraocular lenses with haptic flanging: Short-term clinical outcomes and a disinsertion force study. *Retina* 2019;39:2149–54. [\[CrossRef\]](#)