



Choroidal Thickness in Emmetropia: An Enhanced Depth Imaging Spectral-Domain Optical Coherence Tomography-Based Study

Selim Cevher,¹ Mehmet Baris Ucer,² Tayfun Sahin¹

¹Department of Ophthalmology, Hitit University, Çorum, Turkey

²Department Of Ophtalmology, Hitit University Erol Olçok Research and Training Hospital, Çorum, Turkey

Abstract

Objectives: To investigate and determine the choroidal thickness (CT) in healthy emmetropic Turkish subjects aged between 20 and 40 years using Enhanced Depth Imaging Spectral-Domain Optical Coherence Tomography (EDI-OCT).

Methods: This study included 194 eyes of 194 healthy emmetropic subjects. All participants underwent a detailed ophthalmologic examination. Axial length (AL) was measured with optical biometry. CT measurements were performed at subfoveal, 1.0 mm temporal, and 1.0 mm nasal using the EDI-OCT. Central macular thickness (CMT) measurements were also performed at the same time. Participants were divided into two groups; Group 1 (age between 20 and 30 years) and Group 2 (age between 31 and 40 years). CT and CMT were compared among two groups.

Results: The mean age of all the subjects was 26.61±6.08 years, the mean AL was 23.44±0.72 mm, and the mean spherical equivalent was -0.11±0.28 Diopter. The mean subfoveal, nasal, and temporal CT was 389.27±86.61 µm, 354.54±86.86 µm, and 368.25±78.69 µm, respectively. Subfoveal and nasal CT of female participants were found thinner than male participants (p=0.013 and p=0.008, respectively). CT and CMT were found similar between Group 1 and Group 2.

Conclusion: This study showed that mean subfoveal CT and CMT was 389.27±86.61 µm and 268.17±18.76 µm, respectively, among healthy emmetropic Turkish subjects. Females had thinner CT in subfoveal and nasal quadrants. In addition, age did not affect CT between 20 and 40 years.

Keywords: Axial length, choroidal thickness, emmetropia, enhanced-depth imaging optical coherence tomography, ethnicity, healthy subjects

Introduction

The choroid, the highest vascularized structure in the human body, plays an important role in the eye's normal functions, such as thermoregulation, carrying oxygen, nutrients to the outer layer of the retina, removing waste products, and emmetropization. The retinal pigment epithelium and

photoreceptor layer do not have a vascular structure and the only source of oxygen and nourishment of these structures is the choroid. Choroidal dysfunction and losing of the vascular structure often result in photoreceptor damage and visual impairment (1). Therefore, investigating the choroidal structure and thickness has become more important.

How to cite this article: Cevher S, Ucer MB, Sahin T. Choroidal Thickness in Emmetropia: An Enhanced Depth Imaging Spectral-Domain Optical Coherence Tomography-Based Study. *Beyoglu Eye J* 2022; 7(2): 115-120.

Address for correspondence: Selim Cevher, MD. Oftalmoloji Anabilim Dalı, Hitit Üniversitesi, Çorum, Turkey

Phone: +90 555 814 77 90 **E-mail:** s.cevher@hotmail.com

Submitted Date: October 10, 2021 **Accepted Date:** April 09, 2022 **Available Online Date:** May 27, 2022

©Copyright 2022 by Beyoglu Eye Training and Research Hospital - Available online at www.beyoglu-eye.com

OPEN ACCESS This work is licensed under a Creative Commons Attribution-NonCommercial-ShareAlike 4.0 International License.



The imaging technologies in ophthalmology have been developing in recent years. Enhanced depth imaging optical coherence tomography (EDI-OCT) that shows the choroid, gives information to the ophthalmologist about many details of the structure of the choroid, and choroidal abnormalities underlying various chorioretinal diseases such as central serous chorioretinopathy, (2) age-related macular degeneration, (3) polypoidal choroidal vasculopathy, (4) Vogt-Koyanagi-Harada disease, (5) and high myopia related chorioretinopathy (6). The most frequently investigated topic in these diseases is choroidal thickness (CT) which can be a parameter for some pathologies in the near future. To understand the alternation of the choroid in pathologies, the normal choroidal structure and baseline thickness of the choroid must be known. We studied the subfoveal, 1000 μm nasal and 1000 μm temporal CT in healthy emmetropic Turkish subjects to determine their baseline CT.

In the literature, it was reported that CT may differ according to ethnicity. The mean CT in healthy subjects was investigated by researchers in different ethnic groups. For example, subfoveal CT was found $307 \pm 79 \mu\text{m}$ in Indian subjects, $253.8 \pm 107.4 \mu\text{m}$ in Chinese subjects, and $265.5 \pm 82.4 \mu\text{m}$ in Japanese subjects (7-9).

The main goal of this study was to contribute to the literature by reporting the mean CT values in healthy emmetropic Turkish subjects.

Methods

This is a prospective and cross-sectional study where healthy emmetropic subjects were enrolled during the routine ophthalmological examination. This study was conducted in accordance with the tenets of the Declaration of Helsinki. Possible consequences of the study were explained and all participants agreed to participate in the present study. A written informed consent form was obtained from each participant. Approval for the study was obtained from the Hitit University Faculty of Medicine ethics committee.

The study was performed in the Department of Ophthalmology and 194 right eyes of 194 healthy Turkish participants (age between 20 and 40 years old) were enrolled. All subjects were healthy volunteers with 10/10 best-corrected visual acuity (BCVA) according to the Snellen chart in both eyes.

The exclusion criteria were the following: 1) Refractive error (spherical equivalent [SE]) bigger than +0.50 D and -0.50 D, 2) axial length (AL) lower than 22 mm and bigger than 25 mm, 3) BCVA worse than 10/10, 4) intraocular pressure (IOP) >21 mmHg, 5) cup/disc ratio >0.3, 6) history of intraocular surgery, laser treatment, and trauma, presence or history of any intraocular diseases (including glaucoma, uveitis), 7) any situation which affects the measurement results such as poor OCT images due to cataract, corneal disorders, or unstable

fixation, 8) inability to comply with the OCT examination, 9) active ocular infection (conjunctivitis, keratitis), 10) using of any topical eye drops, 11) mental disability, 12) history of retinal diseases and retinal treatment, 13) systemic disorders such as hypertension or diabetes mellitus, cardiovascular disease, and respiratory disease, 14) history of COVID-19, and 15) systemic drug use, and history of smoking.

All subjects underwent a comprehensive ophthalmic examination including refraction and BCVA, slit-lamp biomicroscopy, IOP measured using Goldmann tonometry, and fundus examination. AL was measured with Nidek AL-Scan (Nidek CO, Aichi, Japan) optical biometer with three consecutive measurements. The mean of these three measurements was used as the AL measurement for each eye. To measure the refractive error, an auto refractor (TOPCON KR-8900; Topcon Corporation, Tokyo, Japan.) was used, and the SE was calculated. Spherical equivalent was defined as spherical + 1/2 cylindrical.

Enhanced Depth Imaging mode was used, a 6-mm horizontal single line scan, through the fovea between 10.00 and 12.00 in the morning (to avoid the diurnal variation of the CT) by a Heidelberg Spectralis® OCT (Heidelberg Engineering) (excitation wavelength = 840 nm, 40,000 A-scans/s, and 5 μm axial resolution. CT measurements were performed by measuring between the sclera and retinal pigment epithelium using a caliper system in the OCT device software manually. Measurements were taken at the subfoveal region, 1000 μm nasal to the fovea, and 1000 μm temporal to the fovea (Fig. 1). If eye movements during image acquisition were detected, measurements were excluded and retaken. Central macular thickness (CMT) measurement was also performed. CT measurements were performed manually by two masked and independent ophthalmologists (MBU, TŞ) to eliminate inter-observer variability. The mean value of the measurements was calculated. If more than 15% difference was detected between the two clinicians' reports, these measurements were excluded from the study.

Statistical Analysis

In this study, statistical analyses were done using SPSS (Version 22.0, SPSS Inc., Chicago, IL, USA) package program. The suitability of the groups to normal distribution was evaluated by Shapiro-Wilk's and Kolmogorov-Simonov analyzes. Continuous variables in normally distributed groups were represented as mean \pm standard deviation, while continuous variables not conforming to normal distribution were represented as median. In comparison of the groups, Student's t-test analysis was used for those who fit the normal distribution, while the Mann-Whitney U test analysis was used for those who did not fit the normal distribution. The statistical significance level was accepted as $p < 0.05$.

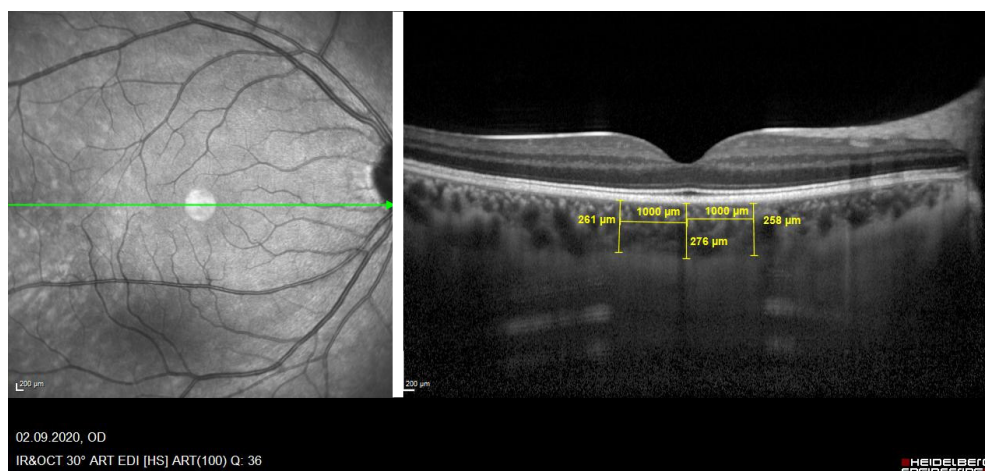


Figure 1. Enhanced depth imaging optical coherence tomography shows choroidal thicknesses.

Results

There were a total of 194 eyes of 194 healthy subjects in the study. Sixty-three (32.4%) of the subjects were female and 131 (67.5%) were male. The right eyes of 194 participants were included in the study. The mean age of female subjects was 27.53 ± 5.82 years (range 20–40 years), and the mean age of male subjects was 26.17 ± 6.18 years (range 20–40 years). The mean age of females and males was significantly different ($p=0.037$). The mean age of all subjects was 26.61 ± 6.08 years (range 20–40 years). The mean SE of females and males was -0.07 ± 0.27 D and -0.18 ± 0.27 D, respectively. Males were a little myopia than females ($p=0.007$). The mean AL in female participants was 23.16 ± 0.73 mm and the mean AL in male participants was 23.57 ± 0.68 mm. There was a statistical difference according to the AL values ($p<0.001$). In general, the mean AL was 23.44 ± 0.72 mm.

The mean CT in the subfoveal, nasal, and temporal quadrants in female participants was 370.31 ± 91.89 μm , 333.55 ± 88.96 μm , and 354.69 ± 80.79 μm , respectively. The mean CT in the subfoveal, nasal, and temporal quadrants in male participants was 398.39 ± 82.77 μm , 364.63 ± 84.62 μm , and 374.77 ± 77.12 μm , respectively. It was detected that females have thinner CT in subfoveal and nasal quadrants than males ($p=0.013$ and $p=0.008$, respectively). Temporal CT values were similar ($p=0.06$). In general, the mean CT in the subfoveal, nasal, and temporal quadrants was 389.27 ± 86.61 μm , 354.54 ± 86.86 μm , and 368.25 ± 78.69 μm , respectively. The mean CMT was 257.80 ± 19.13 μm in females, 273.16 ± 16.46 μm in males, and 268.17 ± 18.76 μm in general. Males have thicker CMT than females ($p<0.001$). Demographics of the study population are shown in Tables 1 and 2.

In addition, participants were divided into two groups according to age; participants age between 20 and 30 years was Group 1, age between 31 and 40 years was Group 2. There was not a statistically significant difference according

Table 1. The mean results of the parameters in the entire study population

Parameters	Entire Study Population (n=194) Mean \pm SD
Mean age, years	26.61 ± 6.08
Mean SE, diopter	-0.11 ± 0.28
Mean AL, mm	23.44 ± 0.72
Mean Subfoveal CT, μm	389.27 ± 86.61
Mean nasal I.0 CT, μm	354.54 ± 86.86
Mean temporal I.0 CT, μm	368.25 ± 78.69
Mean CMT, μm	268.17 ± 18.76

SE: Spherical equivalent; AL: Axial length; CT: Choroidal thickness; CMT: Central macular thickness.

to the subfoveal CT, nasal CT, temporal CT, and CMT between Group 1 and Group 2 ($p=0.087$, $p=0.222$, $p=0.103$, and $p=0.766$, respectively).

Discussion

In the present study, we measured the CT in healthy Turkish subjects and we wanted to determine the average CT values. We excluded the subjects under 20 years because in the pediatric population quality measurements cannot be performed most of the time due to adaptation problems and CT is not stable as this population is at the developmental stage. In addition, we excluded subjects over 40 years to minimize the effects of age on choroidal thinning. Age is likely to affect the CT at an older age. Ding et al. reported that this age-related thinning occurs in age older than 60 years of age (10). Thereby, we aimed to prioritize the effect of ethnicity on CT. In addition, we aimed to detect normative data of CT in the healthy population to interpret results in pathologic conditions.

Table 2. The mean results of the parameters in females and males

Parameters	Female Population (n=131)	Male Population (n=63)	p
Mean age, years	27.53±5.82	26.17±6.18	0.037
Mean SE, diopter	-0.07±0.27	-0.18±0.27	0.007
Mean AL, mm	23.16±0.73	23.57±0.68	<0.001
Mean Subfoveal CT, μm	370.31±91.89	398.39±82.77	0.013
Mean nasal 1.0 CT, μm	333.55±88.96	364.63±84.62	0.008
Mean temporal 1.0 CT, μm	354.69±80.79	374.77±77.12	0.06
Mean CMT, μm	257.80±19.13	273.16±16.46	<0.001

SE: Spherical equivalent; AL: Axial length; CT: Choroidal thickness; CMT: Central macular thickness.

This study shows the mean CT in the subfoveal, nasal, and temporal quadrants as $389.27 \pm 86.61 \mu\text{m}$, $354.54 \pm 86.86 \mu\text{m}$, and $368.25 \pm 78.69 \mu\text{m}$, respectively, in healthy emmetropic Turkish subjects age between 20 and 40 years.

In the literature, there are many studies examining the CT of individuals from different ethnicity. A study from China conducted by Wei et al. reported the mean subfoveal CT as $253.8 \pm 107.4 \mu\text{m}$ (8). Their study included 3468 participants aged between 50 and 93 years, SE between -20.0 D and -7.00 D and the mean AL was $23.2 \pm 1.11 \text{ mm}$ (range, $18.96\text{--}30.88 \text{ mm}$). Their study population was higher than our study. Another study from China, Ding et al. investigated the 210 healthy Chinese subjects with a mean age of 49.7 ± 17.9 years (ranging between 20 and 85 years) and they reported the mean subfoveal CT as $262 \pm 88 \mu\text{m}$ (10). Their participant's refractive error value was between $+6 \text{ D}$ and -6 D . When we compare our study with these two studies, our study's mean age was younger than these studies. Besides, the SE range and AL range of our study were narrower than these studies. In addition to the ethnic effect, the effects of age, AL, and SE on CT were more in these studies.

A study from Indian, Akhtar et al. reported the subfoveal CT as $307 \pm 79 \mu\text{m}$ in normal Indian subjects (7). The mean AL was $22.98 \pm 0.82 \text{ mm}$ (range, $20.50\text{--}25.29 \text{ mm}$). The mean refractive error was $0.00 \pm 1.25 \text{ D}$ and in this respect, it was similar to our study. However, the mean age of their study was 44.0 ± 29.0 years, ranging between 12 and 80 years. Their study population was older than our study population. Another study from India, Bhayana et al. reported the subfoveal CT as $299.10 \pm 131.2 \mu\text{m}$ (11). The study included 238 eyes of 119 healthy Indian subjects age between 19 and 60 years. The mean age was 28.70 ± 11.28 years, the mean AL was $23.63 \pm 1.96 \text{ mm}$, and the mean SE was $-0.91 \pm 3.08 \text{ D}$. This study was similar to our study in the respect of mean age, mean SE, and mean AL but different from our study in the respect of age ranging.

A study from Japan that was conducted by Fujiwara et al., reported that the mean subfoveal CT was $265.5 \pm 82.4 \mu\text{m}$ (9). They investigated 145 eyes of 145 healthy volunteers (range 5–88 years, mean age 45.7 years). This study included both the pediatric population and the elderly population, and we think that CT variation was high in this study. A study from Thailand, Jirattanasopa et al. reported the mean subfoveal CT as $279.4 \pm 75.49 \mu\text{m}$ (12). The mean age was 46.4 ± 16.45 years ranging between 23 and 83 years, the mean AL was $23.31 \pm 0.84 \text{ mm}$ (range, $21.63\text{--}26.10 \text{ mm}$), the mean SE was $-0.54 \pm 1.13 \text{ D}$ ranging -3.91 D to $+2.31 \text{ D}$. The ranges of SE, AL, and age of their study were wider than our study. A study from Iran, Entezari et al. found the subfoveal CT as $363 \pm 84 \mu\text{m}$ (13). The age of their study population was relatively similar to our study; the mean age was 34.6 ± 9.8 years (range, 18–57 years). In addition, their participants' refractive error was similar to our study, ± 1 diopter of refractive errors in either spherical or cylindrical refraction. However, the number of participants was lower than our study. In addition, information about AL in their study was absent. In another study from Iran, Heirani et al. investigated the CT in normal Iranian eyes, the age of the participants range from 4 to 60 years, and the study included myopic, hyperopic, and emmetropic participants (14). They reported the mean subfoveal CT in 152 emmetropic eyes as $346.64 \pm 59.63 \mu\text{m}$. The number of emmetropic participants was relatively smaller than our study and the age range was wider than our study.

The most similar study with our study according to the similar SE and age groups was the study of Lee et al. from Australia (15). They investigated the 741 young adults (19–30 years of age) with mean SE was -0.13 D including four different ethnicities; White ($n=627$), East Asian ($n=19$), South Asian ($n=9$), and other ($n=87$). The mean central CT was reported as $362 \pm 6.82 \mu\text{m}$. However, this study was a multiethnic study. Another multiethnic study was conducted by Song et al. their

study included 2794 eyes of 1619 multiethnic Asian participants (Chinese, Indian, and Malay), the mean age was 60.9 ± 7.7 years, mean subfoveal CT was reported as 255.2 ± 102.6 μm (16). Considering ethnicity, the mean subfoveal CT was found 235.4 ± 90.2 μm in Malays; 261.2 ± 110.5 μm in Chinese; and 277.3 ± 95.7 μm in Indians. The number of participants of this study is larger than our study. However, their study included the eyes with BCVA better than 20/60, not eyes with BCVA 10/10, and their participants are older than our participants. Therefore, these characteristics of the study should be kept in mind while evaluating the results of this study, as it provides information according to ethnic origin.

Abdolrahimzadeh et al., from Italy, investigated the 120 eyes of participants aged were between 20 and 79 years reported the mean CT in 1 mm early treatment diabetic retinopathy study area as 431.8 ± 82.3 μm in subjects aged between 20 and 23 years ($n=20$) and 402.9 ± 80.5 μm in subjects aged between 20 and 29 years ($n=20$) (17). The mean SE was 0.47 ± 1.49 D with a range of ± 3 D in their study. This study may be compared to our study according to the age groups but our study's population was larger than this study and our study included emmetropic subjects while this study included emmetropic, myopic, and hyperopic subjects.

When we examine Turkish studies, different results appear. Tuncer et al. investigated the 154 eyes in 154 healthy subjects with the mean age was 49.01 ± 19.19 years, the mean SE was -0.17 ± 1.20 D, and the mean AL was 23.39 ± 0.76 mm (range, 21.40–25.90 mm) (18). They reported the mean subfoveal CT as 265.86 ± 60.32 μm . Another study was the study of Coskun et al. (19) Their study included 70 subjects with the mean age was 32.9 ± 11.6 years (range: 16–70 years), the mean AL was 23.31 ± 0.91 mm (range: 20.77–26.10 mm), and the mean SE was -0.15 ± 1.64 D (range: -5.75 – 5.50). They reported the mean subfoveal CT as 326 ± 60 μm . These two studies had some differentiations comparing with our study. First, the distributions of age, SE, and AL did not exactly reflect those of a normal population. Second, the study population was relatively small. The other study was conducted by Osmanbasoglu et al. (20) They investigated the diurnal CT changes in normal eyes of Turkish people and they found the central CT as 308.7 ± 64.5 μm at 9 AM. Their study design is similar to our study according to the participants' SE range and AL range. However, the age range was wider than our study and the number of subjects ($n=50$) was lower than our study.

In the present study, CT was found thicker than many previous studies. This condition could be explained by the proportions of the study population. First, we included emmetropic subjects while many studies included myopic subjects. It is well known that CT is thinner in myopic eyes (21). Second, we included the AL of subjects between 22 mm and 25 mm while a range of many studies was bigger than our

study. It is well known that AL negatively affects CT. Third, we included the participants with ages between 20 and 40 years while a range of many studies was greater than our study. In addition, in our study, we divided the participants into two groups according to their ages, between 20 and 30 years and between 31 and 40 years. We found no significant difference between the groups and this study shows that age has no effect on CT between 20 and 40 years. This result is similar to the results of the study of Bhayana et al. (11) Although CT decreases with age, age-related choroidal thinning was detected mostly after 60 years (10).

In the present study, females had thinner subfoveal CT, nasal CT and thinner CMT than males although males had longer AL and males were more myopic SE than females. Our results were parallel to the literature. Gupta et al. reported thicker CT in males than females (22). Li et al. reported that CT was 18% higher in men than in women (23). Females have higher basal sympathetic tone than males which can cause vasoconstriction (24). This may explain the difference.

This study has some limitations. First, the study population was relatively small. Second, CT were conducted manually because the Heidelberg Spectralis OCT equipment does not provide automatic segmentation of the choroid. Third, factors such as smoking, caffeine consumption, and menstrual cycle also affect the CT (25-27). In this study, only cigarette consumption questioned and participant with history of smoking was excluded from the study.

Conclusion

The thickness of the choroidal tissue is affected by some parameters such as age, sex, AL, refractive error, circadian rhythm, and ethnicity (8,28). From these parameters, age, AL, refractive error, and circadian rhythm may be standardized and changed with the design of the study, and the influence of the genetic factor (ethnicity) on CT can be more prominent. Ethnicity cannot be changed. In the present study, we standardized the age, diurnal variation, refractive error, and AL and we have minimized the effects of those parameters on CT. Thus, we investigated the mean CT of the Turkish population. We think that the present study is important in terms of its features and design, and we think that this study reports the CT of healthy individuals in Turkish society more accurately.

Disclosures

Ethics Committee Approval: All procedures performed in studies involving human participants were in accordance with the ethical standards of the institutional and/or national research committee and with the 1964 Helsinki Declaration and its later amendments or comparable ethical standards. IRB/ethics committee name, date and number: Hitit University Faculty of Medicine, 10/03/2021, 2021-402.

Peer-review: Externally and internally peer reviewed.

Conflict of Interest: The authors declare that they have no conflict of interest.

Financial Disclosure: The authors declared that this study received no financial support.

Authorship Contributions: Concept – S.C., M.B.U.; Design – S.C., M.B.U.; Supervision – S.C., T.S.; Materials – S.C., M.B.U., T.S.; Data collection and/or processing – S.C., M.B.U., T.S.; Analysis and/or interpretation – S.C., T.S.; Literature search – S.C., T.S.; Writing – S.C.; Critical review – S.C., M.B.U., T.S.

References

- Harris A, Bingaman D, Ciulla TA, Martin B. Retina and choroidal blood flow in health and disease. In: Ryan SJ, editor. Retina. 4th ed. China: Elsevier Mosby; 2006. p. 83–102. [\[CrossRef\]](#)
- Gupta B, Mohamed MD. Photodynamic therapy for variant central serous chorioretinopathy: Efficacy and side effects. *Ophthalmologica* 2011;225:207–10. [\[CrossRef\]](#)
- Grossniklaus HE, Green WR. Choroidal neovascularization. *Am J Ophthalmol* 2004;137:496–503. [\[CrossRef\]](#)
- Gomi F, Tano Y. Polypoidal choroidal vasculopathy and treatments. *Curr Opin Ophthalmol* 2008;19:208–12. [\[CrossRef\]](#)
- Rajendram R, Evans M, Rao NA. Vogt-Koyanagi-Harada disease. *Int Ophthalmol Clin* 2005;45:115–34. [\[CrossRef\]](#)
- Fitzgerald ME, Wildsoet CF, Reiner A. Temporal relationship of choroidal blood flow and thickness changes during recovery from form deprivation myopia in chicks. *Exp Eye Res* 2002;74:561–70. [\[CrossRef\]](#)
- Akhtar Z, Rishi P, Srikanth R, Rishi E, Bhende M, Raman R. Choroidal thickness in normal Indian subjects using Swept source optical coherence tomography. *PLoS One* 2018;13:e0197457.
- Wei WB, Xu L, Jonas JB, Shao L, Du KF, Wang S, et al. Subfoveal choroidal thickness: The Beijing eye study. *Ophthalmology* 2013;120:175–80. [\[CrossRef\]](#)
- Fujiwara A, Shiragami C, Shirakata Y, Manabe S, Izumibata S, Shiraga F. Enhanced depth imaging spectral-domain optical coherence tomography of subfoveal choroidal thickness in normal Japanese eyes. *Jpn J Ophthalmol* 2012;56:230–5. [\[CrossRef\]](#)
- Ding X, Li J, Zeng J, Ma W, Liu R, Li T, et al. Choroidal thickness in healthy Chinese subjects. *Invest Ophthalmol Vis Sci* 2011;52:9555–60. [\[CrossRef\]](#)
- Bhayana AA, Kumar V, Tayade A, Chandra M, Chandra P, Kumar A. Choroidal thickness in normal Indian eyes using swept-source optical coherence tomography. *Indian J Ophthalmol* 2019;67:252–5. [\[CrossRef\]](#)
- Jirattanasopa P, Panon N, Hiranyachattada S, Bhurayanontachai P. The normal choroidal thickness in Southern Thailand. *Clin Ophthalmol* 2014;8:2209–13. [\[CrossRef\]](#)
- Entezari M, Karimi S, Ramezani A, Nikkhah H, Fekri Y, Kheiri B. Choroidal thickness in healthy subjects. *J Ophthalmic Vis Res* 2018;13:39–43. [\[CrossRef\]](#)
- Heirani M, Shandiz JH, Shojaei A, Narooie-Noori F. Choroidal thickness profile in normal Iranian eyes with different refractive status by spectral-domain optical coherence tomography. *J Curr Ophthalmol* 2020;32:58–68. [\[CrossRef\]](#)
- Lee SS, Lingham G, Alonso-Caneiro D, Chen FK, Yazar S, Hewitt AW, et al. Choroidal thickness in young adults and its association with visual acuity. *Am J Ophthalmol* 2020;214:40–51. [\[CrossRef\]](#)
- Song Y, Tham YC, Chong C, Ong R, Fenner BJ, Cheong KX, et al. Patterns and determinants of choroidal thickness in a multiethnic Asian population: The Singapore epidemiology of eye diseases study. *Ophthalmol Retina* 2021;5:458–67. [\[CrossRef\]](#)
- Abdolrahimzadeh S, Parisi F, Scavella V, Recupero SM. Optical coherence tomography evidence on the correlation of choroidal thickness and age with vascularized retinal layers in normal eyes. *Retina* 2016;36:2329–38. [\[CrossRef\]](#)
- Tuncer I, Karahan E, Zengin MO, Atalay E, Polat N. Choroidal thickness in relation to sex, age, refractive error, and axial length in healthy Turkish subjects. *Int Ophthalmol* 2015;35:403–10.
- Coşkun E, Okumuş S, Gürler B, Yayuspayı R, Oren B, Kaydu E, et al. Choroidal thickness in healthy Turkish subjects. *Turk J Med Sci* 2014;44:56–61. [\[CrossRef\]](#)
- Osmanbasoglu OA, Alkin Z, Ozkaya A, Ozpınar Y, Yazici AT, Demirok A. Diurnal choroidal thickness changes in normal eyes of Turkish people measured by spectral domain optical coherence tomography. *J Ophthalmol* 2013;2013:687165. [\[CrossRef\]](#)
- Flores-Moreno I, Lugo F, Duker JS, Ruiz-Moreno JM. The relationship between axial length and choroidal thickness in eyes with high myopia. *Am J Ophthalmol* 2013;155:314–9. [\[CrossRef\]](#)
- Gupta P, Jing T, Marziliano P, Cheung CY, Baskaran M, Lamoureux EL, et al. Distribution and determinants of choroidal thickness and volume using automated segmentation software in a population-based study. *Am J Ophthalmol* 2015;159:293–301.
- Li XQ, Larsen M, Munch IC. Subfoveal choroidal thickness in relation to sex and axial length in 93 Danish university students. *Invest Ophthalmol Vis Sci* 2011;52:8438–41. [\[CrossRef\]](#)
- Ovet G, Alpıdan I, Sakarya Y, Sakarya R, Ozcimen M, Gökaş S, et al. The acute effect of pseudoephedrine on choroidal thickness. *Clin Ter* 2016;167:63–6.
- Ulaş F, Çelik F, Doğan Ü, Çelebi S. Effect of smoking on choroidal thickness in healthy smokers. *Curr Eye Res* 2014;39:504–11.
- Altinkaynak H, Ceylan E, Kartal B, Keleş S, Ekinçi M, Olcaysu OO. Measurement of choroidal thickness following caffeine intake in healthy subjects. *Curr Eye Res* 2016;41:708–14. [\[CrossRef\]](#)
- Ulaş F, Doğan U, Duran B, Keleş A, Ağca S, Celebi S. Choroidal thickness changes during the menstrual cycle. *Curr Eye Res* 2013;38:1172–81. [\[CrossRef\]](#)
- Tan CS, Ouyang Y, Ruiz H, Sadda SR. Diurnal variation of choroidal thickness in normal, healthy subjects measured by spectral domain optical coherence tomography. *Invest Ophthalmol Vis Sci* 2012;53:261–6. [\[CrossRef\]](#)