

A rare cause of neonatal bradycardia: Blocked atrial bigeminal beat

Yenidoğan bradikardisinin nadir bir nedeni: Bloke atriyal bigemine atım

İbrahim ECE¹, Abdurrahman ÜNER¹, Şevket BALLI², Mehmet Burhan OFLAZ³

¹Yüzüncü Yıl Üniversitesi, Tıp Fakültesi, Çocuk Kardiyoloji BD, Van

²Balıkesir Atatürk Hastanesi, Çocuk Kardiyoloji Kliniği, Balıkesir

³Cumhuriyet Üniversitesi, Tıp Fakültesi, Çocuk Kardiyoloji BD, Sivas

Dear Editor,

Bradycardia is defined as a heart rate below the lowest normal value adjusted for age. It is caused by intrinsic dysfunction, injury to the heart's conduction system or by extrinsic factors acting on a normal heart and its conduction system (1). Premature atrial contractions (PACs), are a rare cause of bradycardia. A slow heart rate may occur in that the sinus node discharges a PAC that's blocked before causing the atria to contract (2,3). Herein, we report a newborn with frequent premature atrial contractions in bigeminal pattern. The bradycardiac patient with bradycardia was successfully treated with propafenone.

Herein, we present the case of a 10-day-old infant that was referred to our department for bradycardia. A female neonate of 3100 gr and Apgar score of 8/10 at 1/5 minutes was born by normal spontaneous vaginal delivery at 39. gestational weeks. Her physical examination was normal except bradycardia. Pulse rate was 72 bpm, and blood pressure was 68/32 mmHg. Careful review of her electrocardiogram (ECG) revealed that closely coupled bigeminy PACs were blocked at the atrioventricular junction, mimicking severe sinus bradycardia (Figure 1). No significant abnormalities were found on her echocardiogram,

and laboratory test results (complete blood count, biochemical panel and brain natriuretic peptide) were normal. Holter ECG monitoring showed a sinus rhythm with very frequent blocked atrial bigeminy, and short runs of atrial tachycardia. Mean heart rate was 83 bpm, while the minimal, and maximal heart rates was 63 bpm, and 98 bpm, respectively. An antiarrhythmic medication (propranolol) was started without any improvement in the antiarrhythmic control. This treatment was stopped and therapy with propafenone (300 mg/m²/d) was initiated.

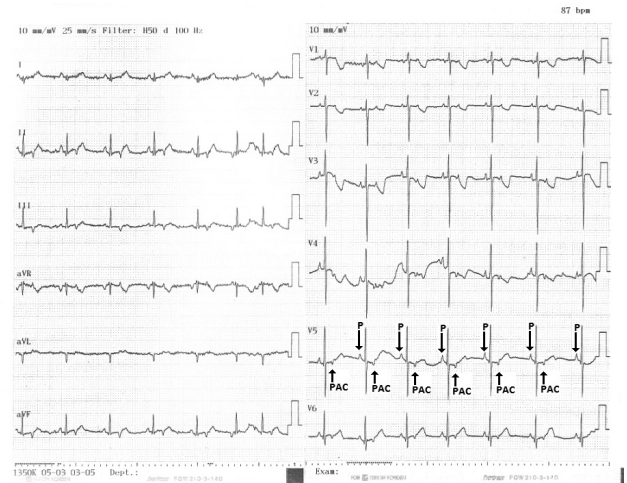


Figure 1. Blocked supraventricular atrial contractions. P, P wave; PAC, premature atrial contraction.

Alındığı tarih: 13.09.2013

Kabul tarihi: 21.10.2013

Yazışma adresi: Yard. Doç. Dr. İbrahim Ece, Yüzüncü Yıl Üniversitesi, Tıp Fakültesi, Çocuk Kardiyoloji Bilim Dalı, Van
e-mail: dibrhimece@gmail.com

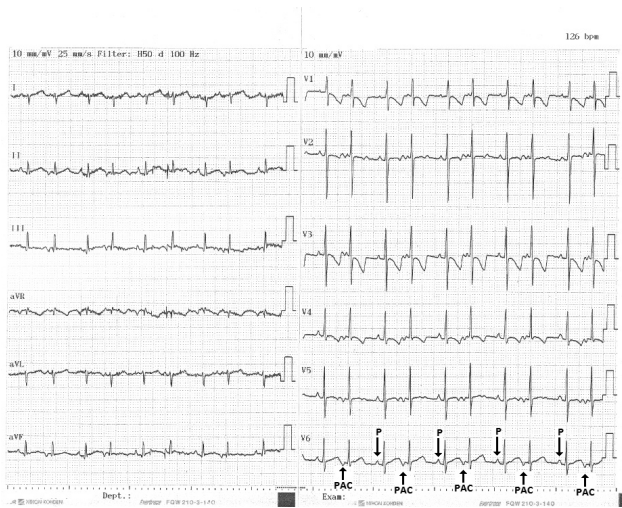

Figure 2. Antiarrhythmic medication was started with Propafenone. On follow-up 12-lead electrocardiogram, all of the PACs conducted. P, P wave; PAC, premature atrial contraction.

ed. On follow-up Holter monitor recordings, the prevalence of premature beats decreased and the mean heart rate increased to 128 bpm. All of the PACs were monitored on ECG (Figure 2). Premature beats were not observed on the ECG obtained 2 months after discharge and normal sinus rhythm was restored.

PACs which are common in neonates, are usually benign, and do not require specific therapy (4). Most PACs result in a normal QRS morphology. If the PACs occur when AV node is refractory, the impulse will not be conducted to the ventricle and may therefore give the appearance of a marked sinus bradycardia (5). Sometimes, PAC wave may not be easily visible on the surface ECG, especially if it is superimposed on the T wave of the preceding sinus beat. If this premature P wave is not obvious, the pause may be incorrectly diagnosed as a sinoatrial block. In the presented case, PAC wave can be easily distinguished. Furthermore, both blocked atrial bigeminy and also second-degree atrioventricular block with 2:1 conduction block both present as ventricular bradycardia. Propafenone hydrochloride, a class IC antiarrhythmic agent, combines sodium its channel-

blocking effects with β -blocking capacities and a weak calcium antagonism. Oral propafenone is effective for the suppression of PACs-induced bradycardia and supraventricular tachycardias (6,7). In this patient, propafenone was used successfully to prevent bradycardia and tachycardia. Administration of antiarrhythmic drugs to patients with marked bradycardia seems inappropriate. However, suppression of PACs led to a paradoxical increase in heart rate. Blocked PACs can be a rare cause of bradycardia in newborn, so it is necessary to analyze ECGs carefully. Without the careful review of surface ECGs, the patient may have undergone pacemaker implantation. Propafenone can be used safely and effectively in such patients.

Conflicts of Interest

None.

REFERENCES

1. Mangrum JM, DiMarco JP The evaluation and management of bradycardia. *N Engl J Med* 2000;342:703-9. <http://dx.doi.org/10.1056/NEJM200003093421006> PMID:10706901
2. Veress G. Infra-His blocked premature atrial contractions simulating 2:1 sinoatrial block in a patient with an atrio-His bypass tract. *Chest* 1993;104:1306-1308. <http://dx.doi.org/10.1378/chest.104.4.1306> PMID:7691482
3. Veress G, Böszörményi E. Bigeminal occurrence of infra-His blocked premature atrial contractions associated with carotid sinus syndrome. *Chest* 1988;94:866-868. <http://dx.doi.org/10.1378/chest.94.4.866> PMID:2458889
4. Dubin AM. Arrhythmias in the newborn. *Neoreviews* 2000;1:146-51. <http://dx.doi.org/10.1542/neo.1-8-e146>
5. Spodick DH. Bradycardia due to blocked atrial bigeminy. *Am J Geriatr Cardiol* 2006;15:328. <http://dx.doi.org/10.1111/j.1076-7460.2006.05878.x> PMID:16957456
6. Paul T, Janousek J. New antiarrhythmic drugs in pediatric use: propafenone. *Pediatr Cardiol* 1994;15:190-7. <http://dx.doi.org/10.1007/BF00800674>
7. Akdeniz C, Tanidir IC, Tuzcu V. Blocked atrial bigeminy presenting with bradycardia. *Congenit Heart Dis* 2012;7:E82-4. <http://dx.doi.org/10.1111/j.1747-0803.2012.00646.x> PMID:22469245