

## Epitelyal Over Karsinomunda İntraperitoneal Kemoterapi sırasında oluşan Peritonovajinal Fistül

### Peritoneovaginal Fistula during Intraperitoneal Chemotherapy of Epithelial Ovarian Carcinoma

Umut Demirci<sup>1</sup>, Havva Yeşil Çınkır<sup>1</sup>, Bülent Yalçın<sup>2</sup>

<sup>1</sup>Dr. A. Y. Ankara Onkoloji Eğitim Ve Araştırma Hastanesi, Tıbbi Onkoloji Kliniği, Ankara, Türkiye

<sup>2</sup>Atatürk Eğitim Ve Araştırma Hastanesi, Tıbbi Onkoloji Kliniği, Ankara, Türkiye

Received: 14.07.2014 Accepted: 17.07.2014 DOI:10.5505/aot.2014.08208

**Anahtar Kelimeler:** İntraperitoneal tedavi; over neoplazmları; peritoneovajinal fistül

**Key words:** Intraperitoneal treatment; ovarian neoplasms; peritoneovaginal fistula

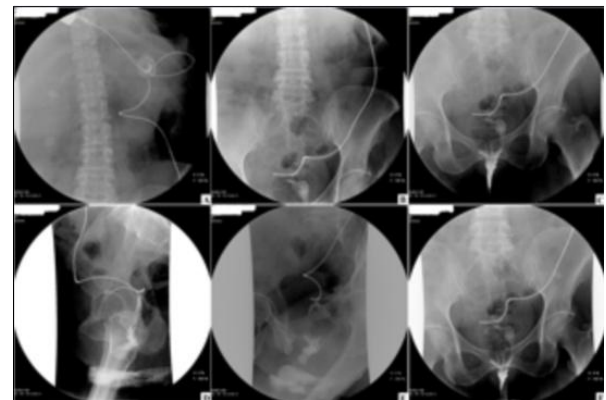
To Editor,

Intraperitoneal (IP) treatment has been achieved the best overall survival (OS) for optimally resected stage III epithelial ovarian carcinoma (EOC) (1). However catheter-related complications are reason for discontinuation of the IP regimen. Here, we describe a case with stage IIIC EOC, who developed peritoneovaginal fistula during first course of IP treatment.

A 59 year-old woman who had been on menopause for 17 years admitted with abdominal pain. Multiple intraabdominal lymph nodes, omental cake and massive ascites were detected in her evaluation studies. The cytology of paracentesis revealed malignant epithelial tumor. Total abdominal hysterectomy, bilateral salpingoophorectomy, parapelvic paraaortic lymph node dissection, omentectomy, appendectomy and IP port implantation were performed for EOC. Pathological examination showed high grade serous papillary carcinoma. IP cisplatin (day 1) and intravenous paclitaxel (day 1) and IP paclitaxel (day 8) every 21 days were planned as adjuvant treatment of stage IIIC EOC. During the first administration of IP cisplatin vaginal discharge occurred. Peritoneovaginal fistula tract was observed in opaque graphics (Fig 1). IP therapy was stopped and then both chemotherapeutic agents were given intravenously as adjuvant treatment, in this case.

Combination of IP and intravenous chemotherapy showed 16-month OS advantage for optimally resected stage III EOC (1). However, catheter-related complications are common reasons (13-40%) for discontinuation of IP treatment. These are abdominal pain, bleeding, infection, peritonitis, catheter blockage, leakage, movement, malfunction, and/or access problems (2). Peritoneovaginal fistula is a rare complication of IP treatment, “leaky vaginal cuff” was the reason for discontinuation of treatment 2 of the 71 patients in a study (3). Although the significant improvement on survival, IP chemotherapy should be given carefully.

**Conflict of Interest:** There is a no conflict of interest



**Figure 1:** Peritoneovaginal fistula tract was observed in opaque graphics



## References

1. Armstrong D, Bundy B, Wenzel L, et al. Intraperitoneal Cisplatin and Paclitaxel in ovarian cancer. *N Engl J Med.* 2006;354:34-43.
2. Landrum LM, Gold MA, Moore KN, Myers TK, McMeekin DS, Walker JL. Intraperitoneal chemotherapy for patients with advanced epithelial ovarian cancer: a review of complications and completion rates. *Gynecol Oncol.* 2008;108:342-7
3. Zeimet AG, Reimer D, Radl AC, et al. Pros and cons of intraperitoneal chemotherapy in the treatment of epithelial ovarian cancer. *Anticancer Res.* 2009;29:2803-8.