

Case Report

Fasciola Hepatica Case Considered as Cholangiocarcinoma on Imaging

Görüntüleme Kolanjiokarsinom Olduğu Düşünülen Fasciola Hepatica Olgusu

Ahmet Aydın¹, Sabin Göktaş Aydın², Banu Karaalioğlu³¹Department of Internal Medicine, Istanbul Medipol University Hospital, Istanbul²Department of Medical Oncology, Medipol University Hospital, Istanbul³Department of Radiology, Medipol University Hospital, Istanbul

ABSTRACT

Fascioliasis is a zoonotic infection and causes fever, eosinophilia, nausea, and even a mass interpreted as a malignancy on imaging. The diagnosis of the disease is difficult because of the wide spectrum of clinical features. This trematode infection is mainly observed in developing countries. Here we report a case of hepatic mass, mistakenly reported as cholangiocarcinoma, caused by fasciola hepatica.

Keywords: Fascioliasis, hepatic mass, triclabendazole

ÖZET

Fascioliasis zoonotik bir enfeksiyondur ve ateş, eozinofili, bulantı ve hatta görüntüleme malignite olarak yorumlanan bir kitleye neden olur. Klinik özelliklerinin geniş bir yelpazeye sahip olması nedeni ile hastalığı teşhis etmek zordur. Bu trematod enfeksiyonu daha çok gelişmekte olan ülkelerde görülmektedir. Burada fasciola hepatica'nın neden olduğu yanlışlıkla kolanjiokarsinom olarak bildirilen bir karaciğer kitlesi vakasını sunuyoruz.

Anahtar kelimeler: Fascioliasis, hepatik kitle, triklabendazol

Introduction

Fasciola hepatica is a trematode that infects mammals' livers and causes an infection of the biliary tract [1]. Typical findings are abdominal pain, fever, malaise, weight loss, urticaria, eosinophilia and leukocytosis. Examination of the stool specimens is the diagnostic test [2,3]. However, in some cases, blood tests can be helpful, including parasite antibodies. Radiological imaging supports the diagnosis. In addition, fascioliasis may have a similar radiological appearance to other diseases of the liver and bile ducts such as cholangiocarcinoma etc. [3]. Triclabendazole, used in a single oral dose of 10 mg/kg, is the drug of choice for the treatment [4]. Here we present a case of hepatic mass caused by

fasciolosis that was initially thought to be cholangiocarcinoma.

Case

A 46-year-old woman living in Istanbul was admitted to our hospital with the complaint of abdominal pain, fever and itching. She had lost 8 kg in the past 6 months, as well. A complete blood count revealed eosinophilia (2,900/mm³, N: 0–400/mm³, 36% of leukocytes), which was confirmed by a peripheral blood smear. Serum chemical analysis revealed the following values: albumin, 3.4 g/dl; alkaline phosphatase, 170 U/l (normal range, 53–128); alanine aminotransferase, 43 U/l (normal range, 10–35); aspartate aminotransferase, 54 U/l (normal range, 14–50); and total bilirubin, 1.2

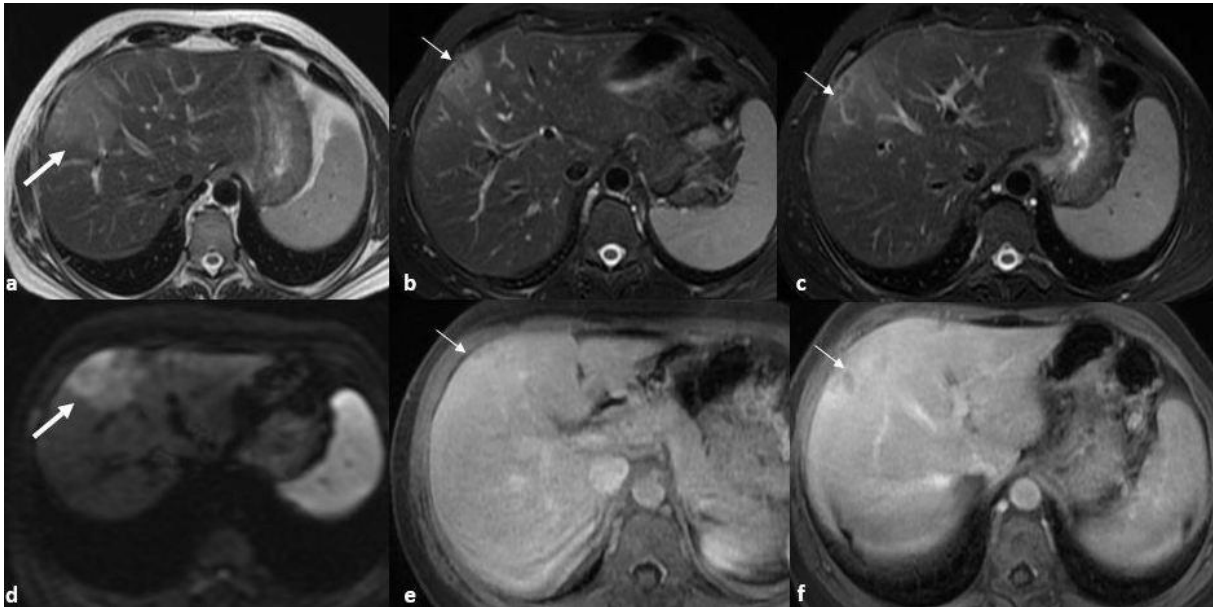


Figure 1. a) Axial T2 FSE image shows a peripherally located hyperintense lesion, favouring a mass. b,c) In axial fat sat T2 FSE image, hypointense tracts were seen in the lesion beneath the capsule extending centrally (thin arrow). d) In DWI, marked diffusion restriction is seen in lesions which is also observed in malignant masses of the liver. e,f) In contrast, enhanced axial fat-sat T1 weighted image, the lesion shows slightly more contrast enhancement.

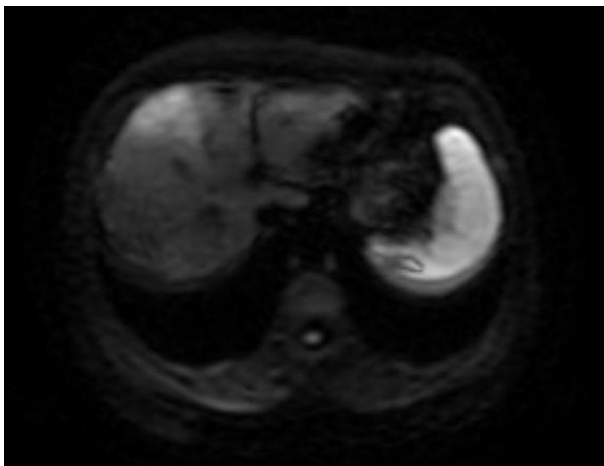


Figure 2. Contrast enhanced T1-weighted image shows the hyperintensity of the mass in right lobe.

mg/dl (normal range 0.3–1.2), AFP: 2.3 ng/ml (normal range <6.0 ng/ml), erythrocyte sedimentation rates: 55 mm/h (normal range < 30 mm/h). Because of a mass in abdominal ultrasonography, Magnetic resonance imaging (MRI) was revealed, which mass was thought to be a cholangiocarcinoma. (Figure 1,2). In stool specimens, there was not found

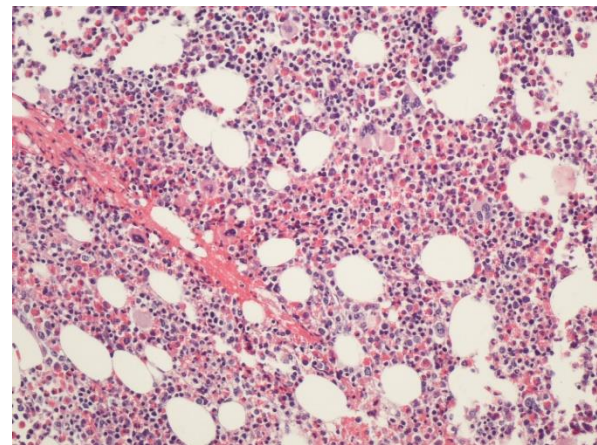


Figure 3. Bone marrow biopsy shows hypercellular bone marrow rich in eosinophilic cells

any parasitic eggs. Hyper-eosinophilic syndrome was excluded by bone marrow biopsy (Figure 3). To establish a definite diagnosis, a hepatic biopsy was performed. Tru-cut liver biopsy in the 5th segment: the material consists of liver parenchyma containing intense and widely eosinophil-rich active inflammation, and granulomatous

lesions consisting entirely of eosinophils were observed. Diagnosis of the parasitic infection was made by serologic test. Serologic test for *Fasciola hepatica* showed high titer against that (positive titer 1/80). Following the diagnosis, triclabendazole was administered at a dose of 10–12 mg/kg for 1 or 2 days; after which the symptoms disappeared (Figure 3), biochemical values soon returned to normal, hepatic mass disappeared, and the patient was discharged with good condition.

Discussion

Fasciola hepatica is mostly seen in developing countries, and the eggs in stool cannot be detected in the acute stage of the disease unless they become adults. Moreover, parasite eggs cannot be seen in chronic fascioliasis due to an ectopic location of the infection [2].

FAST-ELISA, indirect hemagglutination, complement fixation, indirect immunofluorescence (IIF), counter electro-phoresis, and double diffusion can be used as serological tests for the diagnosis of acute fascioliasis. ELISA testing is more rapid and reliable, with a sensitivity rate of 95%. With the treatment, serological titers decline, and antibodies are detectable even for years after infection [5,6].

REFERENCES

1. Mahanty S, Maclean JD, Cross JH. Liver, Lung, and Intestinal Fluke Infections. In: Tropical Infectious Diseases: Principles, Pathogens and Practice, 3rd ed, Guerrant RL, Walker DH, Weller PF (Eds), Saunders Elsevier, Philadelphia 2011. p.854.
2. Sivagnanam S, van der Poorten D, Douglas MW. Hepatic lesions and eosinophilia in an urban dweller. *Liver Int* 2014; 34:643.
3. Webb CM, Cabada MM. Recent developments in the epidemiology, diagnosis,

Radiological evaluation is an important part. Ultrasonography can detect parasite movement in the gall bladder or liver lesion. Contrast-enhanced CT and MRI can demonstrate the parenchymal involvement and subcapsular low attenuation regions. Additionally, the parenchymal lesion shows contrast enhancement relative to liver parenchyma in contrast to the tracts, which is a clue for fascioliasis. [7]. However, fascioliasis may present with multiple nodular lesions, solitary nodular lesions etc., which can cause dilemma or confusion, as in our case.

Triclabendazole is the effective treatment of *Fasciola hepatica* infections. The drug is administered at a dose of 10 mg/kg for 1 or 2 days and is well-tolerated [4]. We treated our patient with triclabendazole as well.

To conclude, *Fasciola hepatica* may cause a mass that may mistakenly suggest liver cancer on imaging, as in our case. While evaluating a patient with liver mass and hypereosinophilia, the differential diagnosis should include parasitic infections. It should not be forgotten that the absence of parasite eggs in the stool does not exclude the diagnosis, and it should be kept in mind that the diagnosis can be made with serum tests.

and treatment of *Fasciola* infection. *Curr Opin Infect Dis* 2018; 31: 409-414.

4. Hillyer GV, Soler de Galanes M, Rodriguez-Perez J, Bjorland J, Silva de Lagrava M, Ramirez Guzman S, Bryan RT. Use of the Falcon assay screening test-enzyme-linked immunosorbent assay (FAST-ELISA) and the enzyme-linked immunoelectrotransfer blot (EITB) to determine the prevalence of human fascioliasis in the Bolivian Altiplano. *Am J Trop Med Hyg.* 1992; 46: 603-9.
5. Carnevale S, Rodriguez MI, Santillan G, Labbe JH, Cabrera MG, Bellegarde EJ, Velasquez JN, Trgovcic JE, Guarnera EA. Immunodiagnosis of

human fascioliasis by an enzyme linked immunosorbent assay (ELISA) and a micro-ELISA. Clin Diagn Lab Immunol. 2001; 8: 174–177.

6. Kabaalioglu A, Cubuk M, Senol U, Cevikol C, Karaali K, Apaydin A, et al. et al. Fascioliasis: US, CT, and MRI findings with new observations. Abdom Imaging. 2000; 25: 400–404.

Corresponding author e-mail: bayrampasadahiliye@gmail.com

Orcid ID:

Ahmet Aydın 0000-0002-8610-768X

Sabin Gökteş Aydın 0000-0002-0077-6971

Banu Karaalioglu 0000-0003-4864-5652

Doi: 10.5505/aot.2022.88156