

## Original Article

## The Evaluation of the Relationship Between ADC Values and Gleason Score in the Prostate Cancer

## Prostat Kanserinde ADC Değerleri ile Gleason Skoru Arasındaki İlişkinin Değerlendirilmesi

Şehnaz Tezcan<sup>1</sup>, Funda Ulu Öztürk<sup>2</sup><sup>1</sup>Koru Hospital, Radiology Department<sup>2</sup>Başkent University School of Medicine, Radiology Department

## ABSTRACT

**Introduction:** The purpose of this study was to evaluate the apparent diffusion coefficient (ADC) values of different grades of prostate cancer (PC) and determine whether the use of ADC values could predict the tumor aggressiveness in PC.

**Materials and methods:** Fortyseven patients (Gleason score (GS)  $\geq 6$ ) who underwent prostate multi-parametric MRI (1.5 Tesla) between January 2017 and December 2020 for the evaluation of suspicious findings on clinical or laboratory evaluation were enrolled in this study. The specimens which were obtained from systematic 12-core trans-rectal ultrasound (TRUS)-guided biopsy were used for histopathologic diagnoses. The average ADC values within the tumors were calculated. Independent sample t-test, one-way analysis of variance (ANOVA, Tukey's post-hoc or Tamhane) and receiver operating characteristics (ROC) curve analysis were used.

**Results:** The mean ADC value of high-risk patients which was  $585.4 \pm 138.7 \times 10^{-6}$  mm<sup>2</sup>/s, was significantly lower than other subgroups (p=0.036). The mean ADC value in low-risk group ( $798.1 \pm 236.5 \times 10^{-6}$  mm<sup>2</sup>/s) was significantly higher (p = 0.012) than others. No significant difference in ADC values was found between low-risk vs intermediate-risk groups (p = 0.149) and intermediaterisk vs high-risk groups (p = 0.419). No statistically significant difference in ADC values between GS 3+4 and GS 4+3 (p, 0.552) was found. ROC analysis revealed an optimal ADC cut-off of  $595 \times 10^{-6}$  mm<sup>2</sup>/s for differentiating high-risk group from the other subgroups (sensitivity, 71%; specificity 67.6%, p, 0.038). For the determination of low-risk group, an ADC cut-off of  $665 \times 10^{-6}$  mm<sup>2</sup>/s (sensitivity, 80%; specificity, 65.6%, p, 0.017) was found.

**Discussion:** While ADC values may differentiate the high-risk and low-risk tumors, the strength of ADC in the prediction of intermediate-risk tumors was low. The ADC cut-off value of  $665 \times 10^{-6}$  mm<sup>2</sup>/s showed the high sensitivity and moderate specificity for the detection of low-risk tumors.

**Keywords:** Diffusion-weighted imaging, ADC values, Gleason score, Prostate cancer

## ÖZET

**Giriş:** Bu çalışmanın amacı, farklı derecelerdeki prostat kanserinin (PK) görünür difüzyon katsayısı (ADC) değerlerini değerlendirmek ve ADC değeri kullanımının PK'deki tümör agresifliğini tahmin edip edemeyeceğini değerlendirmektir.

**Gereç ve yöntemler:** Ocak 2017 ile Aralık 2020 arasında klinik veya laboratuvar bulgularına göre şüpheli olguların değerlendirilmesi için multi-paramterik prostat MRG (1.5 Tesla) çekimi yapılan 47 hasta (Gleason skoru (GS)  $\geq 6$ ) çalışmaya dahil edildi. Histopatolojik tanı için trans-rektal ultrason (TRUS) kılavuzluğunda 12 kor sistemik biyopsiden elde edilen örnekler kullanıldı. Tümör içindeki ortalama ADC değerleri hesaplandı. Bağımsız örneklem t testi, tek yönlü varyans analizi (ANOVA, Tukey's post-hoc veya Tamhane) ve "receiver operating characteristics" (ROC) eğrisi analizi kullanıldı.

**Bulgular:** Yüksek riskli hastaların ortalama ADC'si  $585.4 \pm 138.7 \times 10^{-6}$  mm<sup>2</sup>/s ölçülmüş olup diğer risk alt gruplarına göre anlamlı olarak daha düşüktü (p = 0.036). Düşük risk grubundaki hastalarda ortalama ADC değeri ( $798,1 \pm 236.5 \times 10^{-6}$  mm<sup>2</sup>/s) diğer gruplara göre anlamlı olarak daha yüksekti (p = 0,012).

Düşük riskli ile orta riskli gruplar ( $p = 0.149$ ) ve orta riskli ile yüksek riskli gruplar ( $p = 0.419$ ) arasında ADC değerlerinde anlamlı bir fark bulunmadı. GS 3+4 ve GS 4+3 arasında ADC değerlerinde istatistiksel olarak anlamlı bir fark bulunmadı ( $p, 0,552$ ). ROC analiziyle, yüksek risk grubunu diğer alt gruplardan ayırt etmek için optimal ADC eşik değeri  $595 \times 10^{-6} \text{ mm}^2/\text{s}$  olarak hesaplandı (duyarlılık, %71; özgüllük %67,6,  $p, 0,038$ ). Düşük risk grubunun belirlenmesi için ADC eşik değeri  $665 \times 10^{-6} \text{ mm}^2/\text{s}$  (duyarlılık, %80; özgüllük, %65,6,  $p, 0,017$ ) olarak bulundu.

**Tartışma:** ADC değerleri yüksek riskli ve düşük riskli tümörleri ayırt edebiliyorken, ADC'nin orta riskli tümörleri tahmin etme gücü düşüktü. ADC eşik değeri olan  $665 \times 10^{-6} \text{ mm}^2/\text{s}$ , düşük riskli tümörlerin tespiti için yüksek duyarlılık ve orta düzeyde özgüllük göstermektedir.

**Anahtar kelimeler:** Difüzyon ağırlıklı görüntüleme, ADC değerleri, Gleason skoru, Prostat kanseri

## Introduction

Prostate cancer (PC) is the most frequently diagnosed disease among men. It is the second most common cause of deaths due to malignant tumors. In recent years, multi-parametric magnetic resonance imaging (mpMRI) has become a widely used technique for the diagnosis of PC prior to biopsy. European Society of Urogenital Radiology (ESUR) has developed the Prostate Imaging Reporting and Data Systems version 1 (PI-RADS v1) to provide a global standardization of diagnosis of PC in 2012 [1]. In PI-RADS v1, lesions were scored 1 to 5 in each individual pulse sequence. Hence, this categorization caused lower agreement in the diagnosis of PC among radiologists due to the lack of assessment of final overall score. Subsequently, PI-RADS version 2 (v2) was published in 2015 to improve diagnostic accuracy [2]. In PI-RADS v2, the dominant sequence was determined for each zone which was diffusion-weighted images (DWI) in peripheral zone (PZ) and T2-weighted images (T2WI) in transition zone (TZ) [1, 2]. The most of the previous studies revealed some limitations and moderate agreement among radiologists in the diagnosis of PC [3]. To enhance PI-RADS v2, PI-RADS version 2.1 (PI-RADSv2.1) has been developed in 2019 which is the current form of the PI-RADS [4].

The diffusion-weighted image (DWI) is a non-invasive and relatively quick method which analyzes the Brownian motion of water molecules in tissues. DWI provides quantitative information by using apparent diffusion coefficient (ADC) maps which represents the tumor cellularity. In the

diagnosis of PC, DWI is the most indicative sequence in the assessment of PI-RADS categorization in particular for peripheral zone lesions. Although, DWI is one of the main sequence of mpMRI, the impact of DWI in the diagnosis is based on direct visual evaluation rather than quantitative methods such as ADC measurement. In breast MRI, ADC values have been used for the differentiation of malignant tumors, determination of aggressiveness and treatment response of breast cancer [5, 6]. Gleason score (GS) is the most common used method for the identification of tumor aggressiveness in PC [7]. The determination of aggressiveness of PC prior to surgery may provide the establishment of the optimal treatment management for patients. At this point, ADC may provide additional quantitative information about the tumor histopathological nature. The aim of this study was to evaluate the ADC values of PC and investigate whether the use of ADC values could provide information about the GS in PC.

## Materials and method

### Patient selection

Our retrospective study was approved by the Institutional Review Board of 'Dr. Abdurrahman Yurtaslan Ankara Oncology Training and Research Hospital' (Decision number and date: 2022-05/1866 and 25.05.2022). This study was conducted in accordance with the ethical standards stated by the 1964 declaration of Helsinki. 413 patients who underwent multi-parametric prostate MRI (1.5 Tesla) between January 2017 and December 2020 for the evaluation of

suspicious findings on clinical or laboratory evaluation were enrolled in this study. Out of 413 patients, 366 were excluded due to the absence of histopathological results in our institution or having benign pathology. 47 patients with malignancy (GS  $\geq$  6) were finally included in this study. Due to the GS, patients were classified in 3 groups which were low-risk (GS= 3+3), intermediate-risk (GS = 3+4, 4+3) and high-risk (4+4, 4+5, 5+4 and 5+5). Histopathologic diagnoses were all proven by specimens which were obtained from systematic 12-core transrectal ultrasound (TRUS)-guided biopsy. All specimens were evaluated by the same experienced pathologist.

#### MRI Protocol

All MRI examinations were performed using 1.5 T MRI (GE Optima 360, USA®) with 8 channel body/torso array coil. All patients were examined in supine position. A routine protocol was performed including T2WI, DWI with ADC map, T2 fat-sat, T1WI and dynamic contrast-enhanced (DCE) images indicates the MRI acquisition parameters and sequences in this study. The DCE images were obtained after administration of 0.1 mmol/kg of gadoteric acid. DWI was performed using b values of 50, 1000, 1400 s/mm<sup>2</sup>. The ADC maps were created automatically. Calculations were made based on mean ADC maps of the circular sampling region of interest (ROI), with care taken to perform measurements in solid areas rather than necrotic/cystic areas and visual artifacts. The area of ROIs ranged from 2 to 20 mm<sup>2</sup> due to the range in size of PCs. We placed three circular ROIs within the lesion after referring to T2 weighted sequence for verification of the lesion boundaries on the ADC map. We calculated the average of the ADC values for all three ROIs within the tumor. All MRI studies were examined by the same experienced radiologist.

#### Statistical Analysis

Statistical analyses were performed using the SPSS (IBM SPSS Statistics for Windows, Version 22.0. Armonk, NY: IBM Corp). The Kolmogorov-Smirnov test was used to

analyze the normal distribution of data. Continuous variables were presented as mean  $\pm$  standard deviation. The ADC values, prostate specific antigen (PSA) levels and age were compared according to the GS (low-grade, intermediate grade and high-grade) using the Independent sample t-test and one-way analysis of variance (ANOVA, Tukey's post-hoc or Tamhane). We used a receiver operating characteristics (ROC) curve analysis with corresponding 95% CIs was used to estimate area under curve (AUC) values to evaluate the association between ADC values and 3 different risk subgroups. The "p" value less than 0.05 was considered to show a significant difference.

#### Results

The mean age of patients was 48.3 $\pm$ 11.3 years. The mean age in low-risk, intermediate-risk and high-risk groups were 65.1, 65.5 and 68.2 years, respectively. There was no statistically significant difference between the three groups regarding the mean age (p=0.582).

The mean PSA values were 6.7 $\pm$ 3 ng/ml, 15.6 $\pm$ 19.6 ng/ml and 27.5 $\pm$ 29.6 ng/ml for low-risk, intermediate-risk and high-risk groups, respectively. However, the difference between groups was not statistically significant (p>0.05).

The GSs of specimens were 6 (3+3) in 15 (31.9%), 7 (3+4) in 10 (21.2%), 7 (4+3) in 10 (21.2%), 8 (4+4) in 7 (14.8%) and 9 (4+5) in 5 (10.6%) patients, respectively. The 15 (31.9%), 20 (42.5%) and 12 (25.5%) patients had low-risk, intermediate-risk and high-risk tumor, respectively.

The mean, minimum and maximum ADC values due to the GSs of patients were demonstrated in Table 1. The ADC values according to the risk classification of patients were shown in Table 2 and Figure 1. The mean ADC value of high-risk patients which was 585.4 $\pm$ 138.7 $\times$ 10<sup>-6</sup> mm<sup>2</sup>/s, was significantly lower than intermediate- and high-risk groups (p=0.036). Representative mpMRI of a 76-year old patient with prostate cancer was demonstrated in figure 2. In this

Table 1. The ADC values of patients due to the Gleason scores of patients

Gleason score	N	ADC minimum ( $\times 10^{-6}$ m <sup>2</sup> /s)	ADC maximum ( $\times 10^{-6}$ mm <sup>2</sup> /s)	ADC Mean $\pm$ SD ( $\times 10^{-6}$ mm <sup>2</sup> /s)
3+3 (Low-risk)	15	335	1121	798.1 $\pm$ 236.5
3+4 (Intermediate-risk)	10	338	937	707.8 $\pm$ 187.9
4+3 (Intermediate-risk)	10	429	967	640.1 $\pm$ 171.9
4+4 (High-risk)	7	345	859	573.8 $\pm$ 177.4
4+5 (High-risk)	5	526	693	601.6 $\pm$ 71.7

\*ADC, apparent diffusion coefficient; SD, standard deviation

Table 2. The ADC values of patients due to the risk groups

	N	ADC minimum ( $\times 10^{-6}$ m <sup>2</sup> /s)	ADC maximum ( $\times 10^{-6}$ mm <sup>2</sup> /s)	ADC Mean $\pm$ SD ( $\times 10^{-6}$ mm <sup>2</sup> /s)
Low-risk	15	335	1121	798.1 $\pm$ 236.5
Intermediate-risk	20	338	967	673.9 $\pm$ 178.7
High-risk	12	345	859	585.4 $\pm$ 138.7

\*ADC, apparent diffusion coefficient; SD, standard deviation

Table 3. One-way ANOVA results between three risk groups.

	ADC values (Mean $\pm$ SD) ( $\times 10^{-6}$ m <sup>2</sup> /s)	P value
Low-risk vs Intermediate-risk	798.1 $\pm$ 236.5 vs 673.9 $\pm$ 178.7	0.149
Intermediate-risk vs High-risk	673.9 $\pm$ 178.7 vs 585.4 $\pm$ 138.7	0.419
Low-risk vs High-risk	798.1 $\pm$ 236.5 vs 585.4 $\pm$ 138.7	<b>0.017</b>

\*ADC, apparent diffusion coefficient; SD, standard deviation

MRI figure, the lesion in the left apex of the peripheral zone showed hypointens signal on T2 image and diffusion restriction on DWI (The mean ADC value of  $408 \times 10^{-6}$  mm<sup>2</sup>/s was calculated). The highest mean ADC was observed in the low-risk group which was significantly higher than the other subgroups (Table 2, Table 3). One-way ANOVA showed no significant difference between low-risk versus (vs) intermediate-risk groups and intermediate-risk vs high-risk groups (Table 3). The mean ADC of high-risk group was significantly lower than low-risk group (Table 2, Table 3). We found higher ADC values in GS 3+4 tumors (ADC,  $707.8 \pm 187.9 \times 10^{-6}$  mm<sup>2</sup>/s) than GS 4+3 (ADC,  $640.1 \pm 171.9 \times 10^{-6}$  mm<sup>2</sup>/s), however, this difference was not statistically significant (p, 0.552).

ROC analysis revealed an ADC cut-off of  $595 \times 10^{-6}$  mm<sup>2</sup>/s for differentiating high-risk group from the other subgroups with having a sensitivity of 71% and a specificity of 67.6% (AUC, 0.702; p, 0.038, Figure 3). ROC analysis also showed an ADC cut-off of  $665 \times 10^{-6}$  mm<sup>2</sup>/s with having a sensitivity of 80%, a specificity of 65.6% for the determination of low-risk group (AUC, 0.719; p, 0.017, Figure 3).

### Discussion

In PC, mpMRI has been widely used imaging modality in recent years. The DWI sequence is one of the major components of mpMRI especially in peripheral zone lesions. Although the direct visual evaluation of DWI is generally sufficient in the assessment of PI-

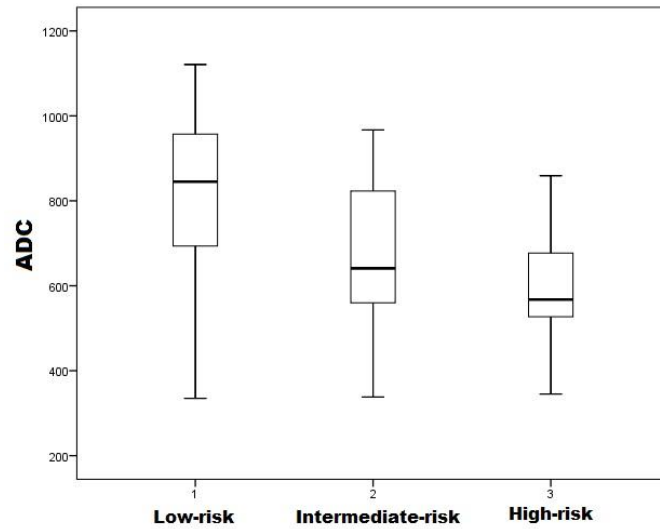


Figure 1. Boxplot showed ADC values in low-risk, intermediate-risk and high-risk groups.

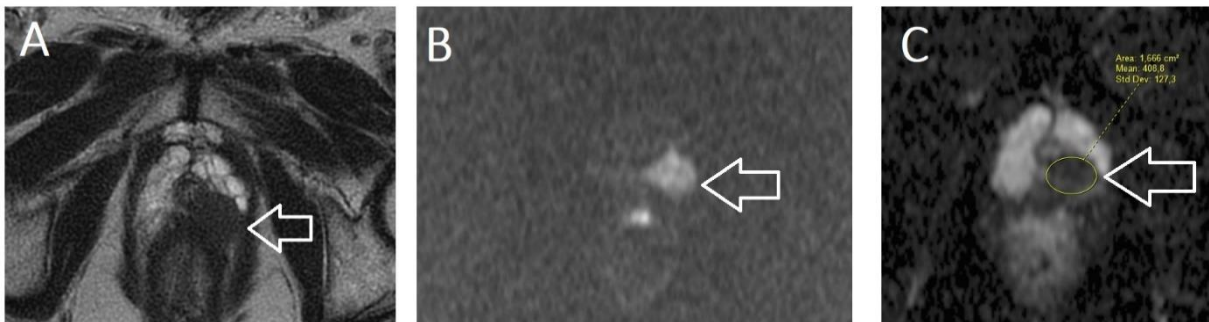


Figure 2. 76-year-old man, A: axial T2, B: axial diffusion weighted imaging, C: axial ADC (apparent diffusion coefficient) map. The lesion in the left apex of the peripheral zone was hyperintense on DWI, hypointense on ADC and T2 images. The mean ADC value of  $408 \times 10^{-6} \text{ mm}^2/\text{s}$  was calculated. The histopathologic result was consistent with prostatic cancer.

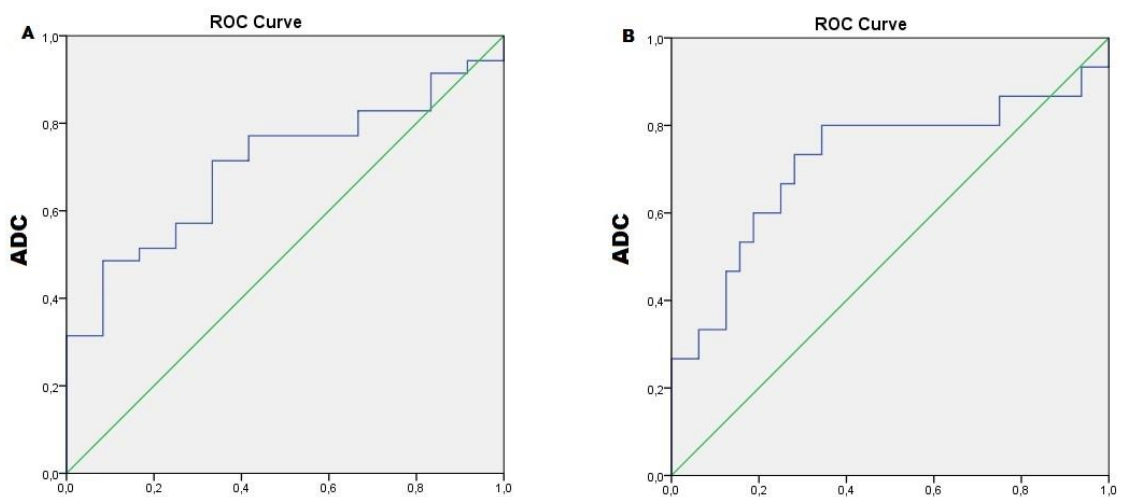


Figure 3. Relative operating characteristic curves (ROC). A. ROC curve in which high-risk group were compared with low- and intermediate-risk groups (AUC, 0.702; p, 0.038). B. ROC curve in which low-risk groups was compared with high- and intermediate-risk groups (AUC, 0.719; p, 0.017).



RADS categorization for the decision of biopsy, the quantitative method such as ADC measurement may improve the diagnostic potential of MRI in both differentiation of malignancy and determination of aggressiveness. As mentioned in literature, the diffusion restriction occurs when cellularity increases in tissues. Some studies showed an inverse relationship between ADC values and GS in PC [8, 9]. Those studies revealed that the dedifferentiation of the tumor with loss of glandular structures and higher cellularity may be a reason of lower ADC in PC [8, 9]. However, the use of ADC is still controversial issue in the determination of aggressiveness. Additionally, a recent meta-analysis revealed a moderate correlation between ADC and GS, in particular with peripheral zone lesions [9].

In our study, the lower mean ADC values ( $585.4 \times 10^{-6} \text{ mm}^2/\text{s}$ ) were found in high risk patients. And also, in low-risk group, the ADC values ( $798.1 \times 10^{-6} \text{ mm}^2/\text{s}$ ) were higher than other subgroups. Previous studies showed higher ADC values (ranged from  $750\text{-}1300 \times 10^{-6} \text{ mm}^2/\text{s}$ ) for low-risk tumor than high-risk tumor with having ADC values between  $485 \times 10^{-6} \text{ mm}^2/\text{s}$  and  $940 \times 10^{-6} \text{ mm}^2/\text{s}$  which were similar to our study [7, 8, 10, 11]. Although, ADC values were significantly different in high- and low-risk groups, the difference of ADC in intermediate group from other subgroups was not statistically significant in this study. In the intermediate-risk group (GS, 7), GS 4+3 has showed more aggressive pattern and higher mortality as compared to GS 3+4 following radical prostatectomy (12). Alessandrino et al. demonstrated that ADC metrics including tumor ADC and tumor/normal tissue ADC can predict the differentiation between GS of 3+4 and 4+3, with acceptable accuracy and low sensitivity rates [12]. Even though, the higher ADC values were found in GS 3+4 than GS 4+3, the difference was not statistically significant in our study.

The quantitative potential of ADC may help urologists to classify patients due to the tumor grading for the management of treatment. At this point, ADC cut-off values come into prominence to determine the aggressiveness. However, variable cut-off values with different accuracy results make confusion in the practical use of ADC in PC. The ADC cut-off value in the discrimination of low-risk tumors ranged from  $820 \times 10^{-6} \text{ mm}^2/\text{s}$  to  $960 \times 10^{-6} \text{ mm}^2/\text{s}$  in the most of the previous studies [7, 13, 14]. While, Woo et al. revealed the ADC cut-off value of  $960 \times 10^{-6} \text{ mm}^2/\text{s}$  with the sensitivity of 77 % and specificity of 76 %, Pepe et al. showed the ADC cut-off value of  $747 \times 10^{-6} \text{ mm}^2/\text{s}$  with the sensitivity of 93% and specificity of 61% for differentiating low grade tumor [7, 11]. In our study, the ADC cut-off value of  $665 \times 10^{-6} \text{ mm}^2/\text{s}$  showed the high sensitivity (80%) and moderate specificity (65%) with AUC of 0.719 for the detection of low-risk tumors. When differentiating high-risk tumors from other subgroups including low- and intermediate-risk groups, an optimal ADC cut-off value of  $595 \times 10^{-6} \text{ mm}^2/\text{s}$  was found with having a sensitivity of 71% and a specificity of 67% in this study. The ADC cut-off values of  $665 \times 10^{-6} \text{ mm}^2/\text{s}$  showed a better accuracy result in differentiating of low-risk tumor than the ADC cut-off values of  $595 \times 10^{-6} \text{ mm}^2/\text{s}$  which was calculated for the differentiation of high-risk tumors in our study. The variable results of ADC cut-off values between literature and our study may be due to the technical factors, selected study population and variable sample size. Although, quantitative potential of ADC increases the attention of DWI in PC, the variable cut-off values limit its usage in the determination of aggressiveness of PV prior to surgery.

Our study had some limitations. The study design was retrospective. The study sample size was small. The pathological results were obtained from TRUS-guided systematic

prostate biopsy whereas the use of GS following radical prostatectomy may increase the accuracy of results.

### Conclusion

The ADC values may differentiate the high-risk and low-risk tumors prior to radical

prostatectomy. The prediction potential of ADC in intermediate-risk tumors was not significant. The ADC cut-off value of  $665 \times 10^{-6} \text{ mm}^2/\text{s}$  showed the high sensitivity and moderate specificity for the discrimination of low-risk tumors

### REFERENCES

1. Barentsz JO, Richenberg J, Clements R, Choyke P, Verma S, Villeirs G, Rouviere O, Logager V, Fütterer JJ, European Society of Urogenital Radiology. ESUR Prostate MR Guidelines 2012. *Eur Radiol* 2012; 22: 746-57.
2. American College of Radiology. Prostate Imaging Reporting and Data System version 2. [www.acr.org/Quality-Safety/Resources/PIRADS](http://www.acr.org/Quality-Safety/Resources/PIRADS). Published 2015.
3. Purysko AS, Bittencourt LK, Bullen JA, Mostardeiro TR, Herts BR, Klein EA. Accuracy and Interobserver Agreement for Prostate Imaging Reporting and Data System, Version 2, for the Characterization of Lesions Identified on Multiparametric MRI of the Prostate. *AJR Am J Roentgenol*. 2017; 209(2): 339-349.
4. Turkbey B, Rosenkrantz AB, Haider MA, Padhani AR, Villeirs G, Macura KJ, Tempany CM, Choyke PL, Cornud F, Margolis DJ, Thoeny HC, Verma S, Barentsz J, Weinreb JC. Prostate Imaging Reporting and Data System Version 2.1: 2019 Update of Prostate Imaging Reporting and Data System Version 2. *Eur Urol*. 2019; 76(3): 340-351.
5. Meng L, Ma P. Apparent diffusion coefficient value measurements with diffusion magnetic resonance imaging correlated with the expression levels of estrogen and progesterone receptor in breast cancer: A meta-analysis. *J Cancer Res Ther*. 2016; 12: 36-42.
6. Shin HJ, Kim HH, Shin KC, et al. Prediction of low-risk breast cancer using perfusion parameters and apparent diffusion coefficient. *Magn Reson Imaging*. 2016; 34: 67-74.
7. Woo S, Kim SY, Cho JY, Kim SH. Preoperative Evaluation of Prostate Cancer Aggressiveness: Using ADC and ADC Ratio in Determining Gleason Score. *AJR Am J Roentgenol*. 2016; 207(1):114-20.
8. Hambrock T, Hoeks C, Hulsbergen-van de Kaa C, et al. Prospective assessment of prostate cancer aggressiveness using 3-T diffusion weighted magnetic resonance imaging-guided biopsies versus a systematic 10-core transrectal ultrasound prostate biopsy cohort. *Eur Urol* 2012; 61: 177-84.
9. Surov A, Meyer HJ, Wienke A. Correlations between Apparent Diffusion Coefficient and Gleason Score in Prostate Cancer: A Systematic Review. *Eur Urol Oncol*. 2020; 3(4): 489-497.
10. Faletti R, Battisti G, Discalzi A, Grognaudi ML, Martinello S, Oderda M, Gontero P, Bergamasco L, Cassinis MC, Fonio P. Can DW-MRI, with its ADC values, be a reliable predictor of biopsy outcome in patients with suspected prostate cancer? *Abdom Radiol (NY)*. 2016; 41(5): 926-33.
11. Pepe P, D'Urso D, Garufi A, Priolo G, Pennisi M, Russo G, Sabini MG, Valastro LM, Galia A, Fraggetta F. Multiparametric MRI Apparent Diffusion Coefficient (ADC) Accuracy in Diagnosing Clinically Significant Prostate Cancer. *In Vivo*. 2017; 31(3): 415-418.
12. Alessandrino F, Taghipour M, Hassanzadeh E, Ziaei A, Vangel M, Fedorov A, Tempany CM, Fennesy FM. Predictive role of PI-RADSv2 and ADC parameters in differentiating Gleason pattern 3+4 and 4+3 prostate cancer. *Abdom Radiol (NY)*. 2019; 44(1):279-285.
13. Lebovici A, Sfrangeu SA, Feier D, et al. Evaluation of the normal-to-diseased apparent diffusion coefficient ratio as an indicator of prostate cancer aggressiveness. *BMC Med Imaging* 2014; 14:15 13.
14. Itatani R, Namimoto T, Yoshimura A, et al. Clinical utility of the normalized apparent diffusion coefficient for preoperative evaluation of the aggressiveness of prostate cancer. *Jpn J Radiol* 2014; 32:685-691

Corresponding author e-mail: sehnazce@yahoo.com

Orcid ID:

Şehnaz Tezcan 0000-0001-7204-3008

Funda Ulu Öztürk 0000-0003-2782-2824

Doi: 10.5505/aot.2023.81488