

## Interatrial septal mass

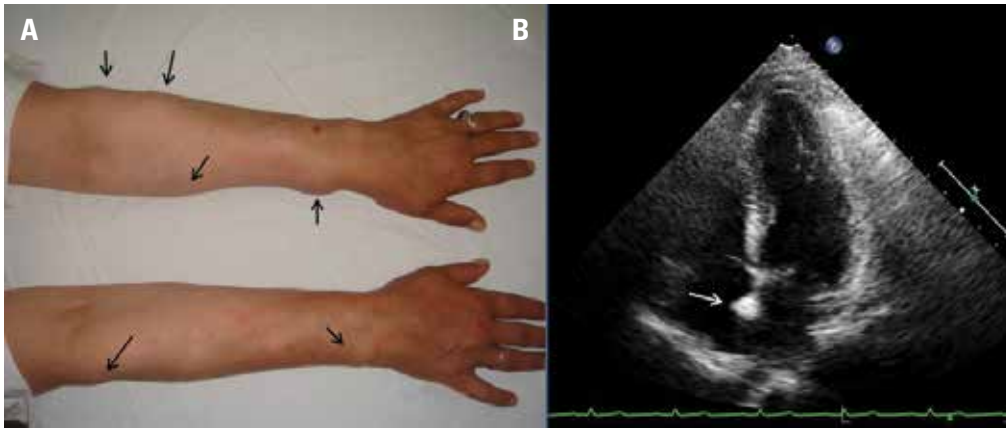
### *İnteratriyal septal kitle*

A 47-year-old female patient was referred to our clinic, because of her atrial arrhythmia detected at her check-up. Her medical history revealed surgical excisions for multiple lipomas at her both upper extremities. Physical examination showed multiple lipomas at her upper extremities (Fig. 1A). The electrocardiogram (ECG) showed sinus rhythm with premature atrial complexes and 48 hours Holter monitoring did not show any other findings. On transthoracic echocardiography (TTE), left ventricular systolic functions were normal, and there was trace

mitral valve regurgitation but interestingly there was a 12x8 mm hyperechoic mass on interatrial septum (Fig. 1B).

#### What is your diagnosis?

1. Myxoma
2. Lipomatous hypertrophy
3. Rhabdomyoma
4. Lipoma



**Figure 1. A) Multiple lipomas (thin black arrows) are seen in both upper extremities. B) Transthoracic apical 4-chamber view shows a hyperechoic mass (thin white arrow) in the interatrial septum**

Answer: p. 621

**Address for Correspondence/Yazışma Adresi:** Dr. Ahmet Güler, Koşuyolu Kalp Eğitim ve Araştırma Hastanesi, Kardiyoloji Kliniği, Kartal, İstanbul-Türkiye Phone: +90 216 459 40 41 E-mail: ahmetguler01@yahoo.com.tr

**Available Online Date/Çevrimiçi Yayın Tarihi:** 10.09.2013

© Telif Hakkı 2013 AVES Yayıncılık Ltd. Şti. - Makale metnine [www.anakarder.com](http://www.anakarder.com) web sayfasından ulaşılabilir.

© Copyright 2013 by AVES Yayıncılık Ltd. - Available on-line at [www.anakarder.com](http://www.anakarder.com)

doi:10.5152/akd.2013.223

