

# Myocardial viability testing in patients with severe left ventricular dysfunction by SPECT and PET

*Ciddi sol ventrikül disfonksiyonu olan hastalarda miyokardiyal canlılığın SPECT ve PET ile değerlendirilmesi*

*Mehmet Onur Demirkol*

Department of Nuclear Medicine and Molecular Imaging, V.K.V. American Hospital, İstanbul, Turkey

## ABSTRACT

In this article, the role of nuclear medicine modalities in assessing myocardial viability and risk stratification in patients with advanced left ventricular (LV) dysfunction are reviewed. Diagnosis of reversible LV dysfunction in patients with heart failure is an important clinical issue. Patients with severe LV dysfunction who have viable myocardium are the patients at highest risk because of the potential for ischemia but at the same time benefit most from revascularization. It is important to identify viable myocardium in these patients, and nuclear medicine techniques are an excellent tool for this. Single-photon emission computed tomography (SPECT) in combination with myocardial perfusion tracers plays an important role in the identification of tissue viability in myocardial segments. Imaging with positron emission tomography (PET) tracers allow the assessment of physiologic processes such as myocardial oxygen consumption, metabolic rate of glucose utilization, and myocardial blood flow. Metabolic imaging with PET offers regional tissue viability in patients with advanced coronary artery disease and severely impaired LV function. (*Anadolu Kardiyol Derg 2008; 8: Suppl 2; 60-70*)

**Key words:** Myocardial viability, left ventricular dysfunction, single-photon emission computed tomography, positron emission tomography

## ÖZET

Bu derlemede ileri sol ventrikül disfonksiyonlu hastalarda, miyokard canlılığı değerlendirmesi ve risk sınıflamasında nükleer tıp yöntemlerinin rolü gözden geçirilmektedir. Kalp yetersizliği olan hastalarda, geri dönebilir sol ventrikül disfonksiyonunun teşhisi önemli bir klinik konudur. Canlı miyokard olan ciddi sol ventrikül disfonksiyonlu hastalar, iskemi potansiyeli nedeni ile en yüksek risk taşıyan hastalardır ama aynı zamanda revaskularizasyondan en fazla yarar görürler. Bu hastalarda miyokard canlılığının belirlenmesi çok önemlidir ve bunun için nükleer tıp teknikleri mükemmel bir araçtır. Tek foton emisyon bilgisayarlı tomografisi (SPECT) ile kombine miyokardiyal perfüzyon ajanları; miyokardiyal segmentlerde canlı dokunun tanımlanmasında çok önemli rol oynamaktadırlar. Pozitron emisyon tomografisi (PET) ajanları; miyokardiyal oksijen tüketimi, glikoz kullanımının metabolik hızı ve miyokardiyal kan akımı gibi fizyolojik olayların değerlendirilmesine olanak sağlamaktadır. Pozitron emisyon tomografisi ile metabolik görüntüleme, ileri koroner arter hastalığı ve sol ventrikül fonksiyonu ciddi derecede bozulmuş hastalarda bölgesel doku canlılığını ortaya koyar. (*Anadolu Kardiyol Derg 2008; 8: Özel Sayı 2; 60-70*)

**Anahtar kelimeler:** Miyokardiyal canlılık, sol ventrikül disfonksiyonu, tek-foton emisyon bilgisayarlı tomografi, pozitron emisyon tomografisi

## Introduction

The prevalence of left ventricular (LV) dysfunction and resultant heart failure is increasing in industrialized countries. Two thirds of cases of left ventricular dysfunction are the result of coronary artery disease (CAD) (1).

Not only are these patients at high risk for subsequent cardiac death, severe morbidities, and recurrent hospitalizations for congestive heart failure, they also frequently have severe limitations in their lifestyles and well-being.

Although there have been significant advances in medical therapy for LV dysfunction and resulting symptoms of heart

**Address for Correspondence/Yazışma Adresi:** Doç. Dr. Mehmet Onur Demirkol, V.K.V. Amerikan Hastanesi Nükleer Tıp ve Moleküler Görüntüleme Bölümü  
Güzelbahçe Sok. No:20 34365 Nişantaşı, İstanbul, Türkiye Phone: +90 212 444 37 77 / Ext.: 25 80-25 82 E-mail: onurd@amerikanhastanesi.org

©Telif Hakkı 2008 AVES Yayıncılık Ltd. Şti. - Makale metnine [www.anakarder.com](http://www.anakarder.com) web sayfasından ulaşılabilir.  
©Copyright 2008 by AVES Yayıncılık Ltd. - Available on-line at [www.anakarder.com](http://www.anakarder.com)

failure, the prognosis from heart failure remains extremely poor, with an annual mortality ranging from 10% to 50% per year (2). The total number of deaths has risen 148% between 1979 and 2000 (3). Many of these patients had previous myocardial infarctions, the extent of remaining viable tissue is of clinical interest, and also related to prognosis (4).

The need for making the diagnosis of resting ischemia, hibernation, or stunning stems from their role in exacerbating LV dysfunction, heart failure symptoms sudden death, hemodynamic deterioration and from the need to decide between revascularization and cardiac transplantation.

Several clinical studies have shown that myocardial dysfunction in patients with CAD may be reversible (5). After an initial ischemic injury, various processes can occur that lead to LV dysfunction, including LV remodeling, impairment of energetics, myocyte dysfunction, and cell death via necrosis and/or apoptosis. Other than cell death, these processes are, to an extent, reversible, and LV function often can be improved, resulting in better patient outcome. Although medical therapy can be extremely beneficial, revascularization in the appropriate patient often is the best therapy (6)

Left ventricular dysfunction, in some cases, is the result of "stunned myocardium," which is defined as myocardium that has become dysfunctional because of a transient coronary occlusion, has been salvaged by coronary reperfusion, yet exhibits prolonged but transient postischemic dysfunction, lasting hours to weeks (7). Thus, in myocardial stunning, blood flow has been restored but contraction has not returned to baseline, i.e., there is a flow-contraction mismatch.

Left ventricular dysfunction, in other cases, is the result of "hibernating myocardium". Rahimtoola et al. (8), introduced this term to refer to persistent LV dysfunction in the presence of severe CAD that is reversible after revascularization. The pathophysiology underlying these phenomena is thought to reflect the down-regulation of function in the presence of reduced blood flow and oxygen supply (8, 9). By this definition, hibernating myocardium is a flow-contraction match. Some investigators contend that hibernating myocardium is actually a manifestation of repetitive myocardial stunning (10). Table 1 summarizes different properties of stunned and hibernating myocardium.

Regardless of the mechanism, it is important to identify hibernating myocardium because ventricular function will generally improve after revascularization or other therapies.

**Table 1. Properties of different myocardial viability patterns**

	<b>Hibernation</b>	<b>Stunning</b>
MPS (uptake)	> %50	Normal
Blood flow	Diminished	Normal
Wall motion	Abnormal	Abnormal
FDG uptake	+	+
Fatty acid metabolism	+	+
Response to catecholamines	+	+
Oxygen consumption	Diminished	Normal or increased
<small>FDG-fluorodeoxyglucose MPS-myocardial perfusion scintigraphy</small>		

## Clinical importance of identifying viable myocardium in patients with severe left ventricular dysfunction

Patients with depressed LV systolic function have a worsened prognosis. In the CASS (Coronary Artery Surgery Study) registry, for the cohort of patients treated with medical therapy, those with a LV ejection fraction (EF) of 50% or greater had a 10-year survival of approximately 90%, compared with a survival of 60% for those with an EF of 35% to 49%, and a survival of 30% for those with an EF less than 35% ( $p<0.001$ ) (11). Publications have consistently shown that among patients with abnormal LV systolic function, those with hibernating myocardium, have the poorest prognosis if they are not referred for a revascularization procedure.

For example, Di Carli et al. (12) performed positron emission tomography (PET) imaging on 93 consecutive patients with coronary artery disease and a mean LV EF of 25%. Medically treated patients who had PET evidence of myocardial viability had markedly lower annual survival of 50%, compared with 92% for patients without evidence of viability ( $p=0.007$ ). Patients with evidence of myocardial viability who underwent revascularization had a higher survival rate than those treated medically (88% versus 50%,  $p=0.03$ ) (12).

In a meta-analysis of 3088 patients with decreased EF who underwent a viability study using a variety of methods, Allman et al. reported that the yearly death rate for patients with viability who were treated medically was 16%, compared with 3.2% for patients who underwent revascularization ( $p<0.0001$ ) (13). Revascularization improved survival for patients with viable myocardium by 79.6%. This pattern maintained regardless of the technique that was used to assess myocardial viability. Conversely, for patients without viable myocardium, there was a trend toward increased mortality in patients who underwent revascularization, 7.7% versus 6.2% ( $p=0.23$ ) (13).

Haas et al. (14) studied 76 patients with advanced LV dysfunction who were being considered for coronary bypass surgery. Compared with patients who were first evaluated for viability with PET imaging, patients sent to surgery who did not have a viability assessment had a significantly worsened postoperative course, including a lower 12-month survival rate, 79% versus 97% ( $p=0.01$ ). This study concluded that the forgoing of a viability study resulted in too many high-risk patients without viability being sent for bypass surgery, resulting in a worsened prognosis (14).

Schinkel et al. (15) evaluated multiple imaging techniques in assessment of myocardial viability in patients with heart failure. They reported, in general, nuclear imaging techniques have a high sensitivity for the detection of viability, whereas techniques evaluating contractile reserve have a somewhat lower sensitivity and a higher specificity. Patients with a substantial amount of dysfunctional but viable myocardium are likely to benefit from coronary revascularization and may show improvements in regional and global contractile function, symptoms, exercise capacity, and long-term prognosis (15).

## SPECT Perfusion Tracers

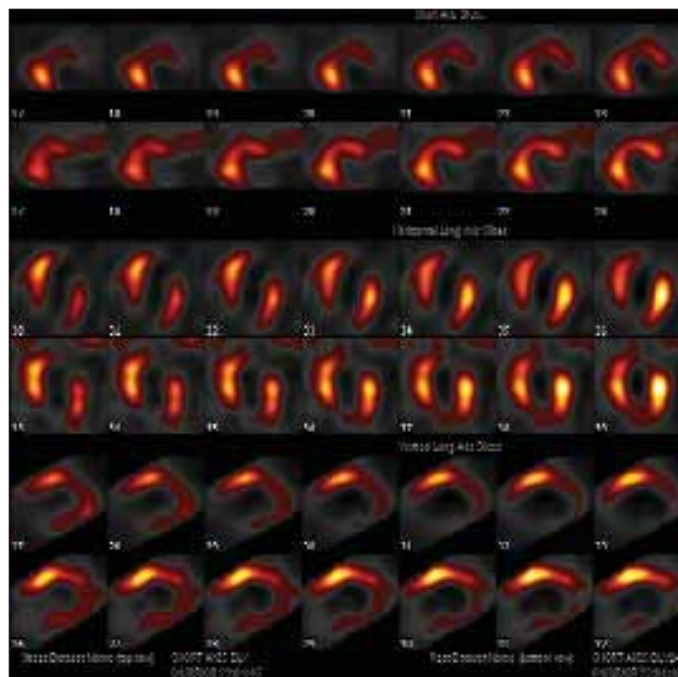
### Thallium-201 imaging

There are numerous methods proposed to assess myocardial viability with thallium-201 (Tl-201), a radionuclide tracer that assesses not only myocardial perfusion but also myocyte cell membrane integrity. Bax et al. (16) analyzed 33 studies with over 800 patients in a meta-analysis and found that Tl-201 imaging using rest and stress protocols had a sensitivity of 86% and a specificity of 59% in predicting functional recovery following revascularization. The relatively low specificity may reflect the criteria used to classify viability as well as the protocol of data acquisition. In addition, a patient may have sufficient myocardial viability in a region to benefit prognostically with revascularization without necessarily being accompanied by an improvement in ventricular systolic function.

In 1976, Pohost et al. (17) first describe the use of Tl-201 redistribution as marker of viable tissue. Some investigators proposed to monitor the redistribution process over prolonged time periods. Gutman et al. (18) reported that in the presence of severe stenoses, defects that appeared fixed at 3 to 5 hours often displayed redistribution after 24 hours. Kiat et al. (19) demonstrated subsequently that the redistribution pattern at 24 hours is more predictive for tissue recovery after revascularization than 3- to -4-hour data.

Although the presence of redistribution has been shown to serve as specific marker of viability, the absence of redistribution at 3 to 4 hours after tracer injection does not rule out tissue viability. Because the quality of 24-hour delayed images often is poor as a result of low counts, a new method of viability assessment was sought (2). In 1990, Dilsizian et al. reported on the technique of Tl-201 reinjection (20). In patients with fixed defects or redistribution images, immediately following acquisition of the delayed images, an additional dose of Tl-201 was injected at rest. It was observed that 49% of irreversible defects demonstrated normal thallium uptake after the second injection of thallium (Fig. 1). Of myocardial segments with defects on redistribution images that were identified as viable by reinjection studies, 87% had normal thallium uptake and improved regional wall motion after angioplasty. Further studies by the Bonow et al. (21) indicated that Tl-201 reinjection imaging has a much greater concordance with Fluorine-18-fluorodeoxy-glucose (FDG) PET imaging than does conventional Tl-201 redistribution, indicating a higher sensitivity for tissue viability by the reinjection procedure. In this study, 88% of viable segments by Tl-201 reinjection protocols were also viable based on the FDG-PET studies (21).

Stress perfusion imaging may not be necessary in patients with known CAD who are scheduled for viability studies. Therefore, a number of investigators evaluated the value of rest-delayed thallium imaging as the preferred method for assessing regional tissue viability. In a group of 26 patients with LV dysfunction, Iskandrian et al. found that 12 of 16 patients with normal or transient thallium defects showed improved ventricular function after surgery, whereas 2 out of 10 patients with fixed defects demonstrated some degree of functional recovery (22).



**Figure 1. Rest-reinjection Tl-201 SPECT imaging in a patient with severe heart failure and severe left ventricular dysfunction (ejection fraction, 32%). After reinjection, there is increased thallium uptake in anterior, antero-septal and antero-lateral segments (viable). There is no change apex, inferior and infero-lateral segments (nonviable).**

The usefulness of rest-redistribution thallium imaging in identifying myocardial viability was further supported by Ragosta et al, who studied 21 patients with severely depressed LV function (mean EF=27%) who subsequently underwent bypass surgery (23). Myocardial segment viability was assessed both by quantitative analysis of defect severity and the presence of redistribution. Overall, 62% of severely asynergic segments with normal viability and 54% with mildly reduced viability improved function after surgery, compared with only 23% that had severely reduced viability ( $p=0.002$ ). There was viability in 7 or more of the 15 segments analyzed, mean LVEF increased significantly after bypass surgery.

Besides the predictive value of thallium imaging for tissue recovery after revascularization, the prognostic value of this imaging approach for long-term clinical outcome was investigated by Pagley et al. (24). Seventy patients with multi-vessel CAD and severe LV dysfunction (EF <40%) were imaged prior to bypass surgery. Following surgery, event-free survival was compared in patients with viable versus nonviable revascularized tissue. Patients with a myocardium at least about two thirds viable as measured by a semi-quantitative index had significantly improved 3- year event-free survival as compared with patients who had less viable tissue (24, 25). Thus, rest-delayed thallium imaging can help identify patients who are likely to benefit from bypass surgery.

There are conflicting data in the literature regarding whether defect reversibility or thallium uptake of 50% or greater of peak counts is the best indicator of viability. In a study of 35 patients with LV dysfunction, Sciagra et al. found that tracer activity in a delayed thallium image was important than defect reversibility

for myocardial viability (26). In contrast, Kitsiou et al. showed that reversible defects more accurately predict functional recovery after revascularization than fixed defects with similar resting tracer activity (27).

For revascularization to improve ventricular function, the ventricle must be ischemic from a stenosis in the artery perfusing the dysfunctional territory (s), and this situation is best depicted by defect reversibility (2). For example, a myocardial region that is dysfunctional from myocardial damage after a non-ST segment elevation infarction and is perfused by a nonstenotic vessel may show sufficient tracer uptake on resting thallium imaging to indicate viability, but will not show improved function after revascularization. In another setting, ventricular contraction may be depressed because of cellular dysfunction related to a cardiomyopathy, in which case one might see satisfactory myocardial thallium uptake, but revascularization would not be expected to improve function. The situation becomes particularly complex in patients who may have both CAD and nonischemic cardiomyopathy, such as diabetics. In these instances, a rest / delayed thallium imaging study may be insufficient, and additional imaging with stress may be needed to identify the presence of myocardial ischemia to decide on revascularization (28). In fact, there is little lost by performing stress/ rest-redistribution studies in all patients sent for assessment of myocardial viability as this will not only provide information regarding viability but also provide an assessment of exercise or pharmacologic induced ischemia (2).

In addition to, an elevated TI-201 lung uptake after stress is related to an adverse prognosis. Marcassa et al. (29) found that in patients with severe postischemic LV dysfunction undergoing rest-redistribution thallium imaging, an increased lung tracer uptake showed incremental prognostic value over clinical and other imaging findings, providing clinically useful risk assessment.

## Technetium-99m perfusion tracers

The vulnerability of TI-201 to attenuation artifacts caused by the relatively lower energy of emitted photons and lower count rates caused by the dose constraints may result in poor or suboptimal images in a significant proportion of studies. Compared with TI-201, technetium-99m (Tc-99m) yields relatively higher energy photons and can be used in much higher doses (30). However, the first-pass extraction fraction of Tc-99m sestamibi and Tc-99m tetrofosmin is lower than that of TI-201 (30). This may be a limitation for the assessment of perfusion at high flow rates but does not effect resting tracer distribution necessary for viability studies. Both Tc-99m labeled tracers are retained in viable myocardium for prolonged time periods (31). Tc-99m sestamibi shows some redistribution in animal studies, which at best is minimal and clinically unimportant in human studies (32).

Myocardial TI-201 uptake occurs through ATPase dependent  $Na^+ / K^+$  channels. The cellular uptake of all cationic Tc-99m perfusion agents is similar and is independent of  $Na^+ / K^+$  channels. This is mediated by a nonspecific charge dependent transfer of lipophilic cations across the sarcolemma. The uptake of cationic agents is dependent on their lipophilicity. However, requirement of cellular metabolic activity rules out lipophilicity alone as the mechanism for cellular uptake of these tracers. Inside the myocytes, the mitochondria are the predominant site of localization of these cationic agents. Mitochondrial localization of Tc-99m cationic appears to be related to a high negative charge (-165 mV) across the mitochondrial membrane compared with other intracellular organelles. Mitochondrial uptake of these agents requires integrity of their oxidative metabolism. These data support a role for Tc-99m cationic agents as a means of assessing myocardial viability (30). Properties of single photon emission computed tomography (SPECT) perfusion agents are summarized in Table 2.

**Table 2. Pharmacokinetics of Thallium-201, Tc-99m Sestamibi, and Tc-99m Tetrofosmin**

	<b>Thallium-201</b>	<b>Tc-99m sestamibi</b>	<b>Tc-99m tetrofosmin</b>
Chemical class/charge	Element Cation	Isonitrit cation	Diphosphine cation
Mechanism of uptake	Active transport Na-K ATPase pump	Passive diffusion Negative electrical potential	Passive diffusion Negative electrical potential
Myocyte localization	Cytosol	Mitochondria	Mitochondria
Intracellular state	Free	Bound	Bound
Preparation	Cyclotron	Generator/kit	Generator/kit
First pass extraction fraction	85%	60%	50%
Percent cardiac uptake	3%	1.5%	1.2%
Myocardial clearance	4 hr $T_{1/2}$	Minimal	Minimal
Body clearance	Renal	Hepatic	Hepatic
Imaging time after injection			
Stress	10 min	15-30 min	5-15 min
Rest	3-4 hrs	30-90 min	30 min

## Tc-99m sestamibi imaging

Several studies have shown a relatively good agreement between Tc-99m sestamibi and Tl-201 imaging in the same patients. Initial studies comparing Tc-99m sestamibi with Tl-201 SPECT imaging suggested an underestimation of tissue viability by Tc-99m sestamibi in up to 47% of segments displaying Tl-201 uptake after reinjection (33). Marzullo et al. (34) confirmed these data, reporting a considerable incidence of resting perfusion defects in LV segments with normal resting wall motion but stenosed vascular supply (34).

In contrast, Udelson et al. found that if sestamibi images are interpreted quantitatively, they can predict ventricular function improvement after revascularization. They also observed that uptake of sestamibi paralleled that of Tl-201, 1 hour after a resting tracer injection. The likelihood of tissue viability was inversely related to the defect severity of both tracers (35). Similar findings were reported by Kauffman et al. Patients with a mean LV EF of 33% underwent early and 3 hours delayed rest Tl-201 imaging, and rest Tc-99m sestamibi imaging. Uptake of both tracers were comparable in myocardial zone of asynergy. Defect magnitude, by quantitation, was similar for 2 tracers for regions with both mild and severe reduction in tracer uptake (36).

Medrano et al. (37), compared regional Tc-99m sestamibi distribution in ischemic myopathic heart removed during heart transplantation. Comparison of in vitro determined Tc-99m sestamibi uptake by autoradiography and histology showed good agreement between tracer uptake and tissue viability. Maes et al. (38) prospectively studied thirty patients with CAD and wall motion abnormalities who were referred for bypass surgery. Each patient underwent rest sestamibi imaging and PET imaging with Nitrogen-13 (N-13) ammonia (a flow agent) and FDG (a metabolic agent), as well as transmural biopsy. Significantly higher sestamibi uptake was found in patients with evidence of viability by PET than in those without. There was a linear relation between sestamibi uptake and fibrosis in the biopsy specimen.

Liu et al. (39) evaluated Tc-99m sestamibi kinetics predict myocardial viability in a perfused rat heart model. They reported that Tc-99m sestamibi myocardial activity is significantly reduced in areas of nonviability after 1 h of tracer uptake and 1 h of tracer clearance. There is a linear correlation between myocardial viability, and tracer activity.

Siebelink et al. (40) performed a prospective, randomized study in 103 patients comparing Tc-99m sestamibi SPECT and FDG / ammonia - PET for the management of advanced CAD. The imaging resulted in comparable patient management and event-free survival after revascularization independently of the use of PET and SPECT (40). However, LV EF was less than 30% in only one third of the patients.

Bax et al. (16) summarized 20 viability studies using Tc-99m sestamibi in 488 patients and reported an average sensitivity of 81% and an average specificity of 66%, resulting in a positive and negative predictive value of 71% and 76%, respectively. Most of these studies used a semiquantitative threshold of tracer uptake between 50% and 60% (16).

Sometimes combining stress sestamibi with rest / delayed thallium imaging, in a dual-isotope protocol, can provide a comprehensive assessment of the entire clinical problem. The extent of reversible defects on the stress sestamibi images can assess the myocardial ischemia, while the rest / delayed thallium images can provide additional information on myocardial viability (2). In the case of advanced CAD and severe LV dysfunction, the waiting period for delayed thallium imaging can be prolonged to optimize the viability information.

## Pharmacological interventions for viability

Investigations proposed the use of nitrates prior the injection of sestamibi in order to enhance viability information. Nitrates may affect the blood flow pattern by improving trans-stenotic and collateral blood flow to hypoperfused segments (41). The use of this pharmacological intervention results in smaller Tc-99m sestamibi perfusion defects, increasing the sensitivity for detecting viable myocardium. Several protocols of nitrate administration (sublingual, oral, infusion of nitrates) have been proposed, and these have yielded results similar to those achieved with Tl-201 viability imaging.

Bisi et al. (42) demonstrated that LV segments, which improved after revascularization, had a 37% decrease of rest perfusion defect size following nitrate application. Sciagra et al. (26) observed that nitrate enhanced sestamibi imaging was at least as good as rest / redistribution thallium in detecting viable myocardium and predicting post-revascularization recovery. In the meta-analysis by Bax et al. (16), defect reversibility after nitrate-enhanced sestamibi imaging yielded a sensitivity of 86% and a specificity of 83% in predicting myocardial viability.

Acampa et al. (43) reported that the presence of viable myocardium at nitrate sestamibi SPECT imaging predicts major cardiac events at long-term follow-up and the risk increases with the extent of viability.

Another method to enhance the ability of sestamibi imaging to detect viability is concomitant assessment of ventricular function using gated SPECT imaging. Iskandrian et al. (44) described acquiring gated SPECT images at baseline and during low dose dobutamine infusion, looking not only at tracer uptake, but also at changes in wall motion to assess contractile reserve.

Administration of trimetazidine, an agent that improves mitochondrial metabolism, before injecting sestamibi also has been shown to enhance tracer uptake in the dysfunctional but viable myocardium (45).

## Tc-99m tetrofosmin imaging

Given its similarity to Tc-99m sestamibi, one would not expect important differences in using Tc-99m tetrofosmin to evaluate myocardial viability in patients with LV dysfunction. Matsunari et al. (46) reported that myocardial tetrofosmin uptake correlated well with thallium uptake on rest delayed images. Gunning et al. (47) found that tetrofosmin imaging was similar to thallium and dobutamine magnetic resonance imaging (MRI) in predicting

post-revascularization functional recovery. He et al. (48) reported that rest uptake of tetrofosmin in dysfunctional myocardial segments, after administration of sublingual nitrate, correlated with metabolic activity as assessed by FDG. Recently, Giorgetti et al. compared nitrate-enhanced Tc-99m tetrofosmin SPECT with contrast-enhanced MRI (49). The correlation of nitrate-enhanced SPECT images with contrast-enhanced MRI was significantly better than without nitrates. Stollfuss et al. (50) showed that the sensitivity for predicting functional recovery after revascularization assessed by MRI by Tc-99m tetrofosmin SPECT can be improved to 86%, including functional information.

Morishima et al. (51) evaluated risk stratification of patients with prior MI and advanced LV dysfunction by gated Tc-99m tetrofosmin myocardial perfusion SPECT imaging. Their results show that perfusion defect volume by Tc-99m tetrofosmin gated SPECT is the most pivotal predictor of the future occurrence of lethal arrhythmic events and of sudden cardiac death (51).

### Positron emission tomography

Another strategy for assessment of viability is the addition of metabolic imaging to perfusion imaging using analogues of either glucose or free fatty acids imaging. Under aerobic conditions, the heart uses predominantly fatty acids, but after carbohydrate loading, the inhibitory effect of insulin on release of fatty acids from adipocytes diminishes circulating fatty acids and up-regulates glucose use by the heart. Injured myocardium frequently demonstrates impaired oxidative metabolism, impaired free fatty acid utilization, and an excess of glucose utilization relative to flow (2).

F-18-fluorodeoxy-glucose (FDG) is an analogue of glucose, which is transported into cells via a specific glucose membrane transporter and is phosphorylated by hexokinase. Unlike glucose, FDG is trapped and is not metabolized further. Its accumulation is an index of glucose utilization (52).

Myocardial flow can be imaged with N-13 ammonia, oxygen-15 (O-15) water or rubidium-82 chloride (Rb-82) (Table 3). Oxygen-15 water represents a freely diffusible tracer that washes in and out of myocardial tissue as a function of blood flow. The first-pass extraction of O-15 water in the heart is not diffusion limited, nor is O-15 water tissue extraction affected by any metabolic pathways. The second group of flow markers is radiotracers retained in myocardial tissue proportional to myocardial blood flow. For these radiopharmaceuticals, the initial tracer extraction (first-pass extraction) and their tissue

retention are important factors defining their suitability as blood flow tracers. N-13 ammonia is highly extracted by myocardial tissue in the form of N-13 ammonia. Within the tissue, the tracer can either back-diffuse into the vascular space or be trapped in the form of N-13 glutamine. Rb-82 displays tracer kinetics similar to those of Tl-201. Initial extraction of this compound ranges from 50% to 70%. For both N-13 ammonia retention and Rb-82 chloride extraction, a nonlinear relationship exists between blood flow and tissue tracer extraction (53).

Positron emission tomography has been considered "gold standard" for assessment of myocardial viability using metabolic tracers. The PET criteria of myocardial viability or non-viability are shown in Table 4. With the use of metabolic tracers, several patterns of metabolism can be delineated in combination with knowledge of both perfusion and assessment of regional function to classify myocardium. Normal tissue shows normal function, perfusion and metabolism. Stunned myocardium shows diminished function, preserved flow, and either matched or excessive FDG accumulation. Hibernation has been shown to demonstrate decreased perfusion and function, and relatively preserved or disproportionately increased FDG accumulation. Infarcted myocardium shows a matched decrease in perfusion, function and metabolism (2).

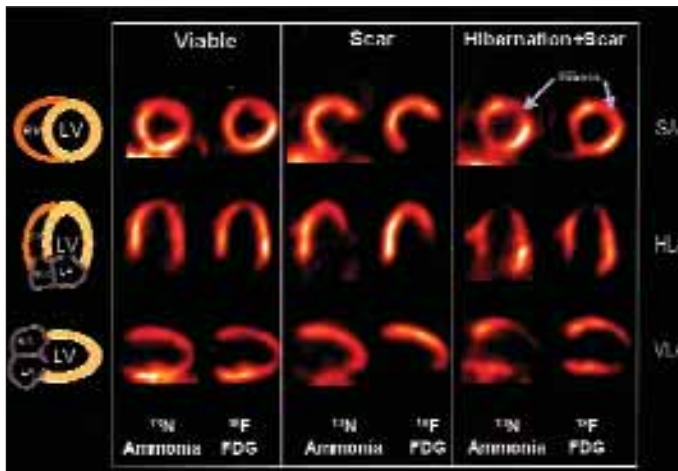
By using information on both blood flow and glucose metabolism, sensitive and specific identification of viable or non-viable myocardium can be performed (Fig. 2). This was first shown by Tillisch et al., who compared relative FDG uptake in patients with advanced CAD and impaired regional and global function before and after revascularization (54). Their study demonstrated that maintained FDG uptake in dysfunctioning segments with reduced flow is associated with functional recovery after revascularization, whereas segments with concordantly decreased flow and metabolism do not recover after restoration of blood flow. Imaging with FDG for delineation of viability is superior to that achievable with thallium imaging (55-57). These studies have demonstrated that approximately 30% to 50% of segments failed to represent scar by delayed thallium imaging demonstrate uptake of FDG suggesting viability.

**Table 4. Flow-metabolism patterns in dysfunctional myocardium**

Blood flow	Glucose metabolism	Definition
+	+	Normal
Diminished	+	Mismatch (viability)
Diminished	Diminished	Match (necrosis)

**Table 3. Cardiac positron radiopharmaceuticals**

Mechanism	Radionuclide	Pharmaceutical	Physical Half-life	Production
Perfusion	Nitrogen-13	Ammonia	10 min	Cyclotron
	Rubidium-82	Rubidium	76 seconds	Generator
	Oxygen-15	Water	110 seconds	Cyclotron
Glucose metabolism	Fluorine-18	Fluorodeoxyglucose	110 minutes	Cyclotron
Fatty acid metabolism	Carbon-11	Acetate	20 minutes	Cyclotron
	Carbon-11	Palmitate	20 minutes	



**Figure 2.** Three different patterns of tracer distribution in PET flow and metabolism imaging can be observed, as shown in three representative short- and long-axis images of patients with severely reduced left ventricular function. Within the panels, the NH<sub>3</sub> study is shown on the left and the FDG study on the right. The distinct patterns are maintained NH<sub>3</sub> and FDG uptake (viable), concordant reduction of NH<sub>3</sub> and FDG (scar; here in the inferolateral wall), and decreased flow with maintained FDG uptake (hibernation; here, in the anterolateral wall). (Reproduced from Schwaiger M, Nekolla SG. Coronary artery disease: tissue viability and perfusion. In: Von Schulthess GK, editor. *Molecular Anatomic Imaging. PET-CT and SPECT-CT Integrated Modality Imaging*. Philadelphia, PA: Lippincott Williams & Wilkins; 2007. p. 227-43, with permission of Lippincott Williams & Wilkins, Copyright 2007)

Free fatty acid imaging with Carbon-11 acetate may in fact be more sensitive in assessing viable myocardium compared with FDG (58-60). However, this tracer requires a cyclotron in addition to the assessment of the myocardial kinetics of washout, thereby making this somewhat less useful for most centers.

A single photon congener,  $\beta$ -methyl-p-<sup>123</sup>I-iodophenyl-pentadecanoic acid (BMIPP), has been used for identification of viable myocardium (61).

Di Carli et al. (62) demonstrated that size of the PET defect representative of hibernating myocardium was predictive of the functional recovery after revascularization. This is important because patients that have the poorest ventricular function are most at risk for perioperative morbidity or mortality but also are those that typically show the most improvement when they undergo revascularization. Analysis of data of patients shows that global LV function increases significantly after revascularization in patients with viable myocardium based on PET (56, 63).

Slart et al. (64) reported that N-13 ammonia PET showed a significant increase in nitrate-enhanced blood flow in viable myocardium, whereas blood flow remained unchanged after nitrate administration in nonviable myocardium similar Tc-99m-labeled perfusion agents.

In all studies, recovery of regional function after revascularization served as the gold standard for tissue viability. However, the criteria of viability have not yet been standardized and vary from study to study. Bax et al. (65), compared the diagnostic performance of various viability tests: PET proved to be the most sensitive method, whereas methods assessing contractile performance displayed greater specificity for wall

motion recovery. This finding is not surprising, because the gold standard for functional recovery may underestimate the presence of viable myocardium, especially in the epicardium. Revascularized segments with subendocardial infarction may show only little functional recovery but may benefit from improved oxygen supply, especially during stress to viable epicardial layers.

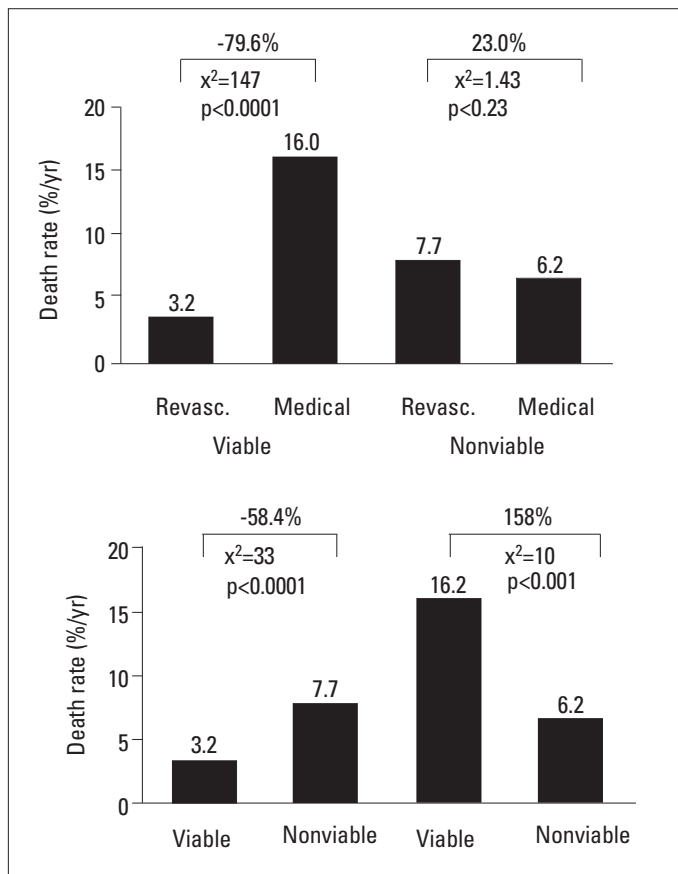
### Prognostic role of PET imaging

Positron emission tomography also has been shown to have important prognostic implications based on the findings of viable versus nonviable myocardium. Patients who are identified as having scar based on PET who do not undergo revascularization have a 14% 1-year incidence of major adverse cardiac events compared with a 7% incidence in patients with scar who underwent revascularization. In contrast, patients with viable myocardium based on PET who did not undergo revascularization had a 1-year event rate of 47%, which was markedly reduced (to 11%) if patients underwent revascularization (56, 65-71). This is despite the fact that studies were performed in patients with very severe LV dysfunction. For example, in the study of Rohatgi et al., the pre-PET mean EF was 22% (56).

These data indicate that the mismatch pattern identifies a subgroup of patients at increased risk for cardiovascular complications. The prognostic information appears independent of the traditional markers, such as LV EF or the New York Heart Association (NYHA) classification, which were not different among the investigated subgroups. Survival was significantly higher in revascularized patients with mismatch.

DiCarli (7) reviewed PET studies comparing both therapy strategies in patients with mismatch. As shown in Figure 3, mismatch pattern was associated with a significantly better survival in all patient cohorts (71). Patients with severe LV dysfunction are at higher risk for complications associated with revascularization.

Dreyfus et al. (72) reported that the assessment of tissue viability in such patients before surgery improves the selection process for revascularization, with low perioperative mortality. Haas et al. confirmed this prognostic role for PET by comparing short-term and midterm survival after surgical revascularization in two groups of patients with three-vessel disease and impaired LV function (73). Whereas one group of patients was selected for surgery based on angiographic and clinical data, the second group consisted of patients selected based on evidence of tissue viability by PET. The latter group had significantly lower incidence of short-term and mid-term complications as well as significantly lower hospital mortality. The prediction of low perioperative complications is an important aspect in the selection process of patients with low LVEF for surgical revascularization, because the reported perioperative mortality of unselected patients averages around 10%. They also reported a 30-day hospital mortality of only 1.9% in more than 100 patients with LVEF, with less than 30% undergoing surgery after a PET-based selection process, which compares very favorably with the results in unselected patients.



**Figure 3. Relative risk of cardiovascular events (odds ratio) for patients with moderate to severe left ventricular dysfunction and viable (hibernating) myocardium treated with revascularization compared with medical therapy. (Reproduced from Di Carli MF. Assessment of myocardial viability after myocardial infarction. J Nucl Cardiol 2002; 9: 229-35 with permission of Elsevier, Copyright 2002)**

Tarakji et al. (74) reported that among systolic heart failure patients (LVEF  $\leq$  35%) referred for FDG PET, early intervention may be associated with improved survival irrespective of the degree of viability (74).

Centers that perform heart transplants often use PET to determine those patients in whom coronary artery bypass grafting (CABG) can be performed rather than transplantation. It has been the experience of several centers that approximately 30 to 50% of patients referred for transplantation have hibernating myocardium based on PET (75-77). These patients do well when revascularized.

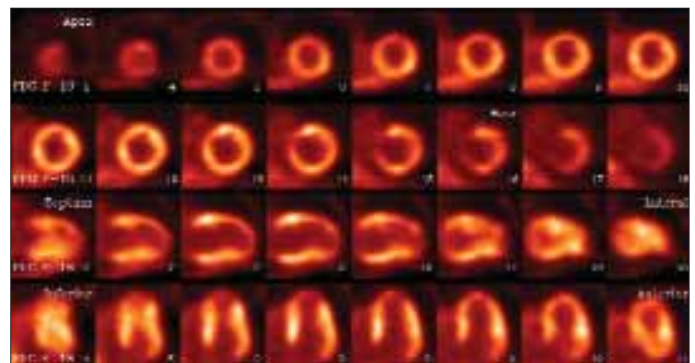
Allman et al. (78) summarized the available prognostic data for viability tests in meta-analysis of 24 studies (more than 3000 patients). In patients with evidence of viability, revascularization was associated with an 80% reduction in annual mortality compared with medical treatment (16% vs. 3.2%). The benefit of revascularization was related to the extent of dysfunction in patients with evidence of viability, indirectly indicating the degree of hibernating myocardium. Patients without evidence of viability in dysfunctional segments did not benefit from revascularization (7.7% vs 6.2% annual mortality with and without revascularization, respectively).

These studies suggest that revascularization brings a survival benefit beyond wall motion enhancement or an increase in LVEF, possibly due to protection against sudden death, or protection from further remodeling and dilatation (Fig. 4). The question of possible survival benefit from CABG even in the absence of an increase in LVEF needs to be ascertained. Some patients with angina undergo CABG even without hope of likely improvement in LVEF (79). Documentation of ischemia in patients with symptoms, or episodes of exacerbation of heart failure and prediction of resolution of ischemic episodes after even limited revascularization, is a desirable aim.

### Future prospects

It is not clear whether improvement of ventricular function, regional or global, is necessary for the patient's benefit. Samady et al. (80) ascertained no difference in survival between ischemic cardiomyopathy patients who did or did not have improved LVEF following bypass surgery. In addition, postoperative improvement in angina and heart failure were similar between the two groups. Thus, even without improvement in ventricular systolic function, there may be important clinical benefits. Preservation of the small areas of viability detected by perfusion imaging techniques may improve clinical outcome by stabilizing the electrical milieu and preventing lethal arrhythmias, by preventing a subsequent myocardial infarction, and by improving symptoms and functional capacity through prevention of deleterious myocardial dilation and remodeling (81). These concepts need further investigation.

With the continued aging of the population and the predicted greater prevalence of patients with chronic diseases such as congestive heart failure and LV dysfunction attributable to CAD, it will become increasingly important to identify patients who will benefit from interventions such as revascularization. It will be important to more accurately identify myocardial viability (2).



**Figure 4. PET/CT findings of the patient with three-vessel coronary artery disease with previous anterior wall myocardial infarction and referred for assessment of viability (ejection fraction, 30%): The anterior wall had good uptake of FDG and that this wall was viable. There was severe reduction of metabolism in the apex (nonviable). The remainder of the left ventricle showed normal metabolism. After coronary bypass surgery, the symptoms of heart failure resolved and the ejection fraction increased to 40%.**



Currently available imaging techniques: stress-delayed, rest-delayed and reinjection thallium imaging, Tc-99m sestamibi imaging, metabolic imaging with PET, dobutamine stress echocardiography, and MRI, are all helpful in making clinical decisions, but all have limitations. Larger, carefully conducted prospective studies will need to be performed to more effectively evaluate the accuracy of various tests alone or in combination, they will need to incorporate newer technologies. The combination of PET and SPECT with computerized tomography will allow establishing of the correlation between coronary anatomy and metabolic imaging, further improving the noninvasive assessment of patients with ischemic heart failure. In addition, newer procedures, such as therapeutic coronary angiogenesis and stem cell repair techniques, may revolutionize the way patients with these types of cardiovascular disease are managed (82, 83).

Nevertheless, one would expect that nuclear medicine techniques will continue to play an important role in assessment of myocardial viability in patients with advanced CAD and severely impaired LV function.

## References

- Gheorgiade M, Bonow RO. Chronic heart failure in the United States. A manifestation of coronary artery disease. *Circulation* 1988; 97: 28-9.
- Travin MI, Bergmann SR. Assessment of myocardial viability. *Semin Nucl Med* 2005; 2: 2-19.
- Deedwania PC. The key to unraveling the mystery of mortality in heart failure. An integrated approach. *Circulation* 2003; 107: 1719-21.
- Bonow RO. Myocardial viability and prognosis in patients with ischemic left ventricular dysfunction. *J Am Coll Cardiol* 2002; 39: 1159-62.
- Wijns W, Vatner SF, Camici PG. Hibernating myocardium. *N Engl J Med* 1998; 339: 173-81.
- Dilsizian V. Myocardial viability: Reversible left ventricular dysfunction. In: Dilsizian V, Narula J, Braunwald E, editors. *Atlas of Nuclear Cardiology*. Philadelphia, PA; Current Medicine: 2003. p.19-46.
- Kloner RA, Bolli R, Marban E, Reinlib L, Braunwald E. Medical and cellular implications of stunning , hibernation, and preconditioning. An NHLBI workshop. *Circulation* 1998; 97: 1848-67.
- Heusch G, Schulz R, Rahimtoola SH. Myocardial hibernation: a delicate balance. *Am J Physiol Heart Cir Physiol* 2005; 288: H984-99.
- Hijssen VL, Borgers Lenders MH, Ramaekers FC, Suzuki G, Palka B, et al. Temporal and spatial variations in structural protein expression during the progression from stunned to hibernating myocardium. *Circulation* 2004; 110: 3313-21.
- Bax JJ, Wahba FF, Van Der Waal EE. Myocardial viability/hibernation. In: Iskandrian AE, Verani MS, editors. *Nuclear Cardiac Imaging*. New York: Oxford University Press; 2003. p 386-98.
- Emond M, Mock MB, Davis KB, Fisher LD, Holmes DR Jr, Chaitman BR. Long-term survival of medically treated patients in the Coronary Artery Surgery Study (CASS) registry. *Circulation* 1994; 90: 2645-57.
- Di Carli MF, Davidson M, Little R, Khanna S, Mody FV, Brunken RC. Value of metabolic imaging with position emission tomography for evaluating prognosis in patients with coronary artery disease and left ventricular dysfunction. *Am J Cardiol* 1994; 73: 527-33.
- Allman KC, Shaw LJ, Hachamovitch R, Udelson JE. Myocardial viability testing and impact of revascularization on prognosis in patients with coronary artery disease and left ventricular dysfunction: A meta-analysis. *J Am Coll Cardiol* 2002; 39: 1151-8.
- Haas F, Haehnel CJ, Picker W, Nekolla S, Martinoff S, Meisner H, et al. Preoperative positron emission tomographic viability assessment and perioperative and postoperative risk in patients with advanced ischemic heart disease. *J Am Coll Cardiol* 1997; 30: 1693-700.
- Schinkel AF, Poldermans D, Elhendy A, Bax JJ. Assessment of myocardial viability in patients with heart failure. *J Nucl Med* 2007; 48: 1135-46.
- Bax JJ, Poldermans D, Elhendy A, Boersma E, Rahimtoola SH. Sensitivity, specificity, and predictive accuracies of various noninvasive techniques for detecting hibernating myocardium. *Curr Probl Cardiol* 2001; 26: 141-88.
- Pohost GM, Zir LM, Moore RH, McKusick KA, Guiney TE, Beller GA. Differentiation of transiently ischemic from infarcted myocardium by serial imaging after a single dose of thallium- 201. *Circulation* 1977; 55: 294-302.
- Gutman J, Berman DS, Freeman M, Rozanski A, Maddahi J, Waxman A, et al. Time to completed redistribution of thallium-201 in exercise myocardial scintigraphy: Relationship to the degree of coronary artery stenosis. *Am Heart J* 1983; 106: 989-95.
- Kiat H, Berman DS, Maddahi J, De Yang L, Van Train K, Rozanski A, et al. Late reversibility of tomographic myocardial thallium- 201 defects an accurate marker of myocardial viability. *Am Coll Cardiol* 1988; 12: 1456-63.
- Dilsizian V, Roccom TP, Freedman NMT, Leon MB, Bonow RO. Enhanced detection of ischemic but viable myocardium by the reinjection of thallium after stress- redistribution imaging. *N Engl J Med* 1990; 323: 141-6.
- Bonow RO, Dilsizian V, Cuocolo A, Bacharach SL. Identification of viable ventricular dysfunction. Comparison of thallium scintigraphy with reinjection and PET imaging with 18 F- fluorodeoxyglucose. *Circulation* 1991; 83: 26-37.
- Iskandrian AS, Hakki A, Kane SA, Goel IP, Mundth ED, Hakki AH, et al. Rest and redistribution of thallium-201 myocardial scintigraphy to predict improvement in left ventricular function after coronary arterial bypass grafting. *Am J Cardiol* 1983; 51: 1312-6.
- Ragosta M, Beller GA, Watson DD, Kaul S, Gimple LW. Quantitative planar rest-redistribution 201 TI imaging in detection of myocardial viability and prediction of improvement in left ventricular function after coronary bypass surgery in patients with severely depressed left ventricular function. *Circulation* 1993; 87: 1630-41.
- Pagley PR, Beller GA, Watson DD, Gimple LW, Ragosta M. Improved outcome after coronary bypass surgery in patients with ischemic cardiomyopathy and residual myocardial viability. *Circulation* 1997; 96: 793-800.
- Sharir T, Berman DS, Lewin HC, Friedman JD, Cohen I, Miranda R, et al. Incremental prognostic value of rest-redistribution (201) TI single-photon emission computed tomography. *Circulation* 1999; 100: 1964-70.
- Sciagra R, Bisi G, Santoro GM, Zeraushek F, Sestini S, Pedenovi P, et al. Comparison of baseline-nitrate technetium-99m sestamibi with rest-redistribution thallium-201 tomography in detecting viable hibernating myocardium and predicting post-revascularization recovery. *J Am Coll Cardiol* 1997; 30: 384-91.
- Kitsion AN, Srinivasan G, Quyyumi AA, Summers RM, Bacharach SL, Dilsizian V. Stress-induced reversible and mild-moderate irreversible thallium defects: Are they equally accurate for predicting recovery of regional left ventricular function after revascularization? *Circulation* 1998; 98: 501-8.
- Klocke FJ, Baird MG, Bateman TM, Berman DS, Carabello BA, Cerqueira MD, et al. ACC/AHA/ASNC guidelines for the clinical use of cardiac radionuclide imaging: a report of the American College of Cardiology/American Heart Association Task Force on Practice Guidelines (ACC/AHA/ASNC Committee to Revise the 1995 Guidelines for Clinical Use of Radionuclide Imaging). (2003). American College of Cardiology Web Site. (accessed 2004 September 30) Available from: URL: <http://www.acc.org/qualityand-science/clinical/guidelines/radio/index.pdf>

29. Marcassa C, Gali M, Baroffio C, Eleuteri E, Campini R, Giannuzzi P. Independent and incremental prognostic value of (201)Tl lung uptake at rest in patients with severe postischemic left ventricular dysfunction. *Circulation* 2000; 102: 1795-801.
30. Jain D. Technetium-99m labeled myocardial perfusion imaging agents. *Semin Nuc Med* 1999; 29: 221-36.
31. Kailasnath P, Sinusas AJ. Comparison of Tl-201 with Tc-99m-labeled myocardial perfusion agents: technical, physiologic and clinical issues. *J Nucl Cardiol* 2001; 8: 482-98.
32. Richter WS, Cordes M, Calder D, Eichstaedt H, Felix R. Washout and redistribution between immediate and two-hour myocardial images using technetium-99 sestamibi. *Eur J Nucl Med* 1995; 22: 49-55.
33. Cuocolo A, Pace L, Ricciardelli B, Chiariello M, Trimarco B, Salvatore M Identification of viable myocardium in patients with chronic artery disease: Comparison of thallium-201 scintigraphy with reinjection and technetium-99m methoxyisobutyl isonitrile. *J Nuc Med* 1992; 33: 505-11.
34. Marzullo P, Sambuceti G, Parodi O. The role of sestamibi scintigraphy in the radioisotopic assessment of myocardial viability. *J Nucl Med* 1992; 33: 1925-30.
35. Udelson JE, Coleman PS, Metherall J, Pandian NG, Gomez AR, Griffith JL, et al. Predicting recovery of severe regional ventricular dysfunction. Comparison of resting scintigraphy with 201 Tl and 99m Tc-sestamibi. *Circulation* 1994; 89: 2552-61.
36. Kaufman GJ, Boyne TS, Watson DD, Smith WH, Beller GA. Comparison of rest thallium-201 imaging and rest technetium-99m sestamibi imaging for assessment of myocardial viability in patients with coronary artery disease and severe left ventricular dysfunction. *J Am Coll Cardiol* 1996; 27: 1592-7.
37. Medrano P, Lowry RW, Young JB, Weilbaecher DG, Michael LH, Afridi I, et al. Assessment of myocardial viability with 99mTc-sestamibi in patients undergoing cardiac transplantation. A scintigraphic/pathologic study. *Circulation* 1996; 94: 1010-7.
38. Maes AF, Borgers M, Flameng W, Nuyts JL, van de Werf F, Ausma JJ, et al. Assessment of myocardial viability in chronic coronary artery disease using technetium-99m sestamibi SPECT. *J Am Coll Cardiol* 1997; 29: 62-8.
39. Liu Z, Okada DR, Johnson G3rd, Hocherman SD, Beju D, Okada RD. 99mTc-sestamibi kinetics predict myocardial viability in a perfused rat heart model. *Eur J Nucl Med Mol Imaging* 2008; 35: 570-8.
40. Siebelink HM, Blanksma PK, Crijs HJ, Bax JJ, van Boven AJ, Kingma T, et al. No difference in cardiac event-free survival between positron emission tomography-guided single-photon emission computed tomography-guided patient management: a prospective, randomized comparison of patients with suspicion of jeopardized myocardium. *J Am Cardiol* 2001; 37: 81-8.
41. Aoki M, Sakai K, Koyanagi S, Takeshita A, Nakamura M. Effect of nitroglycerin on coronary collateral function during exercise evaluated by quantitative analysis of thallium-201 single photon emission computed tomography. *Am Heart J* 1991; 121: 1361-6.
42. Bisi G, Sciagrà R, Santoro GM, Fazzini PF. Rest technetium-99m sestamibi tomography in combination with short-term administration of nitrates feasibility and reliability for prediction of post-revascularization outcome of asynergic territories. *J Am Coll Cardiol* 1994; 24: 1282-9.
43. Acampa W, Evangelista L, Sorrentino AR, Petretta M, Luongo L, Cuocolo A. Single-photon emission computed tomography after nitrate administration predicts cardiac events in patients with previous myocardial infarction and left ventricular dysfunction. *J Card Fail* 2007; 13: 765-8.
44. Iskandrian AE, Acio E. Methodology of a novel myocardial viability protocol. *J Nucl Cardiol* 1998; 5: 206-9.
45. Ciavolella M, Greco C, Tavoraro R, Tanzilli G, Scopinaro F, Campa PP. Acute oral trimetazidine administration increases resting technetium 99m sestamibi uptake in hibernating myocardium. *J Nuc Cardiol* 1998; 5: 128-33.
46. Matsunari I, Fujino S, Taki J, Senma J, Aoyama T, Wakasugi T, et al. Quantitative rest technetium-99m tetrofosmin imaging in predicting functional recovery after revascularization comparison with rest-redistribution thallium-201. *J Am Coll Cardiol* 1997; 29: 1226-33.
47. Gunning MG, Anagnostopoulos C, Knight CJ, Pepper J, Burman ED, Davies G, et al. Comparison of 201Tl, 99mTc-tetrofosmin and dobutamine magnetic resonance imaging for identifying hibernating myocardium. *Circulation* 1998; 98: 1869-74.
48. He W, Acampa W, Mainolfi C, Menna F, Sorrentino AR, Petretta M, et al. Tc-99m tetrofosmin tomography after nitrate administration in patients with ischemic left ventricular dysfunction: relation to metabolic imaging by PET. *J Nucl Cardiol* 2003; 10: 599-606.
49. Giogetti A, Pingitore A, Favilli B, Kusch A, Lombardi M, Marzullo P, et al. Baseline/postnitrate tetrofosmin SPECT for myocardial viability assessment in patients with postischemic severe left ventricular dysfunction: new evidence from MRI. *J Nuc Med* 2005; 46: 1285-93.
50. Stollfuss JC, Haas F, Matsunari I, Neverve J, Nekolla S, Ziegler S et al. 99m Tc-tetrofosmin SPECT for prediction of functional recovery defined by MRI in patients with severe left ventricular dysfunction additional value of gated SPECT. *J Nucl Med* 1999; 40: 1824-31.
51. Morishima I, Sone T, Tsuboi H, Mukawa H, Uesugi M, Morikawa S, et al. Risk stratification of patients with prior myocardial infarction and advanced left ventricular dysfunction by gated myocardial perfusion SPECT imaging. *J Nucl Cardiol* 2008; 15: 631-7.
52. Gropler RJ, Geltman EM, Sampathkumaran K, Pérez JE, Schechtman KB, Conversano A, et al. Comparison of carbon-11 acetate with fluorine-18 fluorodeoxyglucose for delineating viable myocardium by positron emission tomography. *J Am Coll Cardiol* 1993; 22: 1587-97.
53. Schwaiger M, Nekolla SG. Coronary artery disease: tissue viability and perfusion. In: Von Schulthess GK, editor. *Molecular Anatomic Imaging. PET-CT and SPECT-CT Integrated Modality Imaging*. Philadelphia, PA: Lippincott Williams & Wilkins; 2007. p. 227-43.
54. Tillisch J, Brunken R, Marshall R, Schwaiger M, Mandelkern M, Phelps M, et al. Reversibility of cardiac wall motion abnormalities predicted by positron tomography. *N Engl J Med* 1986; 314: 884-8.
55. Brunken RC, Mody FV, Hawkins RA, Nienaber C, Phelps ME, Schelbert HR. Positron emission tomography detects metabolic viability in myocardium with persistent 24-hour single-photon emission computed tomography 201 Tl defects. *Circulation* 1992; 86: 1357-69.
56. Rohatgi R, Epstein S, Henriquez J, Ababneh AA, Hickey KT, Pinsky D, et al. Utility of positron emission tomography in predicting cardiac events and survival in patients with coronary artery disease and severe left ventricular dysfunction. *Am J Cardiol* 2001; 87: 1096-9.
57. Brunken RC, Kotton S, Nienaber CA, Schwaiger M, Ratib OM, Phelps ME, et al. PET detection of viable tissue in myocardial segments with persistent defects at Tl-201 SPECT. *Radiology* 1989; 172: 65-73.
58. Gropler RJ, Geltman EM, Sampathkumaran K, Pérez JE, Moerlein SM, Sobel BE, et al. Functional recovery after coronary revascularization for chronic coronary artery disease is dependent on maintenance of oxidative metabolism. *J Am Coll Cardiol* 1992; 20: 569-77.
59. Gropler RJ, Siegel BA, Sampathkumaran K, Pérez JE, Sobel BE, Bergmann SR, et al. Dependence of recovery of contractile function on maintenance of oxidative metabolism after myocardial infarction. *J Am Coll Cardiol* 1992; 19: 998-97.
60. Gropler RJ, Geltman EM, Sampathkumaran K, Pérez JE, Schechtman KB, Conversano A, et al. Comparison of carbon-11-acetate with fluorine-18-fluorodeoxyglucose for delineating viable myocardium by positron emission tomography. *J Am Coll Cardiol* 1993; 22: 1587-97.
61. Tamaki N, Morita K, Tsukamoto E, Kawai Y. Future aspects of BMIPP. *Int J Card Imaging* 1999; 15: 79-89.
62. Di Carli MF, Asgarzadie F, Schelbert HR, Brunken RC, Laks H, Phelps ME, et al. Quantitative relation between myocardial viability and improvement in heart failure symptoms after revascularization in patients with ischemic cardiomyopathy. *Circulation* 1995; 92: 3436-44.

63. Bonow RO. The hibernating myocardium: Implications for management of congestive heart failure. *Am J Cardiol* 1995; 75 Suppl: 17A-25A.
64. Slart RH, Agool A, van Veldhuisen DJ, Dierckx RA, Bax JJ. Nitrate administration increases blood flow in dysfunctional but viable myocardium, leading to improved assessment of myocardial viability: A PET study. *J Nuc Med* 2006; 47: 1307-11.
65. Bax JJ, Wijns W, Cornel JH, Visser FC, Boersma E, Fioretti PM. Accuracy of currently available techniques for ventricular dysfunction due to chronic coronary artery disease: comparison of pooled data. *J Am Coll Cardiol* 1997; 30: 1451-60.
66. Lee KS, Marwick TH, Cook SA, Go RT, Fix JS, James KB, et al. Prognosis of patients with left ventricular dysfunction, with and without viable myocardium after myocardial infarction. Relative efficacy of medical therapy and revascularization. *Circulation* 1994; 90: 2687-94.
67. Di Carli MF, Davidson J, Little R, Khanna S, Mody FV, Brunken RC, et al. Value of metabolic imaging with positron emission tomography for evaluating prognosis in patients with coronary artery disease and left ventricular dysfunction. *Am J Cardiol* 1994; 73: 527-33.
68. Eitzman D, Al-Aouar Z, Kanter HI, vom Dahl J, Kirsh M, Deeb GM, et al. Clinical outcome of patients with advanced coronary artery disease after viability studies with positron emission tomography. *J Am Coll Cardiol* 1992; 20: 559-65.
69. Maddahi J, Di Carli M, Davidson M, et al. Prognostic significance of PET assessment of myocardial viability in patients with left ventricular dysfunction. *J Am Coll Cardiol* 1992; 19: 142A. (Abstract)
70. Tamaki N, Kawamoto M, Takahashi N, Yonekura Y, Magata Y, Nohara R, et al. Prognostic value of an increase in fluorine-18 deoxyglucose uptake in patients with myocardial infarction: comparison with stress thallium imaging. *J Am Coll Cardiol* 1993; 22: 1621-7.
71. Di Carli MF. Assessment of myocardial viability after myocardial infarction. *J Nucl Cardiol* 2002; 9: 229-35.
72. Dreyfus GD, Duboc D, Blasco A, Vigoni F, Dubois C, Brodaty D, et al. Myocardial viability assessment in ischemic cardiomyopathy: benefits of coronary revascularization. *Ann Thorac Surg* 1994; 57: 1402-7.
73. Haas F, Hähnel C, Sebening F, Meisner H, Schwaiger M. Effect of preoperative PET viability on peri- and postoperative risk. *J Am Coll Card* 1996; 27: 300A. (Abstract)
73. Tarakji KG, Brunken R, McCarthy PM, Al-Chekakie MO, Abdel-Latif A, Pothier CE, et al. Myocardial viability testing and the effect of early intervention in patients with advanced left ventricular systolic dysfunction. *Circulation* 2006; 113: 230-7.
74. Maddahi J, Blitz A, Phelps M, Laks H. The use of positron emission tomography imaging in the management of patients with ischemic cardiomyopathy. *Adv Cardiol Surg* 1996; 7: 163-88.
75. Dreyfus GD, Duboc D, Blasco A, Vigoni F, Dubois C, Brodaty D, et al. Myocardial viability assessment in ischemic cardiomyopathy: Benefits of coronary revascularization. *Ann Thorac Surg* 1994; 57: 1402-8.
76. Akinboboye O, Idris O, Cannon PJ, Bergmann SR, et al. Usefulness of positron emission tomography in defining myocardial viability in patients referred for cardiac transplantation. *Am J Cardiol* 1999; 83: 1271-4.
77. Allman KC, Shaw LJ, Hachamovitch R, Udelson JE. Myocardial viability testing and impact of revascularization on prognosis in patients with coronary artery disease and left ventricular dysfunction: a meta-analysis. *J Am Coll Cardiol* 2002; 39: 1151-8.
78. Czernin J, Allen-Auerbach M, Schöder H, et al. Impact of cardiac PET on management of patients with congestive heart failure. *J Nuc Med* 1999; 40: 47P. (Abstract)
79. Samady H, Elefteriades JA, Abbott BG, Mattera JA, McPherson CA, Wackers FJ. Failure to improve left ventricular function after coronary revascularization for ischemic cardiomyopathy is not associated with worse outcome. *Circulation* 1999; 100: 1298-304.
80. Udelson JE. Step forward in the assessment of myocardial viability in left ventricular dysfunction. *Circulation* 1998; 97: 833-8.
81. Forrester JS, Price MJ, Makkar RR. Stem cell repair of infarcted myocardium. An overview for clinicians. *Circulation* 2003; 108: 1139-45.
82. Fam NP, Verna S, Kutryk M, Stewart DJ. Clinician guide to angiogenesis. *Circulation* 2003; 108: 2613-8.