

risk factors. As a remarkable fact, her son had died that day. On admission, physical examination revealed no pathological findings. Electrocardiogram (ECG) showed 1 mm ST elevation in leads I and aVL. There was not ST elevation in precordial leads (Fig. 1A). Transthoracic echocardiography (TTE), revealed apical akinesia, midventricular hypokinesia and basal hyperkinesia of the left ventricle with ejection fraction of 35%. Coronary angiography revealed normal coronary arteries. However, ventriculography (Video 1. See corresponding video/movie images at www.anakarder.com) showed apical and midventricular ballooning with basal hyperkinesia. Chest pain disappeared spontaneously. Cardiac enzyme and troponin levels were elevated and reached to maximal degrees on the 2nd day. Although there was no abnormality in precordial leads on the 1st day, electrocardiogram showed inverted T waves in precordial leads, I and aVL on the 8th day (Fig.1B). Transthoracic echocardiography, performed on the 7th day, revealed normal left ventricular systolic functions. With these findings, we diagnosed the Takotsubo cardiomyopathy (TC) and discharged her from hospital in excellent condition. Takotsubo cardiomyopathy is characterized by the finding of transient left ventricular wall motion abnormalities accompanied by chest pain, dynamic reversible ST-T segment abnormalities, and mild elevation of cardiac enzymes usually present with a recent history of emotional or physical stress. Although ST elevation or T wave inversion in the anterior leads have been the most commonly recorded electrocardiographic findings ECG can be normal or can show nonspecific changes.

Murat Biteker, Nilüfer Ekşi Duran, Tayyar Gökdeniz, Sabahattin Gündüz, Ahmet Güler, Hasan Kaya, Mustafa Yıldız, Mehmet Özkan
Clinic of Cardiology, Kartal Koşuyolu Heart Education and Research Hospital, İstanbul, Turkey

Address for Correspondence/Yazışma Adresi: Dr. Murat Biteker, Kartal Koşuyolu Heart Education and Research Hospital, Clinic of Cardiology, İstanbul, Turkey
Phone: +90 216 488 80 02 Fax: +90 216 459 63 21
E-mail: murbit2@yahoo.com

©Telif Hakkı 2010 AVES Yayıncılık Ltd. Şti. - Makale metnine www.anakarder.com web sayfasından ulaşılabilir.
©Copyright 2010 by AVES Yayıncılık Ltd. - Available on-line at www.anakarder.com
doi:10.5152/akd.2010.027

Pulmonary stenosis due to metastatic malignant melanoma



Metastatik malin melanomun neden olduğu pulmoner darlık

A 60-year-old male with a history of resected malignant melanoma of neck region and three courses of chemotherapy was presented with

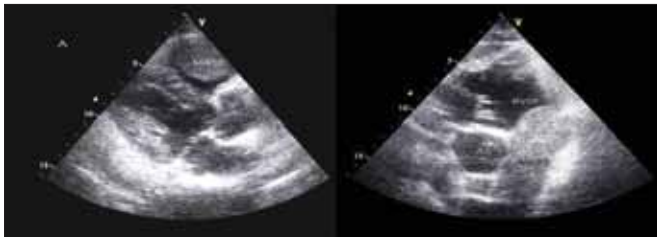


Figure 1. Two-dimensional echocardiogram, parasternal long-axis view showing the mass in the right ventricular outflow tract (panel A) and parasternal short-axis view showing the right ventricular valve mass, obstructing the outflow tract and impinging onto the pulmonary valve (panel B)

Ao - aorta, RVOT - right ventricular outflow tract

exertional dyspnea and near syncope. On cardiovascular examination his heart rate was 90/min and the blood pressure was 90/60 mmHg. Cardiac auscultation revealed a grade 2/6 systolic ejection murmur along the left sternal border. Two-dimensional (2-D) echocardiography showed a 7x3 cm mobile mass in the right ventricle extending into right ventricular outflow tract (Video 1. See video/movie images at www.anakarder.com). Right ventricle was dilated and the mass was found in a narrow pulmonary outflow tract (Fig. 1). A 50 mmHg peak systolic gradient was demonstrated with continuous wave Doppler. At surgery, 7x4 cm mass filling the right ventricular outflow tract was found and removed (Fig. 2). Histopathologic examination of the mass confirmed the diagnosis of malignant melanoma. He was transferred to oncology department with planning of systemic immuno-chemotherapy. However, two months after the surgery, he was hospitalized again due to deep vein thrombosis and pulmonary embolism. Repeated 2-D echocardiography demonstrated complete resolution of right ventricle mass.

Although malign melanoma generally metastasizes to lungs, brain, liver, on post-mortem examination cardiac structures are involved in about half of cases. Despite frequent involvement of the heart, however, less than 5% are diagnosed with such ante mortem due to nonspecific symptoms and clinical signs. Therefore, patients with known malignant melanoma who have cardiac symptoms should always be evaluated with cardiac imaging techniques such as echocardiography to demonstrate the possible cardiac metastasis.

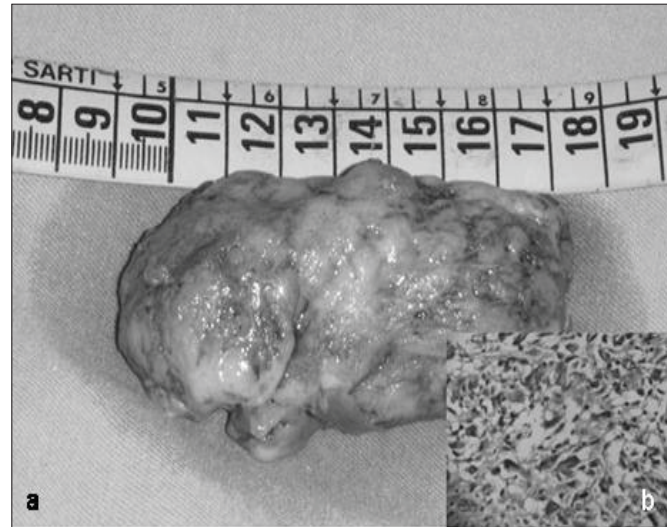


Figure 2. A) Gross appearance of removed mass. B) The histopathologic examination of the tumor revealed melanoma cells with spindle cytoplasm. Nuclei are large and hyperchromatic, rare binuclear forms are noted (Hematoxylin-eosin, original x10)

Yeşim Güray, Çağatay Tuncel*, Zişan Sakaoğulları, Ayça Boyacı, Levent Birincioğlu***
From Departments of Cardiology, *Cardiovascular Surgery and **Pathology, Yüksek İhtisas Hospital, Ankara, Turkey

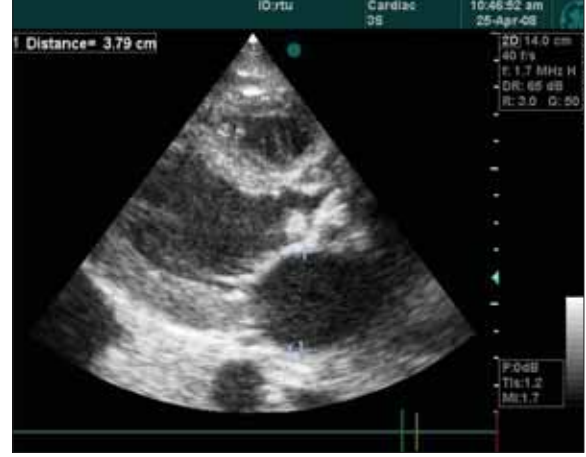Address for Correspondence/Yazışma Adresi: Dr. Yeşim Güray, Yüksek İhtisas Hospital, Department of Cardiology, Ankara, Turkey
Phone: +90 312 306 18 38 Fax: +90 312 324 39 83 E-mail: yesimguray@gmail.com
©Telif Hakkı 2010 AVES Yayıncılık Ltd. Şti. - Makale metnine www.anakarder.com web sayfasından ulaşılabilir.
©Copyright 2010 by AVES Yayıncılık Ltd. - Available on-line at www.anakarder.com
doi:10.5152/akd.2010.028

Serbest duvarda büyük hareketli vejetasyon ile kendisini belli eden infektif endokardit olgusu

A case of infective endocarditis presented with a giant free wall vegetation

Kırk altı yaşındaki erkek hasta şiddetli nefes darlığı, halsizlik ve ateş yüksekliği şikayetiyle hastanemizin acil servisine başvurdu. Son 4 aydır halsizlik ve aralıklı ateş yükselmelerinin olduğu, 15 gün öncesinde başvurduğu bir merkezde ampirik antibiyotik tedavisi başlandığı öğrenildi. Muayenede genel durumu kötü ve bilinci bulanıktı. Fizik muayenesinde; kan basıncı 80/50 mmHg, nabız 110 atım/dak, ateş 38.2°C olarak ölçüldü. Dinlemekle aort odağı ve apekte 2/6 sistolik üfürüm, her iki akciğerde yaygın ekspiratuvar ronküs mevcuttu. Transtorasik ekokardiyografide nonkoroner aort kapakçıkta ve septum bazalinde olmak üzere 0.9X0.8 cm ile 1.0X1.1 cm ebatlarında iki adet hareketli kitle (Şekil 1) (Video 1-3. Video/hareketli görüntüler www.anakarder.com'da izlenebilir), ileri mitral yetersizlik, orta mitral stenozu, orta aort yetersizliği ve hafif aort darlığı olduğu görüldü. Kan tetkiklerinde lökosit 27500/mm³, CRP: 11.4 mg/dl, hemoglobin: 7.5 g/dl, platelet: 324.000/mm³, sedimentasyon: 104 mm/saat, kreatinin: 2.41mg/dl, BUN:56 mg/l olarak saptandı. Arter kan gazı ölçümünde pH:7.15, pCO₂: 37 mmHg, pO₂:62 mmHg, BE:-15 olarak ölçüldü. Hasta entübe edildi ve dahiliye yoğun bakım ünitesine yatırıldı. İnfektif endokardit ön tanısıyla ampirik sefazolin 1 g IV ve gentamisin 40 mg IV 3x1 tedavisine başlanan hastada erken operasyon planlandı. Kan kültürlerinde muhtemelen önceden antibiyotik alması nedeniyle üreme olmadı. Kliniğimizde kalp damar cerrahi anabilim dalının olmaması nedeniyle komşu merkezlerle yapılan görüşmelerde hastanın stabilizasyonundan sonra sevki kararlaştırıldı. Takibinde hipotermik seyreden, lökositoz ve trombositopeni gelişen hasta yatışının 12. gününde exitus

oldu. Olgu vejetasyon yerleşimi açısından ilginç ve tanının ya da cerrahi girişimin gecikmesi durumunda yüksek mortaliteye yol açtığını göstermesi bakımından öğreticidir.



Şekil 1. Parasternal uzun aks kesitte aort kapak komşuluğunda dev vejetasyon görüntüsü

Serhat Bahadır Sözen, Ahmet Kaya, Hakan Cinemre¹, Enver Sinan Albayrak, Hakan Özhan, Mehmet Yazıcı
Düzce Üniversitesi Düzce Tıp Fakültesi, Kardiyoloji Anabilim Dalı, ¹İç Hastalıkları Anabilim Dalı, Düzce, Türkiye

Yazışma Adresi/Address for Correspondence: Dr. Serhat Bahadır Sözen
Düzce Üniversitesi Tıp Fakültesi, Kardiyoloji Anabilim Dalı, Düzce, Türkiye
Tel: +90 380 542 13 90 Faks: +90 380 542 1398

E-posta: serhatsozen@yahoo.com

©Telif Hakkı 2010 AVES Yayıncılık Ltd. Şti. - Makale metnine www.anakarder.com web sayfasından ulaşılabilir.

©Copyright 2010 by AVES Yayıncılık Ltd. - Available on-line at www.anakarder.com
doi:10.5152/akd.2010.029