

Clinical Characteristics and Surgical Outcomes of Right Heart Myxoma and Its Comparison with Left Heart Myxoma: A Single-Center Retrospective Study

ABSTRACT

Background: Cardiac myxomas are commonly located in the left atrium but rarely affect the right side of the heart. We retrospectively analyzed 28 patients receiving surgical treatment for right heart myxomas at our center and aimed to summarize the clinical features and surgical outcomes of right heart myxomas.

Methods: Between May 2001 and June 2022, 244 patients with sporadic cardiac myxomas underwent complete surgical resection. Twenty-eight patients (28/244, 11.48%) were right heart myxomas. Among the 28 right heart myxoma cases, 25 underwent median sternotomy and 3 underwent robotic or total thoracoscopic procedures. The clinical features, operative information, and follow-up data of right heart myxoma were comprehensively reviewed, and clinical characteristics between right heart myxoma and left heart myxoma were also compared.

Results: A significant difference was noted in sex between right heart myxoma and left heart myxoma ($P < .05$). Right heart myxoma had a higher asymptomatic rate (17.86% vs. 3.70%, $P = .007$) and a lower embolization rate (3.57% vs. 30.09%, $P = .003$) than left heart myxoma. The most common attachment site of right heart myxoma is the atrial septum. The mean operative duration and cardiopulmonary bypass time of right heart myxoma resection were 207.71 ± 53.40 minutes and 63.86 ± 29.73 minutes, respectively, with an in-hospital mortality rate of 3.57%. During the follow-up, 2 patients died of noncardiac causes. The overall 1-, 2-, and 5-year actuarial survival rates after right heart myxoma resection were 95.8%, 90.8%, and 84.7%, respectively.

Conclusions: As a rare cardiac tumor, the clinical characteristics of right heart myxoma are different from typical left heart myxoma in some aspects, such as sex, asymptomatic rate, and embolization rate. Prompt surgical resection of right heart myxoma gives excellent early and mid-term results.

Keywords: Cardiac myxoma, right heart, sporadic, surgical outcomes, thoracoscopy

INTRODUCTION

Myxoma is the most common type of primary cardiac tumor, accounting for approximately 75%-80% of all primary neoplasms of the heart.¹ The prevalence of cardiac myxoma is estimated at 0.5 per million per year.² The most common location of myxomas is the left atrium (75%-80%).¹⁻⁴ However, when myxomas originate at right-sided chambers of the heart such as the right atrium or right ventricle, they are designated as right heart myxomas (RHMs). Due to their low incidence,⁴ RHMs have been mainly described in some isolated case reports.⁴⁻⁷ A retrospective series that included a certain number of RHM cases is still scarce.⁸ Thus, the clinical features and surgical outcomes of RHM are not well documented. Therefore, in this study, we retrospectively analyzed 28 patients who underwent resection for RHM at our center and aimed to evaluate the surgical outcomes of RHM and compare its clinical characteristics to those of left heart myxoma (LHM). To the best of our knowledge, this study was one of the few series with a relatively large sample of RHM reported in the literature.

ORIGINAL INVESTIGATION

Yanyi Liu¹ 

Xin Li¹ 

Zhuang Liu¹ 

Yiyao Jiang² 

Chenghao Lu¹ 

Shenglin Ge¹ 

Chengxin Zhang¹ 

¹Department of Cardiac Surgery, the First Affiliated Hospital of Anhui Medical University, Hefei, Anhui, China

²Department of Cardiac Surgery, the First Affiliated Hospital of Bengbu Medical College, Bengbu, Anhui, China

Corresponding author:

Chengxin Zhang
✉ zcxayfy@126.com

Received: September 26, 2022

Accepted: November 24, 2022

Available Online Date: January 31, 2023

Cite this article as: Liu Y, Li X, Liu Z, et al. Clinical characteristics and surgical outcomes of right heart myxoma and its comparison with left heart myxoma: A single-center retrospective study. *Anatol J Cardiol.* 2023;27(3):146-152.



Copyright©Author(s) - Available online at anatoljcardiol.com.
Content of this journal is licensed under a Creative Commons Attribution-NonCommercial 4.0 International License.

DOI:10.14744/AnatolJCardiol.2022.2585

METHODS

Patient Selection

Between May 2001 and June 2022, 244 patients with sporadic cardiac myxomas underwent surgical resection at our institution. Among the 244 cases, 28 were RHMs (11.48%) and 216 were LHMs (88.52%). The clinical features of 28 RHM cases were then compared to those of 216 LHM cases. Of the 28 RHM cases, 26 were right atrial myxomas (RAMs) and 2 were right ventricular myxomas (RVMs). While the LHMs were all left atrial myxomas (LAMs), the left ventricular myxomas (LVMs) were not detected. The preoperative diagnosis of RHM was confirmed by transthoracic echocardiography (TTE); transesophageal echocardiography was performed for patients in whom the diagnosis was doubtful by TTE. A definitive diagnosis was determined based on the pathological results postoperatively. However, patients with a possible diagnosis of RHM on echocardiography who did not undergo surgery were excluded. Clinical and follow-up data were obtained from electronic medical records and follow-up surveys.

Surgical Technique

In 25 patients (25/28, 89.29%), RHMs were excised through median sternotomy under cardiopulmonary bypass using aortic and bicaval cannulation (cardiac arrest in 23, beating heart in 2). To prevent detachment of the mass and intraoperative embolization, we minimized movement and compression of the heart during the surgery. Right atriotomy was performed in all 25 patients; of these, 2 cases were RVM, and ventricular tumors were approached across the tricuspid valve in 1 patient and through an extra right ventriculotomy in the other patient. The basic principle of excision was the complete resection of the tumor and its attached sites. The attachment sites of RHM are listed in Table 1. All myxomas were excised completely. The defect of the atrial septum and right atrial free wall after myxoma resection was repaired with a bovine or autologous pericardial patch when needed. Transesophageal echocardiography was performed at the end of the procedure to assess the presence of a residual tumor or interatrial shunting after septal reconstruction.

Of the remaining 3 patients, 2 underwent total endoscopic robotic RAM resection with da Vinci Surgical System (Intuitive Surgical, Sunnyvale, Calif, USA), and 1 underwent

Table 1. Attached sites of RHM and LHM

	RHM (n=28)	LHM (n=216)	P
Atrial septum	14 (50.0%)	175 (81.02%)	<.001*
Other attached sites	14 (50.0%)	41 (18.98%)	<.001*
	Near vena cava: 4 (14.29%)	Mitral annulus: 14 (6.48%)	-
	Free wall of RA: 4 (14.29%)	Back wall of LA: 10 (4.63%)	-
	Tricuspid annulus: 3 (10.71%)	PV orifice: 9 (4.17%)	-
	CS orifice: 2 (7.14%)	Roof of LA: 8 (3.70%)	-
	Ventricular septum: 1 (3.57%)	-	-

*Statistically significant parameter.

CS, coronary sinus; LA, left atrium; LHM, left heart myxoma; PV, pulmonary vein; RA, right atrium; RHM, right heart myxoma.

total thoracoscopic surgery for RAM resection. Both robotic and thoracoscopic surgeries are minimally invasive procedures for which the peripheral cardiopulmonary bypass was established via right internal jugular venous cannulation and femoral arterial and venous cannulations. In both these procedures, RAM was excised via right atriotomy on the beating heart without aortic occlusion. The principles for myxoma resection were the same as those for conventional surgeries with median sternotomy.

Follow-Up Method

After discharge, patients were followed up at the outpatient center. A telephonic interview was required for those who were lost to the ambulatory follow-up. Of the 27 discharged RHM patients, 23 (23/27, 85.19%) were followed up for 12-161 months (mean, 58.35 ± 40.71 months; median, 48.0 months). Whereas for 214 discharged LHM patients, 173 patients (173/214, 80.84%) were followed from 3 to 219 months (mean, 66.65 ± 47.70 months; median, 59.0 months).

Statistical Analysis

Statistical analysis was performed using Statistical Package for Social Sciences 25.0 (IBM, Chicago, Ill, USA). Quantitative variables were expressed as mean ± standard deviation if normally distributed, otherwise as median and 25-75 percentile. Normally distributed data were compared using Student's *t*-test, and data with skewed distribution were compared using Mann-Whitney *U*-test. Categorical data were described as numbers and percentages and compared using Pearson's χ^2 test or Fisher's exact test. The Kaplan-Meier method was used to draw survival curves and calculate 1-, 2-, and 5-year survival rates. Survival data were compared by log-rank test. A *P*-value of <.05 was considered statistically significant.

RESULTS

There was no significant difference in age and size between RHM and LHM (*P* > .05). However, there was a significant difference in sex between RHM and LHM (*P* < .05). The sex ratio

HIGHLIGHTS

- Cardiac myxoma commonly occurs in the left atrium but rarely in the right side of the heart. Right heart myxoma can present with a wide range of symptoms from being asymptomatic to leading to catastrophic consequences.
- Right heart myxoma differs from typical left heart myxoma in sex proportion, asymptomatic rate, and embolization rate.
- The most common attachment site of right heart myxoma is the atrial septum.
- Prompt surgical resection of right heart myxoma gives excellent early and mid-term results.

(female : male) was 1.15 in RHM and 2.60 in LHM. For patients of both groups, preoperative symptoms can be summarized into 3 major categories: obstructive cardiac symptoms, constitutional symptoms, and embolic phenomenon. There was no significant difference between the RHM and LHM regarding the incidence of each obstructive or constitutional symptom ($P > .05$). However, embolic events were found to be more prevalent in LHM than in RHM (30.09% vs. 3.57%, $P = .003$), and LHM appears to have a greater incidence of cerebral embolism than RHM ($P = .001$). No significant difference was noted in the incidence of pulmonary embolism between the 2 groups ($P > .05$). Additionally, RHM was more likely to be asymptomatic than LHM ($P < .05$). Table 2 summarizes the preoperative clinical features of RHM and compares them with those of LHM.

The most common attachment sites of RHM and LHM were the atrial septum (50.0% and 81.02%, respectively). In addition, RHM was more likely to be attached to other uncommon sites than LHM (50.0% vs. 18.98%, $P < .001$). The attachment sites of RHM and LHM are listed in Table 1.

The comparison of perioperative outcomes between RHM and LHM resection is listed in Table 3. Operation time showed no significant difference between the 2 groups ($P = .119$).

Table 2. Clinical characteristics of RHM and LHM

Parameters	RHM (n=28)	LHM (n=216)	P
Gender (male/female)	13/15	60/156	.043*
Age	54.11 ± 16.59	53.99 ± 13.34	.966
Myxoma size			
Length (mm)	56.61 ± 21.08	53.50 ± 18.41	.409
Width (mm)	43.68 ± 17.48	38.42 ± 13.68	.066
Asymptomatic	5 (17.86%)	8 (3.70%)	.007*
Symptoms			
Obstructive cardiac	21 (75.00%)	186 (86.11%)	.207
Dyspnea	17 (60.71%)	156 (72.22%)	.207
Palpitation	8 (28.57%)	72 (33.33%)	.614
Syncope	4 (14.29%)	18 (8.33%)	.494
Dizziness	7 (25.00%)	35 (16.20%)	.371
Chest pain	3 (10.71%)	18 (8.33%)	.949
Edema	5 (17.86%)	44 (20.37%)	.755
AHF	3 (10.71%)	15 (6.94%)	.739
Constitutional	13 (46.43%)	102 (47.22%)	.937
Fever	1 (3.57%)	13 (6.02%)	.927
Fatigue	4 (14.29%)	34 (15.74%)	1.000
Weight loss	2 (7.14%)	25 (11.57%)	.702
Anemia	8 (28.57%)	70 (32.41%)	.682
Embolic	1 (3.57%)	65 (30.09%)	.003*
Pulmonary embolism	1 (3.57%)	0 (0.00%)	.115
Cerebral embolism	0 (0.00%)	65 (30.09%)	.001*
Atrial fibrillation	2 (7.14%)	8 (3.70%)	.721

*Statistically significant parameter.

AHF, acute heart failure; LHM, left heart myxoma; RHM, right heart myxoma.

However, CPB time and aortic clamping time of RHM resection were significantly shorter than LHM resection ($P < .05$). Concomitant tricuspid annuloplasty was more frequently performed in RHM resection than LHM resection ($P = .008$). Differences were not noted in 30-day mortality ($P = .307$), postoperative 24-h drainage ($P = .628$), intensive care unit stay time ($P = .528$), mechanical ventilation time ($P = .499$), and postoperative hospital stay time ($P = .591$) between the 2 groups. There was 1 early death after RHM resection due to low cardiac output syndrome on postoperative day 2. One RHM patient suffered a wound infection before discharge, and the remaining 26 RHM cases recovered uneventfully. There were 2 early deaths after LHM resection, due to low cardiac output syndrome and sudden cardiac arrest, respectively.

Histologic examination confirmed the diagnosis of myxoma in every case. The detailed clinicopathologic characteristics of the 28 RHM patients are listed in Table 4.

Of the 27 discharged RHM patients, 23 (23/27, 85.19%) were followed up for 12-161 months (mean, 58.35 ± 40.71 months; median, 48.0 months). During follow-up, 1 patient died due to systemic lupus erythematosus 36 months after RHM resection and 1 died due to gastric cancer 19 months after RHM resection. Overall, the actuarial survival rates of patients undergoing RHM resection were 95.8%, 90.8%, and 84.7% at 1, 2, and 5 years, respectively (Figure 1). Furthermore, another patient in the RHM group developed paroxysmal supraventricular tachycardia 3 years postoperatively and underwent radio frequency catheter ablation. No recurrence after RHM resection was observed. All surviving patients after RHM resection were in New York Heart Association functional

Table 3. Comparison of Perioperative Outcomes

Variable	RHM (n=28)	LHM (n=216)	P
Operation time (min)	207.71 ± 53.40	225.50 ± 56.97	.119
CPB time (min)	63.86 ± 29.73	78.60 ± 30.95	.018
Aortic cross-clamp time (min)	34.43 ± 15.13	47.84 ± 21.56	.004
Concomitant procedures [n (%)]			
Tricuspid annuloplasty	6 (21.43)	12 (5.56)	.008
Pulmonary embolectomy	1 (3.57)	0 (0.0)	.115
Mitral annuloplasty	0 (0.0)	11 (5.09)	.461
24-h drainage volume (mL)	252.50 (182.50, 356.25)	260.00 (180.00, 379.50)	.628
ICU stay (h)	28.25 (19.00, 39.75)	26.25 (19.00, 42.00)	.528
Mechanical ventilation time (h)	9.50 (5.13, 14.00)	10.25 (6.00, 16.00)	.499
Postoperative hospital stay (days)	10.00 (8.00, 12.00)	10.00 (8.00, 12.75)	.591
30-day mortality [n (%)]	1 (3.57)	2 (0.93)	.307

CPB, cardiopulmonary bypass; ICU, intensive care unit; LHM, left heart myxoma; RHM, right heart myxoma.

Table 4. Detailed Clinicopathologic Characteristics of RHM

Case	Age (years)/sex	Presentations	Location/Attached Sites	Size (cm)	Pathological Features
Case 1	18/male	Dyspnea	RA/atrial septum	2.0 × 0.6	Papillary, nodular, friable, gelatinous, brown, foci of glassy and mucinous degeneration
Case 2	49/female	Syncope, dizziness, anemia	RV/ventricular septum	6.0 × 5.0	Solid, oval, smooth, firm, greenish yellow, gelatinous
Case 3	50/male	Palpitation, syncope, edema, anemia	RA/atrial septum	7.0 × 4.0	Papillary, lobulated, soft, brown, gelatinous
Case 4	62/male	Chest pain, anemia	RA/atrial septum	5.5 × 5.0	Solid, firm, globular, smooth, greenish yellow, gelatinous
Case 5	71/male	Dyspnea, palpitation, dizziness	RA/atrial septum	4.5 × 4.0	Papillary, nodular, soft, friable, gelatinous, grayish white
Case 6	68/female	Dyspnea, dizziness	RA/atrial septum	8.0 × 4.0	Solid, smooth, firm, oval, brown, gelatinous
Case 7	55/female	Chest pain, dizziness	RA/free wall of RA	7.0 × 6.0	Solid, globular, grayish brown, gelatinous
Case 8	59/female	Dyspnea, palpitation, edema, fatigue	RA/atrial septum	7.5 × 6.5	Papillary, nodular, gelatinous, grayish brown, focally hemorrhagic
Case 9	36/female	Dyspnea, syncope	RA/atrial septum	4.0 × 2.5	Solid, oval, firm, greenish brown, gelatinous
Case 10	40/male	Fever	RA/near IVC	5.0 × 5.0	Solid, cystic, firm, grayish white, foci of hyalinization focally calcification
Case 11	61/male	Dyspnea, palpitation, fatigue, weight loss	RA/atrial septum	9.5 × 7.0	Solid, lobulated, firm, smooth, greenish yellow, gelatinous
Case 12	67/male	AHF, dyspnea, dizziness	RA/free wall of RA	9.0 × 8.0	Solid, nodular, firm, greenish brown, gelatinous
Case 13	75/male	Dyspnea, palpitation, edema, fatigue	RA/atrial septum	6.0 × 3.5	Papillary, irregular, soft, grayish brown, gelatinous
Case 14	68/female	Dyspnea, dizziness	RA/near IVC	2.5 × 2.3	Papillary, soft, friable, gelatinous, reddish brown, old hemorrhage
Case 15	72/female	Asymptomatic	RA/near IVC	2.5 × 2.2	Solid, oval, firm, gray, inflammatory cell infiltration, focally hemorrhagic, calcification
Case 16	48/female	Dyspnea, palpitation, syncope, anemia	RA/at CS orifice	6.0 × 5.5	Solid, oval, brown, firm, hemorrhagic
Case 17	34/female	Asymptomatic	RA/atrial septum	1.0 × 0.7	Papillary, irregular, soft, grayish brown
Case 18	25/male	Anemia, fatigue	RA/at tricuspid annulus	8.0 × 6.0	Solid, oval, firm, grayish white, nodular, hemorrhagic
Case 19	73/female	Asymptomatic	RA/free wall of RA	4.5 × 3.5	Papillary, soft, lobulated, grayish brown, gelatinous
Case 20	68/female	Dyspnea, palpitation, edema, anemia	RA/atrial septum	6.0 × 5.0	Papillary, irregular, soft, grayish red, gelatinous
Case 21	49/male	Dyspnea, dizziness	RA/near CS orifice	7.0 × 6.0	Solid, firm, oval, brown, glassy, mucinous degeneration
Case 22	46/female	AHF, dyspnea, edema	RA/atrial septum	8.0 × 4.5	Papillary, soft, friable, reddish brown, hemorrhagic
Case 23	63/male	Dyspnea, anemia	RV/at tricuspid annulus	7.0 × 4.0	Solid, firm, lobulated, greenish brown, gelatinous
Case 24	50/male	Asymptomatic	RA/at tricuspid annulus	5.0 × 4.0	Solid, oval, firm, smooth, greenish yellow, gelatinous
Case 25	71/female	Dyspnea, weight loss	RA/near SVC	6.0 × 5.0	Solid, nodular, oval, firm, grayish brown, gelatinous
Case 26	66/male	Asymptomatic	RA/atrial septum	5.0 × 5.0	Papillary, lobulated, soft, friable, greenish brown, gelatinous
Case 27	17/female	Dyspnea, anemia	RA/atrial septum	5.5 × 5.0	Solid, firm, globular, greenish, gelatinous
Case 28	54/female	AHF, dyspnea, palpitation, chest pain	RA/free wall of RA	3.5 × 2.5	Papillary, soft, friable, brown, gelatinous

AHF, acute heart failure; CS, coronary sinus; IVC, inferior vena cava; RA, right atrium; RV, right ventricle; SVC, superior vena cava

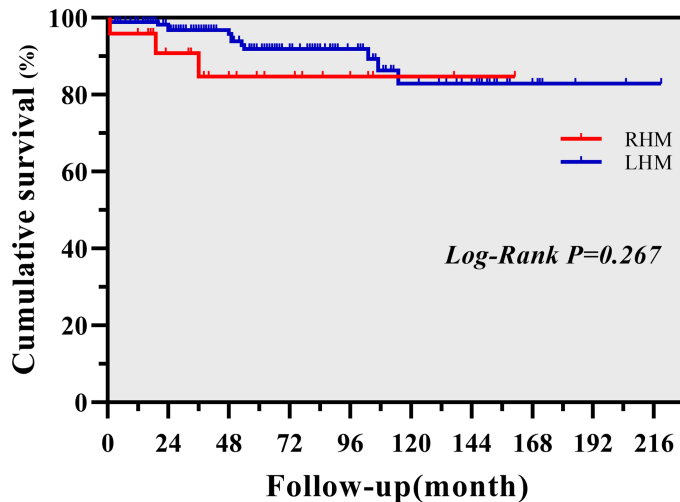


Figure 1. Kaplan–Meier survival curve after RHM and LHM resection. LHM, left heart myxoma; RHM, right heart myxoma.

classes I or II at follow-up (15 in class I and 6 in class II). However, the 1-, 2-, and 5-year actuarial survival rates for patients undergoing LHM resection were 98.9%, 96.8%, and 91.9%, respectively. And there was no significant difference in the actuarial survival rates between the RHM and LHM groups (log-rank $\chi^2=1.231$, $P=.267$, Figure 1).

DISCUSSION

As the most prevalent benign tumors of the heart,⁴ myxomas usually present as solitary and pedunculated masses attached to the fossa ovalis of the left atrium.^{9,10} However, for LAM or RAM, the atrial septum is generally considered to be the most common attachment site.^{8,11-13} One possible explanation for this is that myxomas are derived from multipotent mesenchymal cells,^{9,14} and these cells mainly arise in the fossa ovalis of the atrial septum.¹⁵ Li et al⁸ reported 28 cases of RAMs and found that the atrial septum was the most common attachment site, with 46.23% of RAM and 64.69% of LAM cases.⁸ However, in our study, we found that 50.0% of RHM cases and 81.02% of LAM cases were attached to the atrial septum; both proportions were higher than those reported by Li et al⁸ Moreover, we also found that RHM cases are more likely to be attached to other uncommon sites apart from the atrial septum than LHM cases (50.0% vs. 18.98%, $P < .001$).

Myxomas are more common in females, with a female preponderance of 2-2.6 : 1^{8,15}; RAM is more common in males (4M : 3F).⁷ Unlike previous studies,⁷⁻⁹ a female predominance (15/28, 53.6%) of RHM was noted in our study. In addition, our data identified that there was a significant difference in sex between RHM and LAM ($P < .05$), with a sex ratio (female : male) of 1.15 in RHM and 2.60 in LHM.

Depending on the size, location, and mobility of the tumors, cardiac myxomas can produce various symptoms.⁶ The symptoms can mainly be classified into 3 categories: intracardiac obstruction, embolism, and constitutional

symptoms.^{7,16} Dyspnea presented as the predominant intracardiac obstructive cardiac manifestation of myxoma in 57% of the patients.¹⁵ The results of our study were similar in that dyspnea was the most common clinical manifestation of RHM (60.71%). Our study also identified that RHM cases were more likely to be asymptomatic than LHM cases (17.86% vs. 3.7%, $P=.007$). Of the 28 patients with RHM, the largest diameter of the 5 asymptomatic cases was significantly smaller than that of the remaining 23 symptomatic cases (36.00 ± 17.82 vs. 61.09 ± 19.24 , $P < .05$). This reflected that the presence of symptoms was closely associated with the tumor size of RHM.

Embolization, caused by the fragment of myxoma, is a life-threatening complication.^{5,6} Embolic events occurred in 30%-40% of patients with left-sided myxoma,¹⁷ mainly in the cerebral arteries, but rarely in the coronary and peripheral arteries.¹¹ Right-sided myxomas can also embolize, but they usually cause pulmonary embolism.¹⁸ However, few studies have investigated the embolization rate of right-sided myxoma. Our study observed an embolization rate of 3.57% (1/28) in RHM, which is significantly lower than that of LAM (3.57% vs. 30.09%, $P < .05$). Despite the low incidence, pulmonary embolism caused by RHM can lead to deaths in some cases.¹⁹ Thus, once diagnosed, emergency surgery should be performed. In this retrospective series, a 54-year-old woman (case 28, RAM with pulmonary embolism) was successfully treated by emergency surgical resection of RAM and pulmonary embolectomy.

Deaths while awaiting surgery have been reported.² Thus, emergency surgery should be performed once the diagnosis of RHM is confirmed to prevent possible valvular obstruction.⁸ Case 22 was the only case of death in this study; the patient had a sudden cardiac arrest just before the emergency surgery due to obstruction in the tricuspid orifice. Although the obstruction was successfully removed by resection of RAM, the patient still died of low cardiac output syndrome on postoperative day 2. The important lesson from this case is that preoperative cardiac arrest due to valvular obstruction is associated with poor prognosis, and special attention should be paid to such patients with large sizes of RHM and confirmed valvular obstruction. The surgical principle for myxoma should include complete resection of the stalk with adequate tissue margins, careful removal of the tumor, thorough inspection of cardiac chambers, and reconstruction of the atrial septum or the cardiac wall.⁴ Therefore, the traditional approach for myxoma resection was median sternotomy with cardiopulmonary bypass.²⁰ Over the past decade, however, the concept of minimally invasive surgery has been suggested for the treatment of cardiac myxoma.²¹⁻²³ For example, Zhao et al²² and Deng et al²³ used a thoracoscopic technique to perform myxoma resection and demonstrated that this technique is a safe and effective method. In this study, 2 patients underwent robotic RAM resection and 1 underwent total thoracoscopic RAM resection. All 3 surgeries were successfully performed on the beating heart, and no embolism event or recurrence was observed postoperatively. We suggested that using a

robotic system or thoracoscope is easier to find the stalk and completely resect it because of visual magnification. Some researchers assumed that RVM has a high recurrence with only right atriotomy due to poor exposure.^{20,24} In this study, an extra right ventriculotomy was performed in case 2 (RVM) to allow better exposure for the stalk located at the distal ventricular septum, whereas in case 23 (RVM), good exposure was easily achieved via only right atriotomy for the stalk located at the tricuspid annulus. No recurrence was observed for these 2 RVM cases. Thus, we suggest that the optimal incision for RVM depends on the location of the stalk.

The outcomes for LAM resection are largely favorable, with an early mortality rate of <5%.²⁵⁻²⁶ However, outcome data on RHM are scarce and mostly limited to case reports.^{2,8} This study reported an early mortality rate of 3.57% for RHM resection with satisfactory 1-, 2-, and 5-year survival rates. No significant difference in the actuarial survival rates was noted between RHM and LHM resection. Based on this experience, we recommend that surgery for RHM is a safe and effective treatment approach and that RHM is usually curative.

Study Limitations

The present study has some limitations. First, the study only reported single-institutional experience for RHM treatment. To obtain a greater sample size, a multicenter experience is needed. Furthermore, a longer follow-up time is still required for the validation of these findings.

CONCLUSION

RHMs can present with a wide range of symptoms from being asymptomatic to leading to catastrophic consequences. RHM differs from LHM in some clinical characteristics such as sex, asymptomatic rate, and embolization rate. After a diagnosis of RHM is established, prompt surgical resection gives excellent early and mid-term results.

Data Availability: The clinical data used to support the findings of this study are available from the corresponding author upon request.

Ethics Committee Approval: The study was designed as a retrospective data analysis; therefore, ethical committee approval was not warranted.

Informed Consent: Written informed consent about the surgical procedure was obtained from all patients enrolled in this study.

Peer Review: Externally peer-reviewed.

Author Contributions: Concept – Y.L., S.G.; Design – S.G., C.Z., Y.L.; Writing – Y.L.; Supervision – S.G., C.Z.; Data Collection – Y.L., X.L., Z.L., C.L.; Analysis – Y.L., Y.J.; Literature Review – Y.L., Y.J.; Critical Reviews – S.G., C.Z.

Acknowledgment: None.

Declaration of Interests: The authors declared that they have no conflicts of interest regarding this work.

Funding: This study was supported by the Natural Science Foundation of Anhui province (1808085MH279).

REFERENCES

- Saaddeh AM, Hijazi EM, Saadeh NA. Right atrioventricular myxoma presenting with recurrent syncopal attacks. *Am J Case Rep.* 2021;22:e927874. [\[CrossRef\]](#)
- Straw S, Sengupta A, Gantenby VK, et al. An enormous right atrial myxoma highlights the role of echocardiography in heart failure pathways: a case report. *Eur Heart J J Case Rep.* 2022;6(2):c42. [\[CrossRef\]](#)
- Mahavar RK, Arora D, Singh A, Mishra M. Recurrent cardiac myxoma: a case report. *Ann Card Anaesth.* 2021;24(4):490-492. [\[CrossRef\]](#)
- Henmi S, Salica A, Scaffa R, D'Aleo S, Wolf LG, De Paulis R. Excision of large right atrial myxoma through a right mini thoracotomy. *J Surg Case Rep.* 2022;2022(5):rjac182. [\[CrossRef\]](#)
- Vondran M, Ghazy T, András TB, Rastan AJ. ST-segment elevation myocardial infarction and right atrial myxoma. *Thorac Cardiovasc Surg Rep.* 2022;11(1):e33-e37. [\[CrossRef\]](#)
- Naser N, Hadziomerovic N, Bahram D, Kacila M, Pandur S. Giant right atrial myxoma with symptoms of right heart failure. *Med Arch.* 2021;75(1):66-68. [\[CrossRef\]](#)
- Geweher DM, Neiverth A, Cavalcanti MS, et al. Fast growth rate of a right atrial myxoma. *Einstein (Sao Paulo).* 2022;20:eRC6478. [\[CrossRef\]](#)
- Li H, Guo H, Xiong H, Xu J, Wang W, Hu S. Clinical features and surgical results of right atrial myxoma. *J Card Surg.* 2016;31(1):15-17. [\[CrossRef\]](#)
- Vaideswar P, Gupta R, Mishra P, Lanjewar C, Raut A. Atypical cardiac myxomas: a clinicopathologic analysis and their comparison to 64 typical myxomas. *Cardiovasc Pathol.* 2012;21(3):180-187. [\[CrossRef\]](#)
- Munirathinam GK, Kumar B, Singh H. Role of transesophageal echocardiography in the recurrent biatrial myxoma of uncommon origin. *Ann Card Anaesth.* 2022;25(1):85-88. [\[CrossRef\]](#)
- Reynen K. Cardiac myxomas. *N Engl J Med.* 1995;333(24):1610-1617. [\[CrossRef\]](#)
- Gošev I, Paić F, Durić Z, et al. Cardiac myxoma the great imitators: comprehensive histopathological and molecular approach. *Int J Cardiol.* 2013;164(1):7-20. [\[CrossRef\]](#)
- Singhal P, Luk A, Rao V, Butany J. Molecular basis of cardiac myxomas. *Int J Mol Sci.* 2014;15(1):1315-1337. [\[CrossRef\]](#)
- Aggarwal SK, Barik R, Sarma TC, et al. Clinical presentation and investigation findings in cardiac myxomas: new insights from the developing world. *Am Heart J.* 2007;154(6):1102-1107. [\[CrossRef\]](#)
- Lin Y, Xiao J, Chen J, et al. Treating cardiac myxomas: a 16-year Chinese single-center study. *J Cardiovasc Med (Hagerstown).* 2016;17(1):44-53. [\[CrossRef\]](#)
- Dias RR, Fernandes F, Ramires FJ, Mady C, Albuquerque CP, Jatene FB. Mortality and embolic potential of cardiac tumors. *Arq Bras Cardiol.* 2014;103(1):13-18. [\[CrossRef\]](#)
- Sugeng L, Lang RM. Atypical cardiac myxomas. *Echocardiography.* 2004;21(1):43-47. [\[CrossRef\]](#)
- Braun S, Schrötter H, Reynen K, Schwencke C, Strasser RH. Myocardial infarction as complication of left atrial myxoma. *Int J Cardiol.* 2005;101(1):115-121. [\[CrossRef\]](#)
- He K, Bian L, Liang W, et al. Fire at the gate ruins fish: pulmonary embolism caused by right atrial myxoma. *Cardiovasc J Afr.* 2022;33:1-5. [\[CrossRef\]](#)
- Shah IK, Dearani JA, Daly RC, et al. Cardiac myxomas: A 50-year experience with resection and analysis of risk factors for recurrence. *Ann Thorac Surg.* 2015;100(2):495-500. [\[CrossRef\]](#)
- Lu F, Xin Y, Xu JJ, et al. Minimally invasive myxoma resection: a single-center 5 years' experience. *Heart Surg Forum.* 2022;25(3):E353-E357. [\[CrossRef\]](#)

22. Zhao F, Chen T, Tang Y, Chen Q, Jiang N, Guo Z. Totally thoracoscopic surgery for treating left atrial myxoma. *Med (Baltim)*. 2021;100(45):e27819. [\[CrossRef\]](#)
23. Deng L, Zhang GW, Liu ZH, Meng WX, Liu HY. Totally thoracoscopic surgery for atrial myxomas resection and atrial septal defect repair. *Eur Rev Med Pharmacol Sci*. 2017;21(3):569-575.
24. Karagöz A, Keskin B, Karaduman A, Tanyeri S, Adademir T. Multidisciplinary approach to right ventricular myxoma. *Braz J Cardiovasc Surg*. 2021;36(2):257-260. [\[CrossRef\]](#)
25. Garatti A, Nano G, Canziani A, et al. Surgical excision of cardiac myxomas: twenty years experience at a single institution. *Ann Thorac Surg*. 2012;93(3):825-831. [\[CrossRef\]](#)
26. Pinede L, Duhaut P, Loire R. Clinical presentation of left atrial cardiac myxoma: a series of 112 consecutive cases. *Med (Baltim)*. 2001;80(3):159-172. [\[CrossRef\]](#)