



OPEN ACCESS

Cavitron Ultrasonic Surgical Aspirator Makes it Easier for Neurosurgeons. What About Pathologists?

Kavitron Ultrasonik Cerrahi Aspiratör Beyin Cerrahlarının İşini Kolaylaştırır. Peki Ya Patologlar?

✉ Mahmut Çamlar¹, ✉ Mustafa Eren Yüncü¹, ✉ Emel Ebru Pala², ✉ Nijat Bayramlı¹, ✉ Ali Karadağ¹, ✉ Merve Ören³, ✉ Füsün Demircivi Özer¹, ✉ Nurperi Gazioğlu⁴

¹University of Health Sciences Turkey, İzmir Tepecik Education and Training Hospital, Clinic of Neurosurgery, İzmir, Turkey

²University of Health Sciences Turkey, İzmir Tepecik Education and Training Hospital, Clinic of Pathology, İzmir, Turkey

³Istanbul University Faculty of Medicine, Department of Public Health, İstanbul, Turkey

⁴Demiroğlu Bilim University Faculty of Medicine, Department of Neurosurgery, İstanbul, Turkey

Cite as: Çamlar M, Yüncü ME, Pala EE, Bayramlı N, Karadağ A, Ören M, Demircivi Özer F, Gazioğlu N. Cavitron Ultrasonic Surgical Aspirator Makes it Easier for Neurosurgeons. What About Pathologists? J Tepecik Educ Res Hosp 2023;33(2):197-202

Abstract

Objective: In recent years, the cavitron ultrasonic surgical aspirator has become an indispensable surgical tool for many neurosurgeons. The aim of the present study was to determine the relationship between the use of the cavitron ultrasonic surgical aspirator and the volume of the material obtained for pathological studies.

Methods: The study was conducted with data from 80 consecutive patients undergoing surgical removal of a brain tumor between 2015 and 2019. Clinical records were analyzed retrospectively. Preoperative and postoperative tumor volume measurements were performed on magnetic resonance images using the Aquarius Intuition Client Viewer program available on our picture archiving and communication system. Excised tumor volumes were calculated. The effect of using the cavitron ultrasonic surgical aspirator on the amount of excised tissue, histopathological diagnosis, and excision time of the material sent to our pathology department for histopathological examination was calculated.

Results: Mean age was 52.9 years. Preoperative tumor volumes and resected tumor volumes were significantly higher in group 1 ($p=0.026$; 0.03 respectively). Operation time spent per excised tumor volume was significantly shorter in group 1 ($p=0.005$). The amount of material sent to pathology was higher in group 2 ($p=0.026$). There were no complications related to the resection using the cavitron ultrasonic surgical aspirator and it was found to be useful for tumor removal.

Conclusion: The cavitron ultrasonic surgical aspirator is a highly helpful tool for surgical intervention. This method based on aspiration may have some negative effects on pathological specimens if cavitron ultrasonic surgical aspirator aspirate material not transferred to the pathology department.

Keywords: Brain, cavitron ultrasonic surgical aspirator, pathology, resection, tumor



Address for Correspondence/Yazışma Adresi: Mahmut Camlar Assoc. Prof, University of Health Sciences Turkey, İzmir Tepecik Education and Training Hospital, Clinic of Neurosurgery, İzmir, Turkey

Phone: +90 505 271 46 27 **E-mail:** drcamlar@gmail.com

ORCID ID: orcid.org/0000-0002-6467-0172

Received/Geliş tarihi: 30.04.2022

Accepted/Kabul tarihi: 12.05.2022

Öz

Amaç: Son yıllarda kavitron ultrasonik cerrahi aspiratör birçok beyin cerrahisi için vazgeçilmez bir cerrahi alet haline gelmiştir. Bu çalışmanın amacı, kavitron ultrasonik cerrahi aspiratör kullanımı ile patolojik incelemeler için elde edilen materyal hacmi arasındaki ilişkiyi belirlemektir.

Yöntem: Çalışma, 2015-2019 yılları arasında beyin tümörü cerrahisi uygulanan ardışık 80 hastanın verileri ile gerçekleştirildi. Klinik kayıtlar retrospektif olarak incelendi. Ameliyat öncesi ve ameliyat sonrası tümör hacmi ölçümleri, resim arşivleme ve iletişim sistemimizde bulunan Aquarius Intuition Client Viewer programı kullanılarak manyetik rezonans görüntüleri üzerinde yapıldı. Eksize edilen tümör hacimleri hesaplandı. Kavitron ultrasonik cerrahi aspiratör kullanımının eksize edilen doku miktarına, histopatolojik tanıya ve histopatolojik inceleme için patoloji bölümümüze gönderilen materyalin ekzyon süresine etkisi hesaplandı.

Bulgular: Ortalama yaş 52,9 idi. Ameliyat öncesi tümör hacimleri ve rezeksiyon edilen tümör hacimleri grup 1'de anlamlı olarak yüksekti (sırasıyla $p=0,026$; $0,03$). Eksize edilen tümör hacmi başına harcanan operasyon süresi, grup 1'de anlamlı olarak daha kısaydı ($p=0,005$). Patolojiye gönderilen materyal miktarı grup 2'de daha yüksekti ($p=0,026$). Kavitron ultrasonik cerrahi aspiratör kullanılarak yapılan rezeksiyona bağlı herhangi bir komplikasyon görülmedi ve tümör çıkarılmasında faydalı bulundu.

Sonuç: Kavitron ultrasonik cerrahi aspiratör, cerrahi müdahale için oldukça yardımcı bir araçtır. Aspirasyona dayalı bu yöntem, kavitron ultrasonik cerrahi aspiratör aspirasyonu materyalinin patoloji bölümüne aktarılmaması durumunda patolojik örnekler üzerinde bazı olumsuz etkilere neden olabilir.

Anahtar Kelimeler: Beyin, kavitron ultrasonik cerrahi aspiratör, patoloji, rezeksiyon, tümör

Introduction

Microneurosurgical approaches require high surgical precision due to the proximity of neural and vascular structures. The cavitron ultrasonic surgical aspirator (CUSA) is a sensitive tool used for safe excision without damaging the surrounding normal tissues. The CUSA performs cavitation by ultrasonic waves and vibrations, which destroy the hydrogen bonds resulting in the denaturation of the protein contents of tissues^(1,2). The concurrently used irrigation system of the CUSA removes the disintegrated tissues and provides a clear surgical site, resulting in great convenience. It makes surgery safer, especially for deeper lesions located around important structures and vessels^(2,3). The structure and stiffness of the pathological tissues of brain tumors are not the same. These microsurgical characteristics may pose a problem in the excision of tumors depending on the location. Pituitary surgery is an example of this type of procedure, and CUSA is very helpful, especially in pituitary surgery. In literature, decreased blood loss and surgical times during surgery with the use of CUSA are emphasized^(4,5). These listed advantages, which are crucial for the surgeon and the anesthesia team, are valid reasons for surgeons to prefer CUSA^(4,5).

The diagnosis and treatment of patients do not end with surgery. Some diagnoses can be challenging to establish, and histopathological evaluation of the pathological specimen should be correlated with the surgical findings. Pathological specimens obtained during surgery are as important as the surgical details in the treatment process^(2-4,6).

A detailed study investigating the effect of CUSA use on pathological material and diagnosis has not been published in the literature. For this reason, we investigated the advantages and disadvantages of using CUSA for both neurosurgeons and pathologists.

Materials and Methods

This study was approved by the University of Health Sciences Turkey, İzmir Tepecik Education and Training Hospital Ethics Committee (decision no: 2019/18-20, date: 26.12.2019), and the procedures followed were in accordance with Declaration Helsinki. A total of 80 consecutive patients who underwent surgical excision of a brain tumor between 2015 and 2019 were retrospectively evaluated (Table 1). Medicine records of patients were investigated. Patients who underwent biopsy only were excluded from the study. Patients were divided into two groups. Group 1 consisted of 40 consecutive patients in whose operations CUSA was used. Group 2 consisted of 40 patients who underwent surgery with conventional methods without using CUSA. Preoperative tumor volumes of the patients were recorded from preoperative magnetic resonance imaging (MRI). Postoperative residual tumor amounts were calculated using the Aquarius iNtuition Viewer program from MRI examinations performed within the first 48 h after surgery. Excised tumor volumes were calculated for each patient. Groups were compared with respect to the volume of the material excised for pathology and surgical time.

Statistical Analysis

The Statistical Package for Social Science (SPSS) version 16.0 for Windows (Location, State?) was used for statistical analysis. Chi-square tests and Spearman tests were performed for nonparametric data. Student's t-test and Pearson correlation test were used for parametric data. A p value of <0.05 was set as statistically significant.

Results

There were 44 male and 36 female patients in the cohort. Mean age was 52.9 (2-81) years. The mean age and sex distributions of groups 1 and 2 were similar ($p=0.802$, $p=0.369$, respectively). Preoperative unsuspected tumor volumes and resected tumor volumes were significantly higher in group 1 ($p=0.026$; 0.03 respectively). There was no statistically significant difference between the number of tumors sent to pathology between the groups. When tumor volume sent to pathology was considered as a ratio of resected tumors, statistically significantly higher rates were detected in group 2 ($p=0.026$). There was no difference in surgical times between groups 1 and 2 ($p=0.156$). However, the higher volume of excision in group 1 may have affected this analysis; therefore, we calculated the time per excised material and found that the operation time spent per excised tumor volume was significantly shorter in group 1 ($p=0.005$).

Table 1. The number of patients according to tumor types. Group 1 is operated with using CUSA, group 2 is without using CUSA

Diagnosis	Group 1 (with CUSA)	Group 2 (without CUSA)
Meningioma	11	10
Pilocytic astrocytoma	-	1
Diffuse/anaplastic astrocytoma	2	1
Glioblastoma multiforme	11	7
Metastatic carcinoma	5	9
Hypophysis adenoma	6	1
Medulloblastoma	3	2
Ependymoma	-	1
Cystic/vascular lesion	-	3
Lymphoma/encephalitis	1	1
Hemangioblastoma	-	2
Craniopharyngioma	1	-

CUSA: Cavitron ultrasonic surgical aspirator

From the point of histopathology, the amount of excised material in group 1 was sufficient for definitive diagnosis. The quality of pathology slide preparation was also similar to that of group 2 (Figures 1, 2). The histopathological diagnoses of both groups are documented in Table 2. There was various diagnostic entities in the groups. The excised tissue was inadequate in only two cases from group 2, both having cerebellar cystic lesions on MRI.

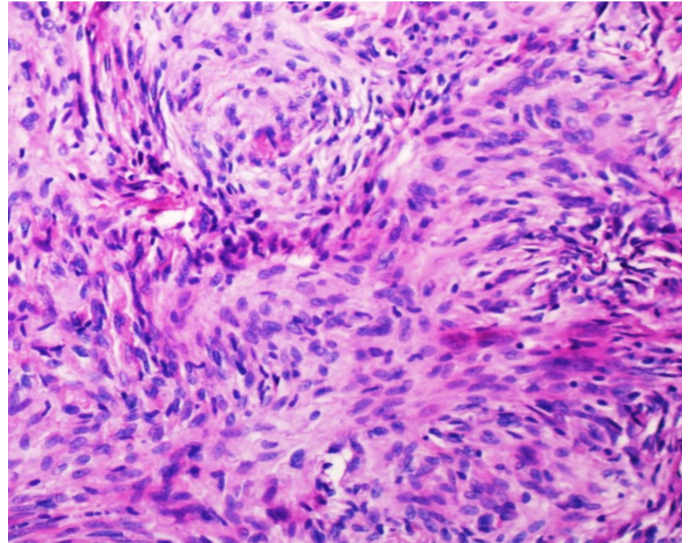


Figure 1. Lobulated arrangement of meningothelial tumor cells with pale, round nuclei in meningioma (HE, 20x)

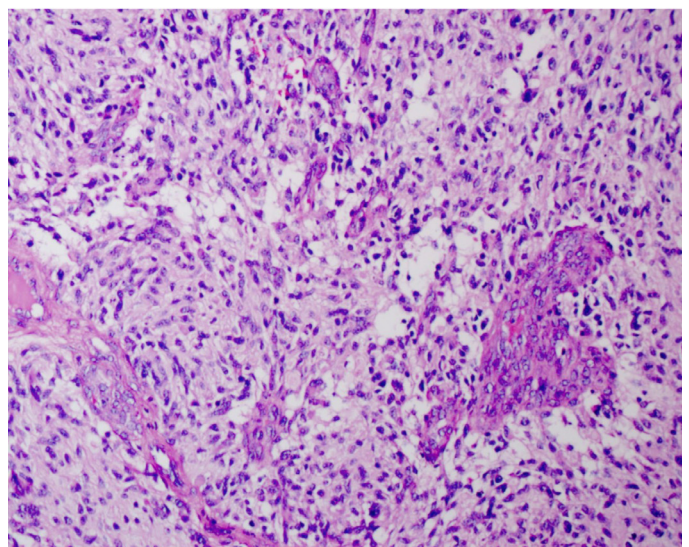


Figure 2. Vascular endothelial proliferation and focal edematous areas in glioblastoma (HE, 20x)

Table 2. Comparison of the pre-operative and postoperative effects of using CUSA

	CUSA (-)	CUSA (+)	p
	Mean ± SD Median (IQR)	Mean ± SD Median (IQR)	
Age	53.4±16.7	52.4±17.9	0.802*
The volume of pathology	3694 (8839)	2625 (9850)	0.661**
Pre-operative tumor volume	53412.8 (88732)	94506.6 (196732)	0.026**
Post-operative tumor volume	0 (3458)	2831.6 (7909)	0.006**
The time of surgery	215±67	193.6±59.8	0.136*
Excision	52464.6 (88131)	87415.6 (194191)	0.03**
Pathologic specimen volume rate	10.3 (19.2)	5.1 (11.5)	0.026**
Surgical time per excised volume (cm ³ /min)	4.9 (12.5)	2.1 (8.3)	0.005**

*t-test, **Mann-Whitney U test, CUSA: Cavitron ultrasonic surgical aspirator, SD: Standard deviation

Discussion

It is well known that surgery is an essential component in the treatment of brain tumors. In recent years, new surgical techniques and various novel instruments that resect brain tumors have been defined. Instruments used in neurosurgical practice and their effects on surgical methods have been reported before⁽⁷⁾. According to some researchers, inherent surgical technique is critical, but new technological advances have augmented what is possible⁽⁷⁾. CUSA is one of such instruments. Its working principle is explained by two main mechanisms. The first one includes cavitation, and the second mechanism includes vibration and suction characteristics. These allow neoplastic tissues to dissociate from healthy tissues gently^(8,9). This is one of the advantages of CUSA. According to Baddour et al.⁽⁴⁾, CUSA use resulted in a significant decrease in surgical times and decreased blood loss. These results explain the importance of this instrument for neurosurgeons. In addition, the amount of safely resected tumor volume is increased. This is especially true for harder solid tumors in relatively difficult to access surgical locations, such as hard pituitary adenoma^(4,10). The CUSA has two rupturing effects at the tissue interface as cavitation and suction. These characteristics of CUSA resolve many surgical problems encountered with older ultrasonic aspiration units. Tissues with weak intracellular bonds are easy to fragment, and tissues with tight intracellular bonds are difficult to fragment. As predicted, the fragmentation rate depends on the amplitude of the system. As understood, the type of tumor tissue is one of the most important parameters to evaluate the effectiveness of CUSA. It has a high maneuverability for cortical supratentorial lesions and is thought that this system can be adapted for endoscopic approaches for anteromedial and posterolateral skull base lesions.

Probably, in the near future, the scope of the ultrasonic bone aspirator may be expanded and can be more successfully used in multiple fields^(4,9,10).

In this study, using CUSA significantly reduced surgical time and increased the volume of excised tumor. Although there was no statistically significant difference in surgical times between the two groups, excised tumor volumes were actually higher in group 1. Since the amount of tumor excised was also higher, the volume of tumor excised per unit time was higher. We also investigated whether there was a decrease in the amount of bleeding, but retrospective data were not available in our documents.

Decreasing surgical time in neurosurgery is crucial for better neurological and systemic recovery. In practice, one of the first reasons surgeons use CUSA for tumor excision is safer and quicker surgery. Second, they consider adequate pathologic specimens. In our study, there was no difference in tumor volumes sent to the pathology laboratory between the groups. However, in group 1, preoperative tumor volumes and excised tumor volumes were higher. After sufficient tumor is sent for pathological specimen by the surgeon, the rest of the tumor is removed with the CUSA and is discarded^(8,11).

Finally, it is necessary to consider whether CUSA eases the process for the pathologist as well. Many neurosurgeons using the CUSA think that a sufficient portion of the tumor is allocated to the pathology laboratory. However, it should be kept in mind that tumor tissues contain heterogeneous areas in terms of morphology and tumor grade. Even the smallest amount of tissue is essential for definitive diagnosis and molecular investigation. Different pathological diagnoses may be achieved by biopsy from different points of a brain tumor of a single patient as reported by Forshew et al.⁽¹¹⁾

which is an excellent summary of the heterogeneity of brain tumors and the importance of even a miniscule portion of the pathology specimen. This situation is also demonstrated at the molecular level with clonal analysis^(12,13). Diagnostic accuracy can be controversial with small pathological specimens as obtained by a biopsy. This point calls for reconsideration of the aspirate material obtained using the CUSA that was removed surgically but was not sent for the pathological examination. In our study, when the tumor volume sent to pathology was considered as a ratio of resected tumor, it was higher in group 2. Although the excised material was diagnostic in all cases of group 1, tumor heterogeneity and molecular tests may require more material. Therefore, the aspirate material should be collected into a disposable container and transferred to the laboratory as a separate specimen.

The morphology of the tissue removed by CUSA may be slightly inferior compared to that removed by conventional biopsy, especially fragile tissue such as that seen in gliomas. Characteristic round nuclei and perinuclear haloes are clearly seen in oligodendroglioma cases. Therefore, artefactual microcyst formation and more edema can be observed. In CUSA specimens, calcispherules can be separated from the tumor mass and concentrated within the fibrinous debris⁽⁶⁾. Meningiomas, schwannomas, and metastatic carcinomas can be better preserved with the CUSA. A positive correlation between the greater amount of excised tumor material and accurate histological grading of low-grade gill tumors has previously been reported^(14,15). The presence of glioblastoma stem cells in the content of this ultrasonic surgical aspirate has been shown by Benhan et al.⁽¹⁶⁾ The importance of this aspiration material has been published. This material, including cancer stem cells, contains many important diagnostic tissues^(6,15,16).

In this study, using CUSA increased the amount of tumor removed and decreased the amount of pathology. In addition, our study is one of the first to investigate the relationship between the utilization of CUSA and pathological specimen volumes.

Study Limitations

We think that when our study is conducted with a larger patient population, we will find that the surgical time will be statistically significantly shorter in patients using CUSA. At the same time, we could not evaluate the effect of CUSA on bleeding because we could not access data on the amount of bleeding during surgery. We think that these are the most

important limitations of our study. We think that the accuracy of our inferences can be demonstrated more clearly when research is conducted with a larger patient population and more data.

Conclusion

We hypothesized that using the CUSA reduces the amount sent to pathology specimens but also reduces surgical time. According to our study, strong evidence to support our hypothesis was found. The aspirate material fragmented by the CUSA should be collected into a disposable plastic bottle, and the fragments recovered by a suction device and collected in the bottle should also be transferred to the laboratory as a separate specimen to use for pathological studies.

Ethics

Ethics Committee Approval: This study was approved by the University of Health Sciences Turkey, İzmir Tepecik Education and Training Hospital Ethics Committee (decision no: 2019/18-20, date: 26.12.2019), and the procedures followed were in accordance with Declaration Helsinki.

Informed Consent: Retrospective study.

Peer-review: Externally peer-reviewed.

Authorship Contributions

Concept: A.K., F.D.Ö., N.G., Design: A.K., F.D.Ö., N.G., Data Collection or Processing: M.E.Y., E.E.P., N.B., Analysis or Interpretation: M.Ç., M.E.Y., A.K., M.Ö., Literature Search: M.Ç., N.B., M.Ö., Writing: M.Ç.

Conflict of Interest: No conflict of interest was declared by the authors.

Financial Disclosure: The authors declared that this study received no financial support.

References

1. Vernon D, Lobo BC, Ting JY. Application of Ultrasonic Aspirators in Rhinology and Skull Base Surgery. *Otolaryngol Clin North Am* 2017;50:607-16.
2. Labanca M, Azzola F, Vinci R, Rodella LF. Piezoelectric surgery: twenty years of use. *Br J Oral Maxillofac Surg* 2008;46:265-9.
3. Sheitoyan-Pesant C, Alarie I, Iorio-Morin C, Mathieu D, Carignan A. An outbreak of surgical site infections following craniotomy procedures associated with a change in the ultrasonic surgical aspirator decontamination process. *Am J Infect Control* 2017;45:433-5.
4. Baddour HM, Lupa MD, Patel ZM. Comparing use of the Sonopet^(®) ultrasonic bone aspirator to traditional instrumentation during the endoscopic transsphenoidal approach in pituitary tumor resection. *Int Forum Allergy Rhinol* 2013;3:588-91.

5. Bruggers S, Sindwani R. Evolving trends in powered endoscopic sinus surgery. *Otolaryngol Clin North Am* 2009;42:789-98.
6. Preston JK, Masciopinto J, Salamat MS, Badie B. Tumour cell dispersion by the ultrasonic aspirator during brain tumour resection. *Br J Neurosurg* 1999;13:486-9.
7. Fatemi P, Zhang M, Miller KJ, Robe P, Li G. How Intraoperative Tools and Techniques Have Changed the Approach to Brain Tumor Surgery. *Curr Oncol Rep* 2018;20:89.
8. Jallo GI. CUSA EXcel ultrasonic aspiration system. *Neurosurgery* 2001;48:695-7.
9. Forterre F, Dickomeit M, Senn D, Gorgas D, Spreng D. Microfenestration using the CUSA Excel ultrasonic aspiration system in chondrodystrophic dogs with thoracolumbar disk extrusion: a descriptive cadaveric and clinical study. *Vet Surg* 2011;40:34-9.
10. Tang H, Zhang H, Xie Q, et al. Application of CUSA Excel ultrasonic aspiration system in resection of skull base meningiomas. *Chin J Cancer Res* 2014;26:653-7.
11. Forshew T, Lewis P, Waldman A, et al. Three different brain tumours evolving from a common origin. *Oncogenesis* 2013;2:e41.
12. Aubry M, de Tayrac M, Etcheverry A, et al. Correction: From the core to beyond the margin: a genomic picture of glioblastoma intratumor heterogeneity. *Oncotarget* 2016;7:67685.
13. Aubry M, de Tayrac M, Etcheverry A, et al. From the core to beyond the margin: a genomic picture of glioblastoma intratumor heterogeneity. *Oncotarget* 2015;6:12094-109.
14. Diffuse low-grade gliomas in adults : natural history, interaction with the brain, and new individualized therapeutic strategies. New York: Springer; 2013.
15. Golub JS, Weber JD, Leach JL, et al. Feasibility of the Ultrasonic Bone Aspirator in Retrosigmoid Vestibular Schwannoma Removal. *Otolaryngol Head Neck Surg* 2015;153:427-32.
16. Behnan J, Stangeland B, Langella T, Finocchiaro G, Murrell W, Brinchmann JE. Ultrasonic Surgical Aspirate is a Reliable Source For Culturing Glioblastoma Stem Cells. *Sci Rep* 2016;6:32788.