

Fine Needle Aspiration Cytology (FNAC) vs. Tru-cut Biopsy in Liver with Iron Overload: An Experimental Study

Demir Yükü Artmış Karaciğerde İnce İğne Aspirasyon Sitolojisi (İİAS) ve Tru-cut Biyopsisi: Deneysel Bir Çalışma

Yasemen Adalı¹, Hüseyin Avni Eroğlu², Mustafa Makav³, Sunay Sibel Karayol⁴, Gülname Fındık Güvendi⁵, Mustafa Gök⁶

¹İzmir University of Economics Faculty of Medicine, Department of Pathology, İzmir, Turkey

²Çanakkale Onsekiz Mart University Faculty of Medicine, Department of Physiology, Çanakkale, Turkey

³Kafkas University Faculty of Veterinary Medicine, Department of Physiology, Kars, Turkey

⁴Harran University Faculty of Medicine, Department of Radiology, Şanlıurfa, Turkey

⁵Rize Recep Tayyip Erdoğan University Faculty of Medicine, Department of Pathology, Rize, Turkey

⁶Aydın Adnan Menderes University Faculty of Medicine, Department of Radiology, Aydın, Turkey

Cite as: Adalı Y, Eroğlu HA, Makav M, Karayol SS, Fındık Güvendi G, Gök M. Fine Needle Aspiration Cytology (FNAC) vs. Tru-cut Biopsy in Liver with Iron Overload: An Experimental Study. Anatol J Gen Med Res 2023;33(3):310-5

Abstract

Objective: Fine needle aspiration cytology (FNAC) is safer, simpler, faster and cost effective, compared to tru-cut biopsy, and patient compliance is generally better. There is not much data on the use of FNAC, which is used in many organs and lesions, in parenchymal diseases in the liver. Therefore, in this study, the benefit of FNAC in showing iron deposition and injury of liver is evaluated.

Methods: There were 2 control groups in the study. At the end of the study, FNAC and tru-cut biopsy samples were taken from these groups, where no administration was performed. FNAC and tru-cut biopsy procedures were also performed to the study groups after the iron overload was created by intraperitoneal iron dextran (88 mg/kg) administration for 28 days. Hepatocyte injury, inflammation and iron deposition were evaluated histopathologically in the preparations. The sensitivity, specificity, positive and negative predictivity and diagnostic accuracy of both methods were calculated based on the hepatectomy material.

Results: In hepatocyte injury; sensitivity (60%), diagnostic accuracy (66.7%) and negative predictivity (50%) were found to be significantly higher in tru-cut group. It was observed that the methods were not superior to each other in the evaluation of inflammation, and FNAC almost approached tru-cut biopsy rates (100%) with a sensitivity of 83.3% and diagnostic accuracy in iron deposition.

Conclusion: In iron-induced liver damage, the gold standard should be tissue examination, so tru-cut biopsy must be the first choice. However, based on the present study results, it is suggested that FNAC may be preferred over more invasive options in cases where tru-cut biopsy can not be used in terms of susceptibility to bleeding, situations where surgical accessibility is not available, patient orientation and cooperation is poor, or in presence of different accompanying diseases.

Keywords: Liver, fine needle aspiration cytology, FNAC, tru-cut, iron overload



Address for Correspondence/Yazışma Adresi: Assoc. Prof. Yasemen Adalı, İzmir University of Economics Faculty of Medicine, Department of Pathology, İzmir, Turkey
Phone: +90 506 343 71 99 **E-mail:** yasemenadali@hotmail.com
ORCID ID: orcid.org/0000-0002-8004-7364

Received/Geliş tarihi: 22.12.2021
Accepted/Kabul tarihi: 02.06.2022



Copyright© 2023 The Author. Published by Galenos Publishing House on behalf of University of Health Sciences Turkey, İzmir Tepecik Training and Research Hospital. This is an open access article under the Creative Commons AttributionNonCommercial 4.0 International (CC BY-NC 4.0) License.

Öz

Amaç: İnce iğne aspirasyon sitolojisi (İİAS) tru-cut biyopsiye göre daha güvenli, basit, hızlı ve uygun maliyetlidir ve hasta uyumu genellikle daha iyidir. Birçok organda kullanılan İİAS'nin karaciğerdeki parankimal hastalıklarda kullanımına ilişkin fazla veri yoktur. Bu nedenle bu çalışmada İİAS'nin demir birikimini ve karaciğer hasarını göstermedeki faydası değerlendirilmiştir.

Yöntem: Çalışmada 2 kontrol grubu yer aldı. Çalışma sonunda herhangi bir uygulama yapılmayan bu gruplardan İİAS ve tru-cut biyopsi örnekleri alındı. Yirmi sekiz gün süreyle intraperitoneal demir dekstran (88 mg/kg) verilerek demir yüklenmesi oluşturulduktan sonra çalışma gruplarına İİAS ve tru-cut biyopsi işlemleri de yapıldı. Preparatlarda hepatosit hasarı, enflamasyon ve demir birikimi histopatolojik olarak değerlendirildi. Hepatektomi materyaline göre her iki yöntemin duyarlılığı, özgüllüğü, pozitif ve negatif prediktifliği ve tanısal doğruluğu hesaplandı.

Bulgular: Hepatosit hasarında; sensitivite (%60), tanısal doğruluk (%66,7) ve negatif öngörü (%50) tru-cut grubunda anlamlı olarak daha yüksek bulundu. Enflamasyonun değerlendirilmesinde yöntemlerin birbirine üstün olmadığı ve İİAS'nin demir birikiminde %83,3 duyarlılık ve tanısal doğrulukla tru-cut biyopsi oranlarına (%100) neredeyse yaklaştığı görüldü.

Sonuç: Demire bağlı karaciğer hasarında altın standart doku incelemesi olmalı, bu nedenle tru-cut biyopsi ilk seçenek olmalıdır. Ancak mevcut çalışma sonuçlarına dayanarak tru-cut biyopsinin kullanılmadığı kanamaya yatkınlık, cerrahi erişimin mümkün olmaması, eşlik eden farklı hastalıkların varlığı ya da hasta oryantasyonu ve kooperasyonunun zayıf olduğu durumlarda İİAS'nin daha invaziv seçeneklere göre tercih edilebileceği önerilmektedir.

Anahtar Kelimeler: Karaciğer, ince iğne aspirasyon sitolojisi, İİAS, Tru-cut, demir yükü artışı

Introduction

Diagnostic fine needle aspiration cytology (FNAC) and tru-cut biopsies are widely used nowadays⁽¹⁻³⁾. While FNAC is used more frequently in routine practice in secretory organs with loose stroma, tru-cut biopsies are mostly preferred in solid areas. Thyroid FNAC has an important place in the guideline in terms of diagnosis and treatment planning⁽⁴⁾, on the other hand, tru-cut biopsies are applied mostly as in the evaluation of hepatitis in the liver tissue⁽⁵⁾. However, especially in epithelial tumors, because the adhesion of tumor cells to each other is weak, FNAC is also used in cases of malignancy located in the liver^(6,7).

When FNAC and tru-cut biopsy are compared, complications such as bleeding, hematoma, pain, and rupture are more likely to be seen in tru-cut biopsy⁽⁸⁾. Patient compliance is generally better in FNAC, which is safer, simpler, faster and cost effective⁽⁹⁾. However, there are not many data regarding the use of FNAC in parenchymal diseases in the liver, except for mass lesions located in the liver^(5,10).

There are many diseases that cause iron deposition in the liver⁽¹¹⁾. Increased iron use or transfusion-related conditions and hepatitis C infections are among the diseases associated with iron overload, in which secondary accumulations are involved in the etiology rather than primary diseases⁽¹¹⁾. Tru-cut biopsies are used in routine practice to evaluate the iron deposition in the liver and its effects in these diseases. In this study, the benefit of FNAC, which is rarely used except in cases with suspected neoplasia in the liver, in showing iron deposition and liver injury caused by iron overload was evaluated.

Materials and Methods

In the study, a total of 24 female Wistar Albino rats, 4-6 months old, weighing 190-250 g, were used, which were obtained from Atatürk University Experimental Animal Breeding Unit. Ethical approval for the study was obtained from Kafkas University Animal Experiments Local Ethics Committee (ethical approval number KAU-HADYEK-2016/053). The animals were fed ad-libitum until the time of study, maintained at room temperature of approximately 25 °C, in an environment with adjustable light-dark cycle for 12 hours and with ventilation. The animals were divided into 4 groups according to their weight, including 6 rats in each group.

These groups were:

Group I (Control FNAC): The group in which FNAC was applied after feeding ad-libitum for 28 days without any administration,

Group II (Control tru-cut): The group in which tru-cut biopsy was applied after feeding ad-libitum for 28 days without any administration,

Group III (Iron FNAC): The group in which FNAC was performed after iron overload was created by intraperitoneal (i.p.) iron dextran (88 mg/kg) administration for 28 days (6 days a week),

Group IV (Iron tru-cut): The group in which tru-cut biopsy was performed after iron overload was created by i.p. iron dextran (88 mg/kg) administration for 28 days (6 days a week).

At the end of the 28-day study, the animals were prevented from feeding for 12 hours and then sedated by anesthetic agent. Subsequently, the liver was imaged with the linear probe of the ultrasonography device (Toshiba Aplio XG), fine needle aspiration was performed with the help of a 20 mL injector and tru cut biopsy procedures were performed with a 18G tru-cut biopsy needle from areas without vascular structures. After these procedures, the animal's life was terminated with cervical vertebra dislocation in accordance with ethical rules and tissue samples required for the study were taken.

Tissues belonging to tru-cut biopsy and hepatectomy materials were kept in 10% buffered formaldehyde solution for 24 hours and then manually embedded in paraffin after routine tissue processing. For histopathological examinations, 4 μ thickness sections taken from the paraffin blocks and were stained with hematoxylin and eosin (H&E) then examined under a light microscope (Olympus BX46). Obtained cytological materials were prepared as direct smears and were stained with H&E then examined under a light microscope (Olympus BX46). Hepatectomy material sections, tru-cut biopsy sections and FNAC preparations in all groups were evaluated in terms of inflammation, congestion, hepatocyte injury and iron deposition. The sensitivity, specificity, positive and negative predictive values and diagnostic accuracy of FNAC and tru-cut biopsy methods from the data obtained on the parameters examined were compared with the excisional biopsy and calculated according to the formulations given below with the help of Table 1.

Statistical Analysis

SPSS 15.0 package program (SPSS Inc. Released 2006. SPSS for Windows, Version 15.0. Chicago, SPSS Inc.) was used for statistical analysis and $p < 0.05$ was considered statistically significant in the analyzes performed at 95% confidence interval.

Results

In the histopathological examinations of the hepatectomy materials of the rats in group 1 and group 2, no finding other than mild congestion was found. In addition to severe iron deposition in rats in groups 3 and 4, hepatocyte injury, inflammation and congestion in varying degrees were noted in the excision materials. Hepatocyte injury ($p=0.005$), inflammation ($p=0.005$) and iron deposition ($p=0.001$) observed in group 3 and group 4 were statistically significantly higher than in groups 1 and 2. The sensitivity, specificity, diagnostic accuracy, positive predictivity and negative predictivity values of the histopathological results for hepatocyte injury, inflammation and iron deposition parameters of FNAC and tru-cut biopsies performed on rats in groups 3 and 4 are presented in Table 2. The zero values observed in the tables are due to the zero value in one or more of the true positive, true negative, false positive and false negative cases. Histopathological examination photographs of the samples taken from the groups are demonstrated in Figures 1 and 2. Figure 3 shows the short summary of the results as a graphical abstract.

Discussion

Biopsy in liver diseases is described as an excessively invasive and aggressive procedure by patients and general practitioners, but it is essential for the diagnosis of diseases and planning treatment for specialists dealing with the hepatobiliary system^(12,13). In this context, excisional biopsy is seen as a more challenging procedure, while tru-cut biopsy seems more innocent in many aspects, especially for patients. For this reason, although tru-cut biopsy, which is one of the biopsy methods used in liver diseases, is more accepted, there are studies showing that FNAC with less complications and more patient compliance can also be rational^(14,15).

In one of the studies conducted in terms of neoplastic lesions, FNAC was applied to 1756 of 1929 patients with serum α -fetoprotein level < 200 ng/mL⁽¹⁴⁾. In this series

Table 1. The calculation of sensitivity, specificity, positive and negative predictive values

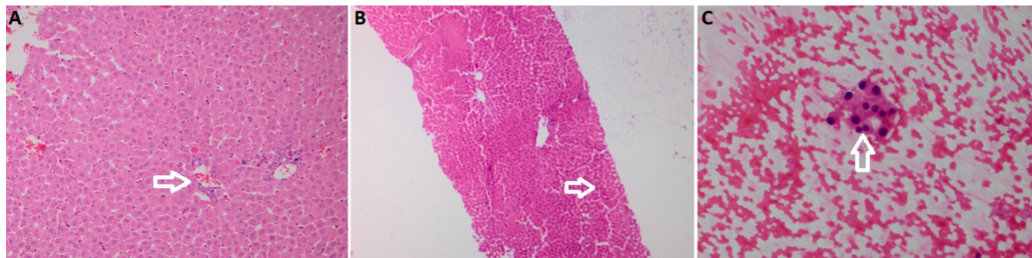
Methods (FNAC or tru-cut)	Gold standard method (excisional biopsy)		Total
	Positive	Negative	
Positive	a (true positive)	b (false positive)	a + b
Negative	c (true negative)	d (false negative)	c + d
Total	a + c	b + d	

Formulas: Sensitivity: $a/(a+c) \times 100$; Specificity: $d/(b+d) \times 100$; positive predictive value: $a/(a+b) \times 100$; negative predictive value: $d/(c+d) \times 100$, FNAC: Fine needle aspiration cytology

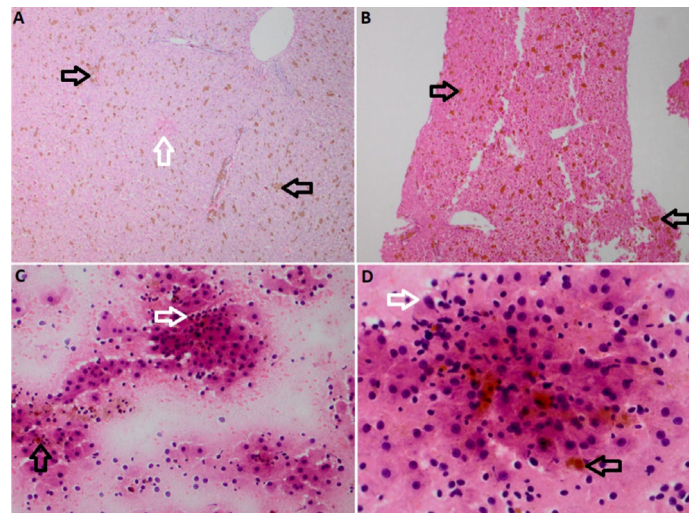
Table 2. Sensitivity, specificity, diagnostic accuracy, positive predictivity and negative predictivity values in the comparison of histopathological materials of the FNAC (group 3) and tru-cut (group 4) groups with respect to hepatocyte injury, inflammation and iron deposition after iron administration

Groups	Diagnostic value parameters	Hepatocyte injury	Inflammation	Iron deposition
Group 3 FNAC/excisional biopsy	Sensitivity	0%	40%	83.3%
	Specificity	100%	100%	0%
	Diagnostic accuracy	16.7%	50%	83.3%
	Positive predictivity	0%	100%	100%
	Negative predictivity	20%	33.3%	0%
Group 4 Tru-cut biopsy/excisional biopsy	Sensitivity	60%	40%	100%
	Specificity	100%	100%	0%
	Diagnostic accuracy	66.7%	50%	100%
	Positive predictivity	100%	100%	100%
	Negative predictivity	50%	33.3%	0%

FNAC: Fine needle aspiration cytology

**Figure 1. A)** Vascular congestion observed in the control group hepatectomy specimen (white arrow), H&E, 200x, **B)** Normal hepatocytes observed in the control group tru-cut biopsy sample (white arrow), H&E, 100x, **C)** Normal hepatocytes observed in the control group FNAC sample (white arrow), H&E, 400x

H&E: Hematoxylin and eosin, FNAC: Fine needle aspiration cytology

**Figure 2. A)** Hepatocyte injury (white arrow) and iron deposition (black arrows) observed in iron group hepatectomy material, H&E, 200x, **B)** Iron deposition observed in iron group tru-cut biopsy material (black arrows), H&E, 200x, **C)** Inflammatory cells (white arrow) and iron deposition observed in the iron group FNAC material (black arrows), H&E, 400x, **D)** Hepatocyte injury (white arrow) and iron deposition observed in the iron group FNAC material (black arrows), H&E, 400x

H&E: Hematoxylin and eosin, FNAC: Fine needle aspiration cytology

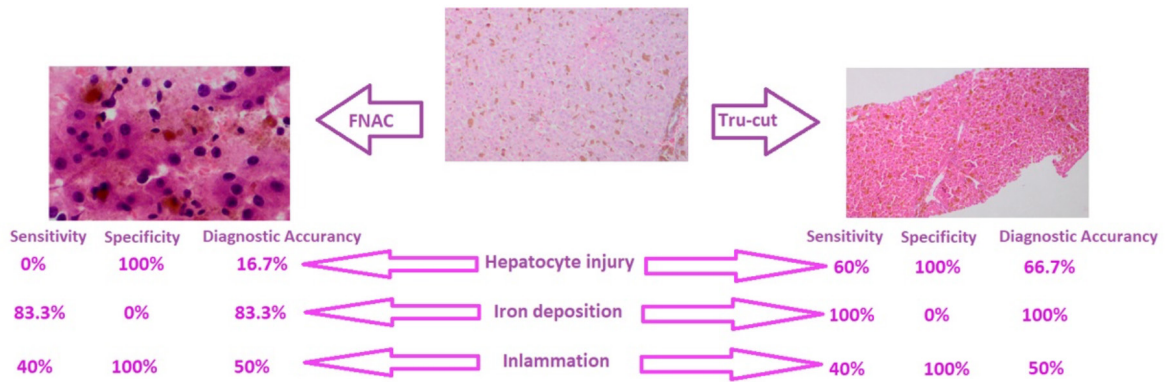


Figure 3. Sum of results presented as a graphical abstract

FNAC: Fine needle aspiration cytology

where 1590 cases were malignant, the sensitivity of FNAC was reported as 92.96%, specificity 100%, positive predictive value 100%, negative predictive value 59.71% and diagnostic accuracy 93.62%⁽¹⁴⁾. Similarly, in a series of 94 patients with liver mass, it was reported that FNAC was diagnostic enough⁽¹⁵⁾. FNAC was found to be effective in distinguishing primary and metastasis in a series of 46 cases, 19 of which were primary liver tumors and no complications were observed during and after the procedure⁽¹⁶⁾. Sattar et al.⁽⁷⁾ stated that the ultrasonography-guided FNAC was a fast, simple, reliable and uncomplicated method for diagnosis in which they evaluated 450 patients with liver masses. Kaçar Özkara and Ozöver Tuneli⁽¹⁷⁾ conducted cytopathological and histopathological analysis in their series of 101 cases of liver mass and found that FNAC had high specificity, especially in hepatic neoplasms, but combined cyto-histopathology was superior. In another study where it was stated that histological correlation with FNAC was provided in 112 cases in 755 liver lesions, it was reported that the diagnostic compliance rates varied between 98.9% and 58.8%⁽¹⁸⁾.

In our study, in which the iron overload, one of the non-neoplastic liver parenchymal diseases, was evaluated, it was observed that the sensitivity, diagnostic accuracy, positive and negative predictivity values of tru-cut biopsy were higher in detecting hepatocyte injury in rats. It was noticed that the methods do not show superiority to each other in the evaluation of inflammation, and in terms of evaluating the iron deposition, FNAC almost approached the tru-cut biopsy rates of 100% with a sensitivity and diagnostic accuracy rate of 83.3%.

Study Limitations

When evaluated in the light of the literature, the use of FNAC may be preferred in benign or malignant lesions that occupy space in the liver. FNAC, which is an effective choice in terms of easy applicability, cheapness and reliability, as well as diagnostic features such as benign-malignant differentiation, primary-metastasis distinction, has limited effectiveness in iron-induced liver damage, one of the parenchymal diseases. Although FNAC, which has variable diagnostic characteristics for different parameters, did not show superiority over biopsy; it has the same sensitivity, specificity, positive and negative predictive values and diagnostic accuracy data as tru-cut biopsy in the evaluation of inflammation. This is thought to be due to the reason that inflammatory cells are not attached to each other like epithelial cells and are easily aspirated. On the other hand, the fact that tru-cut biopsy is superior to FNAC in terms of the evaluated diagnostic values, which is thought to be caused by the hepatocytes holding tightly to each other even if damaged, also supports this theory.

Conclusion

The gold standard must be tissue examination in iron-induced liver damage and therefore tru-cut biopsy should be the priority choice. However, based on the current study results, it is suggested that FNAC may be preferred over more invasive options in cases where tru-cut biopsy cannot be used in terms of susceptibility to bleeding, situations where surgical accessibility is not available, in poor patient orientation and cooperation, or in presence of different accompanying diseases.

Information: This study is presented as a poster presentation in 30. Ulusal Patoloji Kongresi in 20–23 May 2021 in İstanbul.

Ethics

Ethics Committee Approval: Ethical approval for the study was obtained from Kafkas University Animal Experiments Local Ethics Committee (ethical approval number KAU-HADYEK-2016/053 date: 17.02.2016)

Informed Consent: This study is an animal experiment study.

Peer-review: Externally peer-reviewed.

Authorship Contributions

Concept: Y.A., M.G., Design: Y.A., H.A.E., M.M., S.S.K., Data Collection or Processing: Y.A., H.A.E., M.M., G.F.G., S.S.K., Analysis or Interpretation: Y.A., S.S.K., G.F.G., Literature Search: Y.A., M.G., H.A.E., Writing: Y.A., M.G., M.M., G.F.G.

Conflict of Interest: No conflict of interest was declared by the authors.

Financial Disclosure: This study is funded by Kafkas University (project number: 2016-TS-56).

References

- O'Connell AM, Keeling F, Given M, Logan M, Lee MJ. Fine-needle trucut biopsy versus fine-needle aspiration cytology with ultrasound guidance in the abdomen. *J Med Imaging Radiat Oncol* 2008;52:231–6.
- Pagni P, Spunticchia F, Barberi S, Caprio G, Paglicci C. Use of Core Needle Biopsy rather than Fine-Needle Aspiration Cytology in the Diagnostic Approach of Breast Cancer. *Case Rep Oncol* 2014;7:452–8.
- Gupta N, Gupta P, Rajwanshi A. Trucut/Core Biopsy versus FNAC: Who Wins the Match? Thyroid Lesions and Salivary Gland Lesions: An Overview. *J Cytol* 2018;35:173–5.
- Paschou SA, Vryonidou A, Goulis DG. Thyroid nodules: A guide to assessment, treatment and follow-up. *Maturitas* 2017;96:1–9.
- De Pauw FF, Francque SM, Bogers JP, et al. Fine needle trucut biopsy in focal liver lesions: a reliable and safe method in identifying the malignant nature of liver lesions. *Acta Gastroenterol Belg* 2007;70:1–5.
- Barbhuiya M, Bhunia S, Kakkar M, Shrivastava B, Tiwari PK, Gupta S. Fine needle aspiration cytology of lesions of liver and gallbladder: An analysis of 400 consecutive aspirations. *J Cytol* 2014;31:20–4.
- Sattar A, Khan AM, Anjum S, Naqvi A. Role of ultrasound guided fine needle aspiration cytology in diagnosis of space occupying lesions of liver. *J Ayub Med Coll Abbottabad* 2014;26:334–6.
- Cevik FC, Aykin N, Naz H. Complications and efficiency of liver biopsies using the Tru-Cut biopsy Gun. *J Infect Dev Ctries* 2010;4:91–5.
- Pujani M, Jetley S, Jairajpuri ZS, et al. A Critical Appraisal of the Spectrum of Image Guided Fine Needle Aspiration Cytology: A Three Year Experience from a Tertiary Care Centre in Delhi. *Turk Patoloji Derg* 2016;32:27–34.
- Huang C, Lorentzen T, Skjoldbye B, Rosenberg J, Nølsøe CP. Fast-track, ambulatory ultrasound-guided Tru-Cut liver biopsy is feasible and cost-efficient. *Dan Med J* 2015;62:A511.
- Brissot P, Troadec MB, Loréal O, Brissot E. Pathophysiology and classification of iron overload diseases; update 2018. *Transfus Clin Biol* 2019;26:80–8.
- Poynard T, Lebre C. The inconvenience of investigations used in hepatology: patients' and hepatologists' opinions. *Liver* 1982;2:369–75.
- Perrillo RP. The role of liver biopsy in hepatitis C. *Hepatology* 1997;26(3 Suppl 1):57–61.
- Chen QW, Cheng CS, Chen H, et al. Effectiveness and complications of ultrasound guided fine needle aspiration for primary liver cancer in a Chinese population with serum α -fetoprotein levels ≤ 200 ng/ml—a study based on 4,312 patients. *PLoS One* 2014;9:e101536.
- Li GP, Gong GQ, Wang XL, Chen Y, Cheng JM, Li CY. Fine needle aspirating and cutting is superior to Tru-cut core needle in liver biopsy. *Hepatobiliary Pancreat Dis Int* 2013;12:508–11.
- Ding W, He XJ. Fine needle aspiration cytology in the diagnosis of liver lesions. *Hepatobiliary Pancreat Dis Int* 2004;3:90–2.
- Kaçar Özkara S, Özöver Tuneli I. Fine needle aspiration cytopathology of liver masses: 101 cases with cyto-/histopathological analysis. *Acta Cytol* 2013;57:332–6.
- Reddy CV, Goud YG, Poornima R, Deshmane V, Madhusudhana BA, Gayathridevi M. Role of FNAC in Hepatic lesions: Risk of track metastases. *South Asian J Cancer* 2015;4:35–7.