



Ultrasound guided posterior femoral cutaneous nerve block

Ultrason kılavuzluğunda posterior femoral kutanöz sinir bloğu

İsmet TOPÇU,¹ İnan AYSEL²



Summary

The posterior femoral cutaneous nerve (PFCN) is a branch of the sacral plexus. It needs to be implemented as a complementary block for anesthesia or in the surgeries necessitating tourniquet in the suitable cases. We consider target oriented block concept within the PFCN block in the anesthesia implementations with the emergence of ultrasonic regional anesthesia in the practice and with the better understanding of sonoanatomy.

Key words: Posterior femoral cutaneous nerve; ultrasound.

Özet

Posterior femoral kutanöz sinir (PFCN) sakral pleksusun bir dalıdır. Uygun olgularda anestezi amacıyla veya turnike gerektiren cerrahilerde tamamlayıcı bir blok olarak yapılması gerekebilmektedir. Ultrasonun rejyonal anestezi pratiğine girmesiyle ve sonoanatominin daha iyi anlaşılmasıyla birlikte, anestezi uygulamalarımızda hedefe yönelik blok konseptini PFCN bloğu içinde düşünmeliyiz.

Anahtar sözcükler: Posterior femoral kutanöz sinir; ultrason.

Introduction

The posterior femoral cutaneous nerve (PFCN) is a branch of the sacral plexus. This is a posterior cutaneous nerve of the thigh and it arises from the posterior divisions of the ventral rami of S1 and S2 and the anterior divisions of S2 and S3.^[1] PFCN innervates to the skin of the perineum and the back surface of the thigh and leg (Figure 1). PFCN exits the pelvic region via the greater sciatic foramen. It passes right below the gluteus maximus muscle and from the upper proximal of bicep femoris muscle and ends by giving skin branches. Principally effective cutaneous is a nerve. It has no motor innervations and it is actually a strong sensory nerve.^[2]

With the sacral plexus block or posterior sciatic nerve blocks can be provided with PFCN block. It

is important that PFCN is blocked with the aim of preventing tourniquet pain in the knee, leg and foot operations which necessitates the tourniquet wearing to the femur.^[3] Isolated PFCN block indication is considerably limited. However, it is necessary to know and implement isolated block in the suitable cases to prevent over local anaesthesia consumption. With the ultrasound put into practice in the routine regional anaesthesia, nerve blocks are implemented by seeing nerves, not blindly.^[4] It is also possible to anaesthetize only the area where the operation takes place. The patients undergoing an operation are no longer subjected to unnecessary nerve blocks or central block implementations.

In this case presentation of the anaesthesia implementation with isolated ultrasound guided PFCN

¹Department of Anesthesiology and Intensive Care, Celal Bayar University Faculty of Medicine, Manisa, Turkey;

²Department of Anesthesiology and Intensive Care, Hand Microsurgery, Orthopedics and Traumatology Hospital, Izmir, Turkey

¹Celal Bayar Üniversitesi Tıp Fakültesi, Anesteziyoloji ve Yoğun Bakım Anabilim Dalı, Manisa;

²El Mikrocerrahi Ortopedi ve Travmatoloji Hastanesi, Anesteziyoloji ve Yoğun Bakım Kliniği, Izmir

Submitted (Başvuru tarihi) 23.08.2012 Accepted after revision (Düzeltilme sonrası kabul tarihi) 19.09.2012

Correspondence (İletişim): Dr. İsmet Topçu, Güzelyurt Mahallesi, Tarzan Bulvarı, No: 88, Öncü Sitesi, 45030 Manisa, Turkey.

Tel: +90 - 236 - 236 03 30 / 1006 e-mail (e-posta): topcuismet@yahoo.com

block in the skin flap in the rudimentary part of a traumatic patient who was implemented an amputation from the upper knee in the previous operation.

Case Report

The case was a 27-year-old, 79 kg and 175 cm male. Due to the traffic accident, which he had approximately 45 days ago, he was implemented upper knee subtotal amputation and exploration and irrigation for gluteus because of fracture of femur lateral condyle, tibia, fibula and metatarsus and gluteal injury (full level decomposition in gluteus maximus muscle) (Figure 2). In the postoperative period, debridement, adductor suture and skin graft operation are planned due to the dermal problem developed in the femur distal and posterior (Figure 3). The ASA physical status of patient is class I. His hemodynamic is stabile.

The case was taken to the operation after the implementation of premedication with diazepam. A vascular access was opened with 18 G IV cannula, infusion was started with 1 ml/kg Isolyte S solution. Standard hemodynamic monitorization was implemented after ECG, non-invasive artery blood pressure measure, peripheral O₂ saturation measure. The case was taken to the operation after the implementation of premedication with diazepam. A vascular access was opened with 18 G IV cannula, infusion was started with 1 ml/kg Isolyte S solution. Standard hemodynamic monitorization was imple-

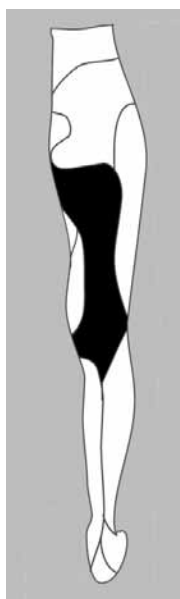


Figure 1. Cutaneous innervation area of the posterior cutaneous nerve of thigh.

mented after EKG, non-invasive artery blood pressure measure, peripheral O₂ saturation measure. The case was taken to the prone position and real-time block was practised with 100 mm insulated stimulation needle (Stimuplex Kanule A, B Braun) by seeing PFCN and by using 6-13 Mhz frequency linear probe with in - plane approach with ultrasound (SonoSite S-Nerve, Bothell, WA) from the subgluteal region. 10 mL 0,5% bupivacaine was implemented (Figure 4, 5). Twenty minutes after block, pain-free surgery started. An additional analgesic during the surgical operation was not required. The case didn't have any complication after the operation and post operative analgesic period was decided as 3 hours, the patient was discharged uneventfully in the post-operative seventh day.

Discussion

PFCN is distributed to the skin of the perineum and

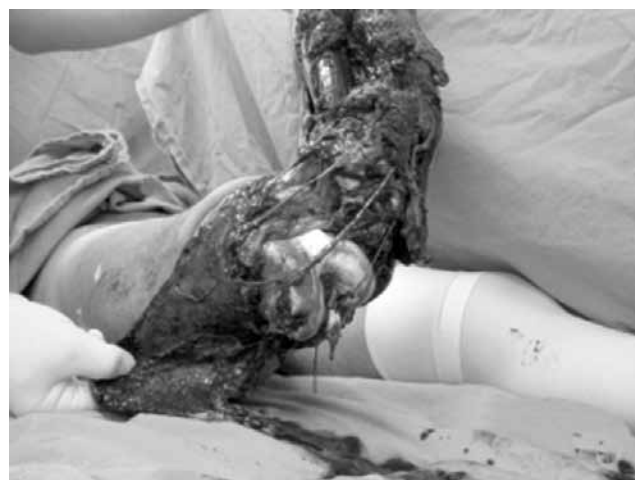

Figure 2. Subtotal amputation of the distal thigh due to trauma before the operation.

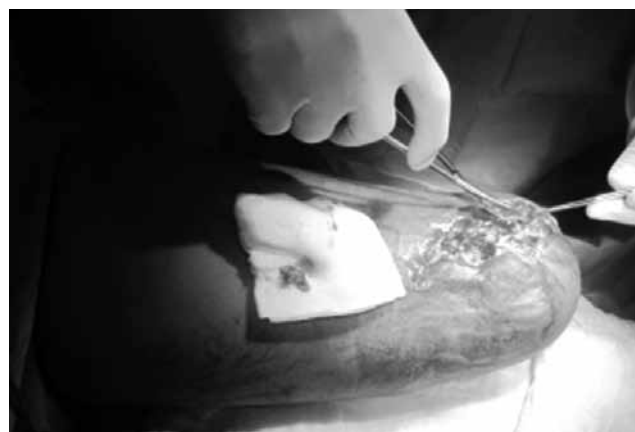

Figure 3. Posterior view of the thigh with a skin defect before the second operation.

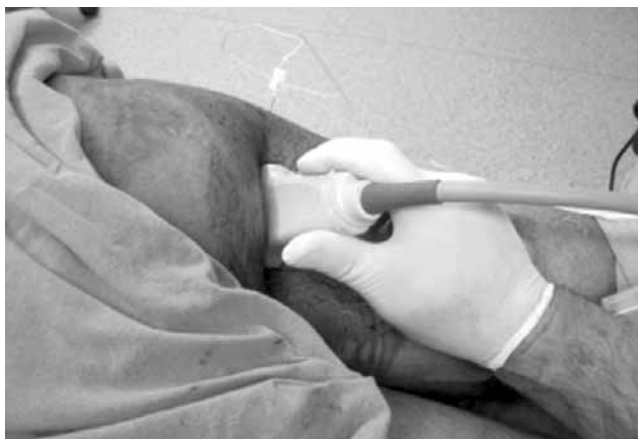

Figure 4. There is a scar tissue at the gluteal region (arrow). The patient is prone position and the probe is placed parallel to subgluteal crease. In-plane approach for posterior cutaneous nerve blockade.

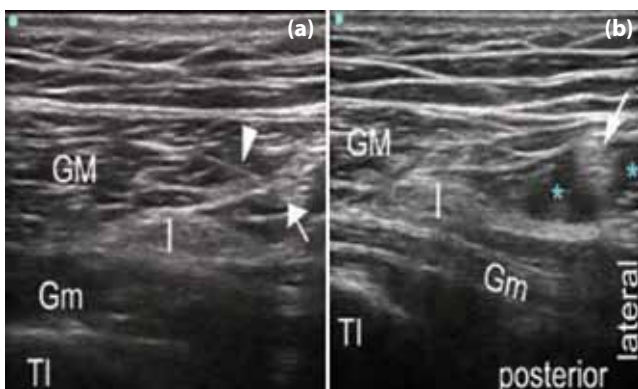

Figure 5. Gluteus maximus (GM) medius (Gm) muscle, ischiadic (I) and posterior cutaneous (arrow) nerve, ischial tuberosity (TI), needle (arrow head), local anesthetic (*). **(a)** Posterior cutaneous nerve is shown at the lateral side of the ischiadic nerve and under the lateral board of the gluteus maximus muscle. The needle is placed near the medial side of the posterior cutaneous nerve. **(b)** The local anesthetic is deposited mostly around the posterior cutaneous nerve but only a small part of the local anesthetic is in contact with the ischiadic nerve.

the back surface of the thigh and leg. It is principally a sensory nerve.^[1,2] It can be defined as a cutaneous nerve. It accompanies the inferior gluteal artery to the gluteus maximus and runs down the outer thigh and deep into the tissue at the back of the knee.^[5] PFCN is not a branch of sciatic nerve; it is a separate branch of sacral plexus. However, PFCN arises from greater sciatic foramen with sciatic nerve and goes to subgluteal field together with it. Thus, while a sciatic nerve block is implemented with posterior approaches (such as Labat approach), PFCN block can also be obtained.

In the case, the region to be implemented the surgical operation is within the sensory distribution re-

gion of PFCN. Due to the injury of the case in the gluteal region, a sacral plexus block implementation with the posterior approach was not possible. If the patient was implemented sciatic nerve block with posterior approach, there would be the possibility of PFCN not to be blocked. We have implemented isolated PFCN block with the target oriented real time implementation with ultrasound, by seeing the needle and local anaesthetic. Approximately 10 mL local anaesthetics provided sufficient and successful analgesia for the operation. This amount is very low if it is for sciatic nerve block implementation. Thus, we decreased the use of local anaesthetics by using PFCN block. At this level, in which we implemented PFCN block, the sciatic nerve is usually seen as 3 sided in the ultrasound. Although we implemented isolated PFCN, due to its close neighbourhood with sciatic nerve, we observed that some local anaesthetic came to a side of sciatic nerve.

Hughes and Brown who were the first to define the PFCN block in the literature, defined PFCN branches as emerging from below the medial border of gluteus maximus.^[6] They defined the needle access point as at a point one quarter of the distance from the ischial tuberosity to the greater trochanter in the gluteal fold. However, we practised the block by seeing PFCN in the ultrasound guide without using nerve stimulator or using these anatomic landmarks. As the nerve in the PFCN block usually goes from sacral roots to the gluteal area together with inferior gluteal nerve (60%), Barbero et al. reports that when the PFCN is stimulated, a motor response related to the inferior gluteal nerve may be expected.^[7] This view is a right approach for our routine practice as we use nerve stimulator. Especially when a posterior sciatic nerve block is implemented with nerve stimulator, if there a contradiction happens in the gluteus maximus, when the stimulation of nervus gluteus inferior innervating this muscle and the neighbourhood of PFCN are considered, we have some amount of local anesthetic implementation. However, in the posterior sciatic block implementation, gluteus maximus muscle contradiction is not a desired or searched state.

The sciatic nerve block implementation with anterior approach is a method used in the knee and foot surgery implementations. The most important rea-

son why this method is not popular is that due to the anatomic landmarks, PFCN cannot be blocked.

^[3] This situation creates a problem especially in the anaesthesia of surgeries requiring thigh tourniquet implementation. Isolated PFCN block should be known well and should be kept in the mind as a complementary block when there is an unsuccessful or insufficient PFCN block.

As the ultrasound is put into the regional anaesthesia practice and the sonoanatomy is better understood, the blocks have started to be “damage specific” and “target oriented”. It is recommended that the PFCN block explained in this article is considered from this aspect.

Conflict-of-interest issues regarding the authorship or article: None declared.

Peer-review: Externally peer-reviewed.

References

1. McMinn RMH, Hutchings RT. Color atlas of human anatomy: right gluteal region-branches of the sacral plexus. Weert, The Netherlands: Smeets-Weert, 1977:293.
2. Netter FH. Atlas of human anatomy. 3rd ed. Teterboro, NJ: 2002.
3. Barbero C, Fuzier R, Samii K. Anterior approach to the sciatic nerve block: adaptation to the patient's height. *Anesth Analg* 2004;98(6):1785-8. [CrossRef](#)
4. Griffin J, Nicholls B. Ultrasound in regional anaesthesia. *Anaesthesia* 2010;65 Suppl 1:1-12. [CrossRef](#)
5. Windhofer C, Brenner E, Moriggl B, Papp C. Relationship between the descending branch of the inferior gluteal artery and the posterior femoral cutaneous nerve applicable to flap surgery. *Surg Radiol Anat* 2002;24(5):253-7. [CrossRef](#)
6. Hughes PJ, Brown TC. An approach to posterior femoral cutaneous nerve block. *Anaesth Intensive Care* 1986;14(4):350-1.
7. Chelly JE, Delaunay L. Block of the posterior femoral cutaneous nerve. *Anesth Analg* 2005;100(2):597. [CrossRef](#)