

## Celiac Ganglion Block

Serdar Erdine\*

### ÖZET

#### Çölyak gangliyon bloğu

Perkütan çölyak pleksus bloğu yaklaşık bir asırdır uygulanan bir yöntemdir. Çölyak pleksus ve splanknik sinir blokları, başlangıçta cerrahi anestezi elde etmek amacıyla uygulanmıştır. Ancak, bu blokların uygulamadaki teknik zorlukları ve cerrahi anestezi elde etmedeki değişken sonuçları nedeniyle zamanla bu uygulamaların yerini spinal anestezi ve somatik paravertebral sinirlerin segmental blokları almıştır. Çölyak pleksus ve splanknik sinir bloklarının cerrahi anestezide kullanımının daralmasını, bu yöntemlerin yeni bir uzmanlık alanı olan ağrı tedavisinde artan kullanımları takip etmiştir. Bu bloklar, pankreas, karaciğer, safra kesesi, omentum, mezenter ve mideden transvers kolona kadar olan sindirim kanalından kaynaklanan, özellikle malign kökenli kronik ağrılarda etkili olmaktadır. Bu yazıda, çölyak blok ile ilgili anatomi, endikasyon ve kotrendikasyonlar, değişik uygulama teknikleri ve bunların sonuçları irdelenmektedir.

**Anahtar kelimeler:** Çölyak, splanknik, blok, teknik, abdominal ağrı

### SUMMARY

The percutaneous blockade of the celiac plexus is being performed nearly for a century. The aim of performing celiac plexus and splanchnic nerve blocks was surgical anesthesia at the beginning. But because of the technical demands and variable results of celiac plexus and splanchnic nerve blocks as a surgical anesthetic, over time, these techniques were supplanted by spinal anesthesia and segmental blockade of the somatic paravertebral nerves. As celiac plexus and splanchnic nerve blocks were falling into disuse for surgical anesthesia, the clinical utility of these techniques was becoming apparent in the new specialty of pain management. Celiac plexus and splanchnic nerve blocks are effective in relieving chronic abdominal pain, especially originating from the malignancies of the pancreas, liver, gallbladder, omentum, mesentery, and alimentary tract from the stomach to the transverse portion of the large colon. The relevant anatomy, indications, contraindications, different application techniques and results of celiac blockade is reviewed in this paper.

**Key words:** Celiac, splanchnic, block, technique, abdominal pain

(\*) İstanbul University İstanbul Faculty of Medicine, Department of Algology, Prof., M. D.

#### Correspondence to:

Serdar Erdine, Prof., M. D., İstanbul University İstanbul Faculty of Medicine, Department of Algology, 34390 Çapa, İstanbul, TURKEY  
Tel: (+90 212) 531 31 47 Fax: (+90 212) 631 05 41 e-mail: algotur@superonline.com

(\*) İstanbul Üniversitesi İstanbul Tıp Fakültesi, Algoloji Bilim Dalı, Prof. Dr.

#### Başvuru adresi:

Prof. Dr. Serdar Erdine, İstanbul Üniversitesi İstanbul Tıp Fakültesi, Algoloji Bilim Dalı, 34390 Çapa, İstanbul  
Tel: (0212) 531 31 47 Faks: (0212) 631 05 41 e-posta: algotur@superonline.com

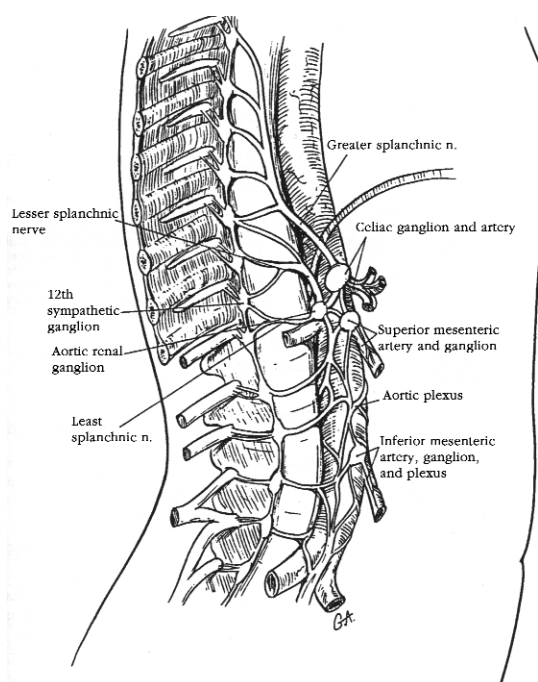
## History

In 1914, Kappis introduced the percutaneous technique for block of the splanchnic nerves and celiac plexus with local anesthetic (Kappis 1914). He described a posterior approach intended to be used primarily for a surgical anesthesia that utilized two needles, the tips of which were placed into the retroperitoneum via a retrocrural approach. He rapidly gained experience with this technique and reported on it in a series of 200 patients (Kappis 1918).

The same year, Wendling (1918) described a method of blocking the celiac plexus and splanchnic nerves utilizing a single needle placed anteriorly through the liver. Judged to be riskier than Kappis' posterior approach, it rapidly fell into disfavor.

Labat, Farr, and others introduced modifications of Kappis' technique over the ensuing 30 years (Roussiel 1923, Braun 1921, Labat 1920). Because of the technical demands and variable results of celiac plexus and splanchnic nerve blocks as a surgical anesthetic, over time, these techniques were supplanted by spinal anesthesia and segmental blockade of the somatic paravertebral nerves (De Takats 1927).

As celiac plexus and splanchnic nerve blocks were falling into disuse for surgical anesthesia, the clinical utility of these techniques was becoming



**Figure 1:** Splanchnic nerves; greater, lesser and least. Formation of the respective abdominal plexuses is shown.

apparent in the new specialty of pain management. Recognizing the difficulty in distinguishing the somatic and visceral components of abdominal pain, Popper (1948) recommended the use of splanchnic nerve block with local anesthetic as a diagnostic tool.

Alcohol neurolysis of the splanchnic nerves and celiac plexus for long-lasting relief of abdominal pain was first described by Jones (1957). Bridenbaugh and colleagues (1964) reported on the role of neurolytic celiac plexus block to treat the pain of upper abdominal malignancy.

In spite of these modifications, Kappis' classic posterior approach to the celiac plexus and splanchnic nerves continues to serve as the basis for contemporary techniques. Interestingly, there is renewed interest in the anterior approach to celiac plexus block, utilizing computed tomography or ultrasound to allow more accurate needle placement (Matamala et al. 1992, Matamala et al. 1988).

## Anatomy

Innervation of the abdominal viscera originates in the anterolateral horn of the spinal cord with the ventral spinal routes to join the white communicating rami en route to the sympathetic chain. In contradiction to other preganglionic sympathetic nerves, these axons do not synapse in the sympathetic chain; rather, they pass through the chain to synapse at distal sites, including the celiac, aortic renal and superior mesenteric ganglia. Postganglionic nerves accompany blood vessels to their respective visceral structures (Figure 1).

Preganglionic nerves from T<sub>5</sub> to T<sub>9</sub> and occasionally T<sub>4</sub> and T<sub>10</sub> travel caudally from the sympathetic chain along the lateral and anterolateral aspects of the vertebral bodies. At the level of T<sub>9</sub> and T<sub>10</sub>, the axons coalesce to form the greater splanchnic nerve, course through the diaphragm, and end as numerous terminal endings in the celiac plexus. Most travel ipsilaterally, but a few cross and synapse with contralateral postganglionic cell bodies.

Sympathetic nerves from T<sub>10</sub>-T<sub>11</sub> and occasionally T<sub>12</sub>, combine to form the lesser splanchnic nerve. Their course parallels the greater splanchnic nerve in a posterolateral position and ends in either the celiac plexus or aorticorenal ganglion. The least splanchnic nerves arise from T<sub>12</sub>, parallel posteriorly the lesser splanchnic nerve, and synapse in the aorticorenal ganglion.

Nociceptive input from abdominal viscera is carried by afferent nerves that are part of the spinal nerves but accompany the sympathetic nerves. Cell bodies exist in the posterior roots of the spinal nerves, with proximal axons synapsing in the dorsal horn of the spinal cord.

The celiac plexus lies anterior to the aorta and epigastrium. It is also located just anterior to the crus of the diaphragm and becomes an important consideration in selection of the approach for blockade. The plexus extends for several centimeters in front of the aorta and laterally around the aorta. Fibers within the plexus arise from preganglionic splanchnic nerves, parasympathetic preganglionic nerves from the vagus, some sensory nerves from the phrenic and vagus nerves, and sympathetic postganglionic fibers. Afferent fibers concerned with nociception pass diffusely through the celiac plexus and represent the main target of celiac plexus blockade.

These fibers coalesce to form a dense, intertwining network of autonomic nerves. Three pairs of ganglia exist within the plexus: (1) the celiac ganglia, (2) the superior mesenteric ganglia, and (3) the aorticorenal ganglia. Postganglionic nerves from these ganglia innervate all of the abdominal viscera with the exception of part of the transverse colon, the left colon, the rectum, and the pelvic viscera. Pelvic viscera ultimately have nociceptive synapse from T<sub>10</sub>-L<sub>1</sub> spinal levels and include the uterus and cervix (Raj 1985).

## Indications

Any pain originating from visceral structures and innervated by the celiac plexus can be effectively alleviated by block of the plexus. These structures include the pancreas, liver, gallbladder, omentum, mesentery, and alimentary tract from the stomach to the transverse portion of the large colon.

An additional benefit in these patients may be the effect of celiac plexus block on gastric motility. Complete sympathetic denervation of the gastrointestinal tract allows unopposed parasympathetic activity and increases peristalsis. Whereas diarrhea has been reported in a few patients, a concomitant decrease in the incidence of nausea and vomiting has also been reported. The presence of severe nausea and vomiting may be as a primary indication in patients with pancreatic cancer.

## Contraindications

Owing to the proximity to vascular structures, celiac plexus block is contraindicated in patients who are on anticoagulant therapy or suffer from congenital abnormalities of coagulopathy, antineoplastic cancer therapies, or liver abnormalities associated with ethanol abuse (Patt 1993, Waldman 1990). Local or intraabdominal infection and sepsis represent absolute contraindications to celiac plexus block.

As blockade of the celiac plexus results in greater bowel motility, the technique should be avoided in patients with bowel obstruction. Neurolytic celiac plexus block should probably be deferred in patients who suffer from chronic abdominal pain who are chemically dependent or who exhibit drug-seeking behavior, until these relative contraindications have been adequately addressed (Waldman 1992). The use of alcohol as a neurolytic agent should be avoided in patients on disulfiram therapy for alcohol abuse.

## Equipment

- 25 G skin infiltration needle
- 22 G 1.5-inch needle for deep infiltration
- 16 G 2-inch angiocath
- Curved blunt needle, 10 or 15 cm (10 or 15 mm tip)

## Drugs

Local anesthetic block

- 0.5% ropivacaine / 0.5% bupivacaine equal parts = 40 ml
- 2% lidocaine
- Steroids (water soluble)  
Dexamethasone  
Depot methylprednisolone or triamcinolone diacetate or equivalent

## Neurolysis

- 6-10% phenol in iohexol (Omnipaque)
- Absolute alcohol  
97% alcohol  
50% alcohol in saline
- Radiofrequency thermocoagulation (RFTC) machine

## Preoperative evaluation

1. Prothrombin time, activated partial thromboplastin time, bleeding time or platelet function study, blood count with platelets

2. CXR (chest X-ray)
3. Magnetic resonance imaging (MRI, for cancer; in area of block and detection of aneurysms)

### **Preoperative medication**

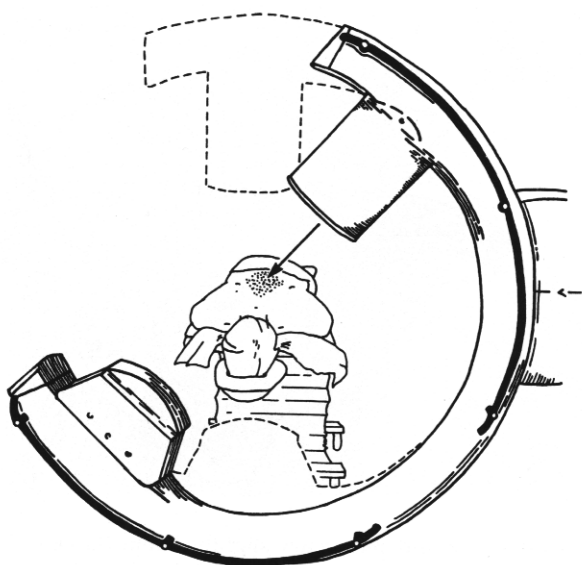
Standard ASA conscious sedation.

### **Technique**

#### **Posterior approach – blind technique**

The patient is placed in the prone position with a pillow beneath the abdomen to reverse the thoracolumbar lordosis (Figure 2). This position increases the distance between the costal margins and the iliac crests and between the transverse processes of adjacent vertebral bodies. For comfort, the patient's head is turned to the side, and the arms are permitted to hang off freely at either side of the table. The operative field is prepared and draped in standard aseptic manner.

Some clinicians find it beneficial to delineate the pertinent landmarks on the skin with a sterile marker. The landmarks include the iliac crests, 12<sup>th</sup> ribs, dorsal midline, vertebral bodies (T<sub>12</sub>-T<sub>2</sub>), and lateral borders of the paraspinal (sacrospinalis) muscles. Moore (1965) recommends that the intersection of the 12<sup>th</sup> rib and the lateral border of the paraspinal muscles on each side (which corresponds to L<sub>2</sub>) should be marked and connected with lines to each other and to the cephalic portion of the L<sub>1</sub> spine, forming an isosceles triangle, the sides of which serve as an additional guide to needle positioning (Figure 3).



**Figure 2:** Patient is placed is prone position with C-arm in oblique position at T<sub>12</sub>.

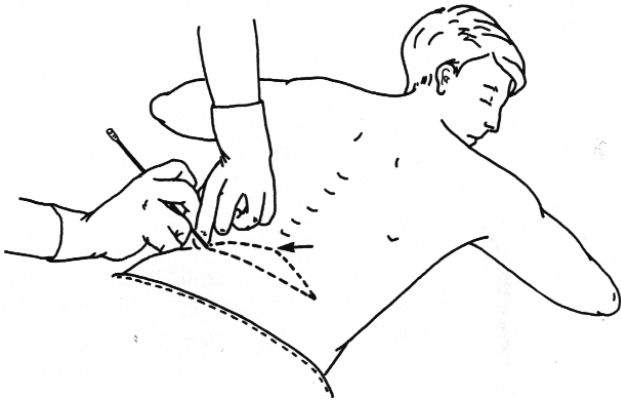The skin and underlying subcutaneous tissues and musculature are infiltrated with 1.0% lidocaine at the points of needle entry, which is about four fingerbreadth (7.5 cm) lateral to the midline, just beneath the 12<sup>th</sup> ribs. Either 20 or 22 G, 13 cm styletted needles are inserted bilaterally through the previously anesthetized areas. The needles are initially oriented 45 degrees toward the midline and about 15 degrees cephalad, to ensure contact with the L<sub>1</sub> vertebral body. Once contact with the vertebral body has been verified, the depth at which bone contact occurred is noted (some clinicians find it useful to actually mark this measurement on the shaft of the needle with a sterile gentian violet marker after the needle is withdrawn).

After bony contact is made and the depth is noted, the needles are withdrawn to the level of the subcutaneous tissue and redirected slightly lateral (about 60 degrees from the midline) so as to “walk off” the lateral surface of the L<sub>1</sub> vertebral body. The needles are reinserted to the depth at which contact with the vertebral body was first noted. At this point, if no contact with bone is made, the left-sided needle is gradually advanced 1.5 to 2 cm or until the pulsations emanating from the aorta transmitted to the advancing needle are felt (Thomson et al. 1987, Moore et al. 1981). The right-sided needle is then advanced slightly farther (i.e., 3-4 cm past contact distance with the vertebral body) (Figure 4). Ultimately, the tips of the needles should be just posterior to the aorta on the left and to the anterolateral aspect of the aorta on the right. It is essential that anteroposterior (AP) and lateral images are taken to confirm the correct position.

The stylets are removed, once the needles are in good position and the needle hubs are inspected for blood, cerebrospinal fluid, thoracic fluid and urine. A small volume of contrast material is injected bilaterally and its spread is observed radiographically.

Ideally, on the fluoroscopic AP view, contrast material is confined to the midline and concentrated near the L<sub>1</sub> vertebral body. A smooth posterior contour can be observed on the lateral view, in front of the vertebral body.

Alternatively, if computed tomography (CT) guidance is used, contrast material should appear lateral to and behind the aorta. If contrast material is confined entirely to the retrocrural space, the needles should be advanced to the retrocrural space to minimize the risk of posterior spread of local



**Figure 3:** Surface landmarks for celiac plexus block. The diagram drawn resembles a flat isosceles triangle.

anesthetic or neurolytic agent to the somatic nerve roots (see later) (Jain 1989).

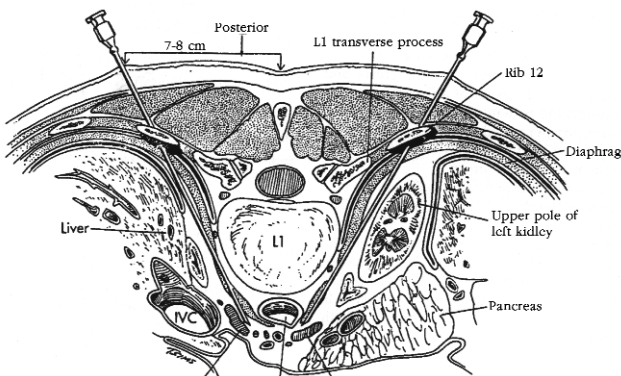
### ***Intradiscal approach***

The patient is placed in prone position with a pillow beneath the iliac crest to facilitate the opening of the interdiscal space as much as possible. T<sub>12</sub>-L<sub>1</sub> level is identified under fluoroscopy. The fluoroscope is turned oblique at an angle of 15-20 degrees. It is important to align the inferior end plates with a cephalocaudal projection (Figure 5).

### ***Paraspinous posterior approach***

This approach is similar to the approach for splanchnic nerve block. The difference is the needle which is diverted at the L1 vertebra and anterior to the vertebral body.

For diagnostic and prognostic block by utilizing the retrocrural technique, 12 to 15 ml of 1.0% lidocaine or 3.0% 2-chloroprocaine is administered through each needle (Waldman 1992). For



**Figure 4:** Cross-section of celiac plexus block. The proximity of renal parenchymal tissue necessitates placing needles no farther than 7 to 8 cm from midline.

therapeutic local anesthetic toxicity, all local anesthetics should be administered in incremental doses (Waldman 1991). For treatment of the pain of acute pancreatitis, an 80 mg dose of depot methylprednisolone is advocated for the initial celiac plexus block and 40 mg for subsequent blocks.

Most investigators suggest that 10 to 12 ml of 50% ethyl alcohol or 6.0% aqueous phenol be injected through each needle for retrocrural neurolytic block. Thomson and colleagues (1987), however, strongly recommend that 25 ml of 50% ethyl alcohol be injected via each needle.

After the neurolytic solution has been injected, each needle should be flushed with sterile saline solution (there have been anecdotal reports of neurolytic solution being tracked posteriorly along with the needles, as they are withdrawn). Radiographic guidance, in particular CT guidance, offers the pain specialist an added margin of safety when performing neurolytic celiac plexus block and thus should be utilized.

### ***Catheter placement***

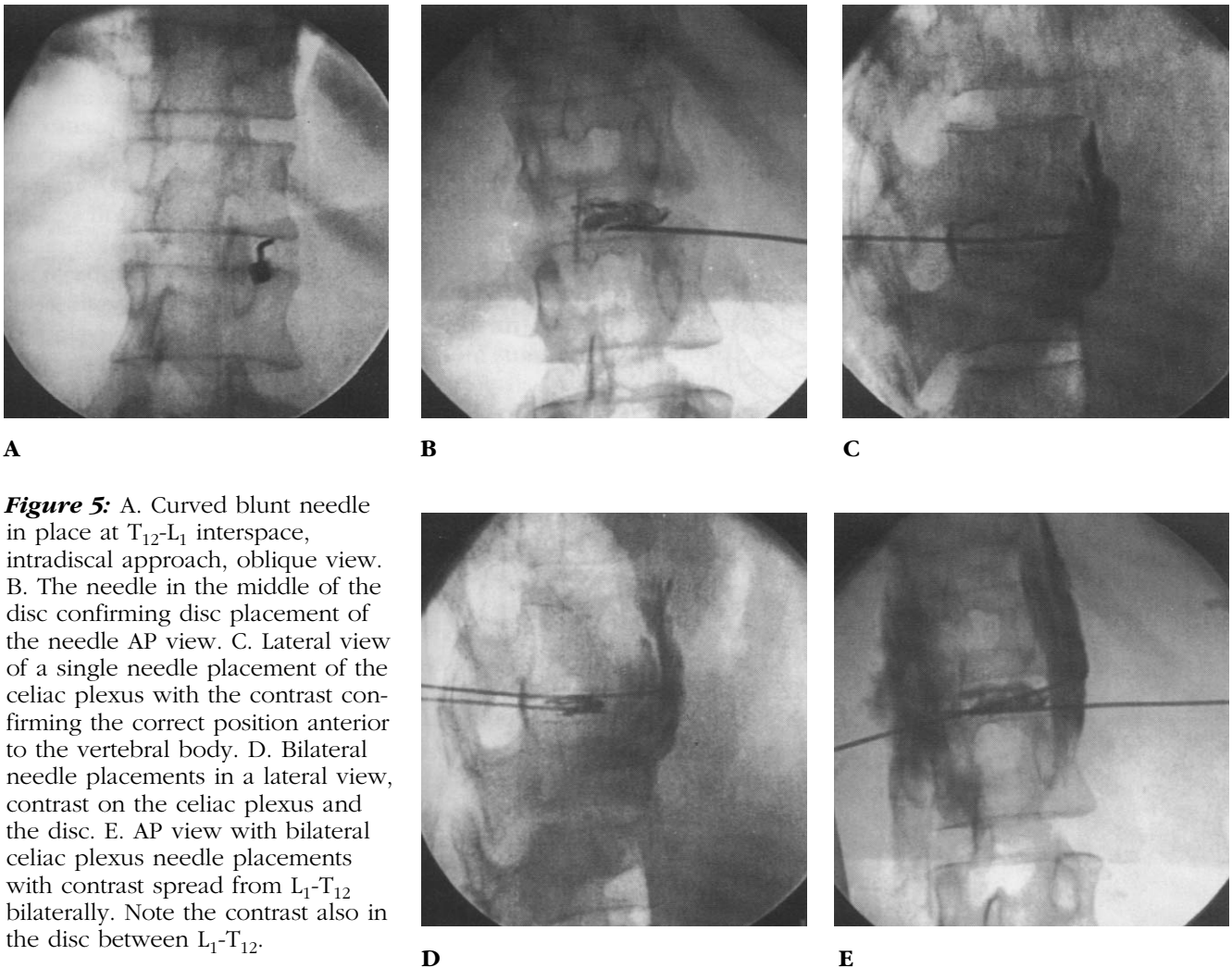
Patients with nonmalignant abdominal pain often fare poorly after neurolytic blockade of the celiac plexus, yet many derive temporary benefit from local anesthetic blockade. Because this pain is sympathetically mediated and reflexively perpetuated, continuous denervation of the plexus by local anesthetic infusion may provide prolonged analgesia.

The technique for placement is similar to that described previously. Instead of 22-gauge needles, use a 6 or 8-inch catheter system (e.g.: Longdwel, Becton & Dickinson) placed bilaterally. Once they are placed, secure the catheters at the skin with either a 2-0 silk skin suture or benzoin and Steri-Strips. Place a sterile, clear dressing over the catheters, which are connected to local anesthetic solutions of bupivacaine 0.1%, given at 6 to 8 ml/hr. These catheters can be maintained for 4 to 7 days if placed sterilely and if the sites are checked daily.

### ***Anterior approaches to celiac plexus block***

#### ***Advantages:***

A percutaneous anterior approach to the celiac plexus was advocated early in this century, only to be abandoned because of the high incidence of complications (Labat 1928, Wendling 1918). The



**Figure 5:** A. Curved blunt needle in place at T<sub>12</sub>-L<sub>1</sub> interspace, intradiscal approach, oblique view. B. The needle in the middle of the disc confirming disc placement of the needle AP view. C. Lateral view of a single needle placement of the celiac plexus with the contrast confirming the correct position anterior to the vertebral body. D. Bilateral needle placements in a lateral view, contrast on the celiac plexus and the disc. E. AP view with bilateral celiac plexus needle placements with contrast spread from L<sub>1</sub>-T<sub>12</sub> bilaterally. Note the contrast also in the disc between L<sub>1</sub>-T<sub>12</sub>.

advent of fine needles, improvements in radiological guidance technology, and the maturation of the specialty of interventional radiology have since led to renewed interest in the anterior approach to the celiac plexus.

Extensive experience with transabdominal fine-needle aspiration biopsy has confirmed the relative safety of this approach and provides the rationale and method for the modification of this radiologic technique for anterior celiac plexus block. The anterior approach to the celiac plexus necessarily involves the passage of a fine needle through the liver, stomach, intestine, vessels, and pancreas. Surprisingly, it is associated with very low rates of complications (Eisenberg et al. 1995, Lieberman et al. 1988, Mueller et al. 1987, Patt and Cousins 1988).

Advantages of the anterior approach to blocking the celiac plexus include its relative ease, speed and reduced peri-procedural discomfort as compared with posterior techniques (Patt 1993, Matamala et al. 1992). Perhaps the greatest advantage

of the anterior approach is the fact that patients are spared having to remain prone for long, which can be a significant problem for patients suffering from intraabdominal pain. The supine position is also advantageous for patients with ileostomies and colostomies.

The anterior approach is probably associated with less discomfort because only one needle is used. Furthermore, the needle does not impinge on either periosteum or nerve roots or pass through the bulky paraspinous musculature. Because needle placement is pre-crural, there is less risk of accidental neurologic injury related to retrocrural spread of drug to somatic nerve roots or epidural and subarachnoid spaces.

Potential disadvantages of the anterior approach to celiac plexus block include the risks of infection, abscess, hemorrhage, and fistula formation (Mueller 1987). Although preliminary findings indicate that these complications are exceedingly rare, further experience is needed to draw a definitive conclusion.

The anterior technique can be carried out under CT or ultrasound guidance. Patient preparation is similar to that for posterior approaches to celiac block. The patient is placed in the supine position on the CT or ultrasound table. The skin of the upper abdomen is prepared with antiseptic solution. The needle entry site is identified 1.5 cm below and 1.5 cm to the left of the xiphoid process (Lieberman 1988). At that point, the skin, subcutaneous tissues and musculature are anesthetized with 1.0 % lidocaine. A 22 G, 15 cm needle is introduced through the anesthetized area perpendicular to the skin and advanced to the depth of the anterior wall of the aorta, as calculated using CT or ultrasound guidance.

If CT guidance is being utilized, 4 ml of water-soluble contrast in solution with an equal volume of 1.0 % lidocaine is injected to confirm needle placement. If ultrasound guidance is being used, 10 to 12 ml of sterile saline can be injected to help confirm needle position (Matamala et al. 1992). After satisfactory needle placement is confirmed, diagnostic and prognostic block is carried out using 15 ml of 1.5 % lidocaine or 3.0 % 2-chloroprocaine. Owing to the potential for local anesthetic toxicity, all local anesthetics should be administered in incremental doses.

Matamala and associates (1992) recommended 35 to 40 ml of 50 % ethyl alcohol for neurolytic blocks of the celiac plexus via the anterior approach. Other investigators have had equally good results utilizing 15 to 20 ml of absolute alcohol.

An alternative technique uses fluoroscopy to guide the passage of a single needle just to the right of the center of the L<sub>1</sub> vertebral body, after which it is withdrawn 1 to 3 cm (Labat 1928). Important precautions for the anterior approach to celiac plexus block include the administration of prophylactic antibiotics and the use of needles no larger than 22 gauge to minimize the risks of infection and trauma to the vasculature and viscera.

### Complications

In the hands of the skilled clinician, serious complications should rarely occur from celiac plexus and splanchnic nerve blocks. Because of the proximity of other vital structures, however, coupled with the use of large volumes of neurolytic drugs, the following side effects and complications may be seen:

- Hypotension
- Paresthesia of lumbar somatic nerve
- Intravascular injection (venous or arterial)
- Deficit of lumbar somatic nerve
- Subarachnoid or epidural injection
- Diarrhea
- Renal injury
- Paraplegia
- Pneumothorax
- Chylothorax
- Vascular thrombosis or embolism
- Vascular trauma
- Perforation of cysts of tumors
- Injection of the psoas muscle
- Intradiscal injection
- Abscess
- Peritonitis
- Retroperitoneal hematoma
- Urinary tract abnormalities
- Failure of ejaculation
- Pain during and after the procedure
- Failure to relieve pain

The main side effect from celiac plexus block is backache, which usually results from the passage of needles through the back muscles. This can be minimized by gently positioning the needles, minimal repositioning and adequate local infiltration. Although self-limiting, back pain can be a significant complaint and can require use of a nonsteroidal anti-inflammatory drug, muscle relaxant or heating pad. Celiac catheter placement and subsequent maintenance can be distressing enough to require the ongoing treatments.

### Efficacy of Celiac and Splanchnic Nerve Blocks

Despite general agreement that celiac plexus block is indeed efficacious, significant controversy persists regarding (1) its efficacy relative to the opioid therapy, (2) the relative efficacy among different approaches and techniques, and (3) whether even a remote risk of paraplegia warrants a commitment to neurolysis, especially when treatment with analgesics usually provides adequate relief. Regrettably, despite the legacy of a richly descriptive literature, these questions

remain largely unresolved because of persisting scientific inadequacies.

A survey of the literature reviewed data from 23 studies on celiac neurolysis performed on 1126 patients, 64% of whom had pancreatic cancer pain and 36% of whom had pain caused by other intra-abdominal malignancies (Eisenberg 1995). Good to excellent pain relief was achieved in 90% of available patients during the first 2 weeks after treatment, only 6% of whom required a repeated procedure for inadequate analgesia. Partial or complete pain relief was observed in 95% of patients alive at the time of last follow-up and 87% of patients at the time of death. In another review that addressed the treatment of pain due to intra-abdominal malignancy independent of the site of primary tumor, significant relief of pain and persistence of effect until death were reported in 62% to 100% and 35% to 100%, respectively, with most studies reporting favorable outcomes in the higher ranges (Patt and Cousins 1998).

Another carefully conducted survey of the available literature draws similar conclusions (Mercandante and Micosia 1998). In this paper, Mercandante and Micosia conclude that favorable results are achieved in 85% and 73% of patients with pain caused by pancreatic and other malignancies, respectively, independent of the technique used. Such results include a low incidence of serious side effects, dose reduction in most patients, and a half-life for pain relief in excess of 4 weeks, with the likelihood of pain relief receding with increased survival time. In a recent small, prospective randomized controlled trial comparing celiac plexus neurolysis in 12 patients with medical management alone in 12 patients, all of whom suffered from pain caused by pancreatic cancer, neurolysis was associated with significant benefit, although this benefit was ultimately not as dramatic as the older literature would predict (Polati et al. 1998). Patients treated with neural blockade had much greater initial pain relief and similar long-term results for pain but used reduced drug doses and differed significantly from untreated patients on the basis of drug-related adverse effects. Complications were limited to transient hypotension and diarrhea in treated patients, whereas control patients experienced more constipation (12 of 12 versus 5 of 12), nausea and vomiting (4 of 12 versus 1 of 12, and other events, including a gastric ulcer and a gluteal abscess.

A carefully conducted randomized, prospective evaluation of quality of life in pancreatic cancer patients treated with celiac neurolysis versus pharmacotherapy reported on 10 and 11 patients, respectively (Kawamata et al. 1996). Patients given neural blockade had less pain for the first 4 weeks after treatment and used less morphine through week 7, after which lower doses persisted but not at a statistically significant level. Whereas performance status improved only transiently after celiac block, the most striking observation was that of a profound deterioration of performance status noted in pharmacologically treated patients that appeared to have been prevented in patients treated with neural blockade.

Using a similar design in 20 pancreatic cancer pain patients, Mercadante (1993) also achieved similar pain scores in patients randomized to pharmacotherapy alone and celiac block with pharmacotherapy but only as a consequence of a significantly greater opioid burden and attendant side effects. Factors influencing efficacy are uncertain but may include plexus invasion by tumor, which in one study, was found in 70% of patients with pancreatic cancer and was independent of tumor size and histopathology (Ihse 1990).

Time to maximal pain relief is variable. In most patients, relief is immediate and complete; in others it will accrue over a few days (Staats and Kost-Byerly 1995, Jain et al. 1989). In addition, pain relief is often reestablished with repetition. If the interval of comfort is extremely short, repetition by an alternate route may be warranted.

## References

- Braun H.: Ein Hilfsinstrument zur Ausführung der splanchnicusanesthetie. *Zentralbl Chir* 1921; 48: 1544.
- Bridenbaugh L. D., Moore D. C., Campbell D. D.: Management of upper abdominal cancer pain: Treatment with celiac plexus block with alcohol. *JAMA* 1964; 190: 877.
- De Takats G.: Splanchnic anesthesia: A critical review of the theory and practice of this method. *Surg Gynecol Obstet* 1927; 44: 501.
- Eisenberg E., Carr D. B., Chalmers T. C.: Neurolytic celiac plexus block for treatment of cancer pain: A meta-analysis. *Anesth Analg* 1995; 80: 290-295.
- Ihse I.: Pancreatic pain. *Br J Surg* 1990; 77: 121-122.
- Jain S., Hirsh R., Shah N.: Blood ethanol levels following celiac plexus block with 50% ethanol. *Anesth Analg* 1989; 68: S135.
- Jain S.: The role of celiac plexus block in intractable upper abdominal pain. In Racz G. B., editor. *Techniques of Neurolysis*. Boston: Kluwer Academic, 1989, pp. 161.



- Jones R. R.: A technique of injection of the splanchnic nerves with alcohol. *Anesth Analg* 1957; 36: 75.
- Kappis M.: Die Anesthesierung des Nervus splanchnicus. *Zentralbl* 1918; 45: 709.
- Kappis M.: Erfahrungen mit Lokalansthesia bei Bauchoperationen. *Verh Dtsch Ges Circ* 1914; 43: 87.
- Kawamata M., Ishitani K., Ishikawa K.: Comparison between celiac plexus block and morphine treatment on quality of life in patients with pancreatic cancer pain. *Pain* 1996; 64: 597-602.
- Labat G.: L'anesthésie splanchnique dans les interventions chirurgicales et dans les affections douloureuses de la cavité abdominale. *Gaz d'Hop* 1920; 93: 662.
- Labat G.: Splanchnic analgesia. In: Labat G., editor. *Regional Anesthesia: Its Technique and Clinical Application*, 2nd edition. Philadelphia: WB Saunders, 1928, pp. 398.
- Lieberman R. P., Nance P. N., Cuka D. J.: Anterior approach to the celiac plexus during interventional biliary procedures. *Radiology* 1988; 167: 562.
- Matamala A. M., Lopez F. V., Martinez L. I.: Percutaneous approach to the celiac plexus using CT guidance. *Pain* 1988; 34: 285.
- Matamala A. M., Sanchez J. L., Lopez F. V.: Percutaneous anterior and posterior approach to the celiac plexus: A comparative study using four different techniques. *Pain Clinic* 1992; 5: 21-28.
- Mercadante S.: Celiac plexus block versus analgesics in pancreatic cancer pain. *Pain* 1993; 52: 187-192.
- Mercadante S., Micosia F.: Celiac plexus block: A reappraisal. *Reg Anesth Pain Med* 1988; 23: 37-48.
- Moore D. C., Bush W. H., Burnett L. L.: Celiac plexus block: A roentgenographic, anatomic study of technique and spread of solution in patients and corpses. *Anesth Analg* 1981; 60: 369.
- Moore D. C.: *Regional Block* 4th edition. Illinois: Springfield, 1965, pp. 137-143.
- Mueller P. R., van Sonnenberg E., Casola G.: Radiographically guided alcohol block of the celiac ganglion. *Semin Intervent Radiol* 1987; 4: 195.
- Patt R. B., Cousins M. J.: Techniques for neurolytic neural blockade. In: Cousins M. J., Bridenbaugh P. O., editors. *Neural Blockade*, 3rd edition. Philadelphia: JB Lippincott, 1998, pp. 1007-1061.
- Patt R. B.: Neurolytic blocks of the sympathetic axis. In: Patt R. B., editor. *Cancer Pain*. Philadelphia: JB Lippincott, 1993. pp. 393-411.
- Polati E., Finco G., Gottin L.: Prospective randomized double-blind trial of neurolytic celiac plexus block in patients with pancreatic cancer. *Br J Surg* 1988; 85: 199-201.
- Popper H. L.: Acute pancreatitis: An evaluation of the classification, symptomatology, diagnosis and therapy. *Am J Digest Dis* 1948; 15: 1.
- Raj P. P.: Chronic pain. In: Raj P. P., editor. *Handbook of Regional Anesthesia*. New York: Churchill Livingstone, 1985, pp. 113-115.
- Roussiel M.: Anesthésie des nerfs splanchniques et des plexus mesenteriques superieur et inferieurs enchirurgie abdominale. *Presse Med* 1923; 31: 4.
- Staats P. S., Kost-Byerly S.: Celiac plexus blockade in a 7-year-old child with neuroblastoma. *J Pain Symptom Manage* 1995; 10: 321-324.
- Thomson G. E., Moore D. C., Bridenbaugh P. O.: Abdominal pain and celiac plexus nerve block. *Anesth Analg* 1987; 56:1.
- Waldman S. D., Portenoy R. K.: Recent advances in the management of cancer pain. Part II. *Pain Manage* 1991; 4: 19.
- Waldman S. D.: Acute and postoperative pain management. In: Weiner R.S., editor. *Innovations in Pain Management*. Orlando: PMD Press, 1993, pp. 28-29.
- Waldman S. D.: Celiac plexus block. In: Weiner R. S., editor. *Innovations in Pain Management*. Orlando: PMD Press, 1990. pp. 10-15.
- Waldman S. D.: Management of acute pain. *Postgrad Med* 1992; 87: 15-17.
- Wendling H.: Ausschaltung der Nervi splanchnici durch Leitungsanesthésie bei Magenoperationen und anderen Eingriffen in der oberen Bauchhule. *Beitr Klin Chir* 1918; 110: 517.