



## CASE REPORT

## Frontal recess osteoma causing severe headache

### *Şiddetli baş ağrısına neden olan frontal reses osteomu*

Ceyhun AKSAKAL

#### Summary

Frontal sinus osteomas are benign and well-defined masses that may cause various symptoms when they press on the surrounding tissues. Paranasal sinus osteoma is seen as a well-defined mass showing high opacity in Computed tomography. In this case study, we presented here a 53-year-old frontal recess osteoma with severe headache filling the left frontal recess in the context of the literature.

Keywords: Computed tomography; headache; osteoma.

#### Özet

Frontal reses osteomları benign, iyi sınırlı, çevre dokulara baskı yaptığında farklı semptomlara neden olan kitlelerdir. Paranasal sinüs osteomları tomografide yüksek opasifiye, iyi sınırlı kitle olarak görülürler. Biz 53 yaşında sol frontal resesi dolduran osteomu olan ve şiddetli baş ağrısı olan hastayı literatür eşliğinde sunduk.

Anahtar sözcükler: Komputeze tomografi; baş ağrısı; osteom.

#### Introduction

Frontal sinus osteomas are often asymptomatic, but slowly growing, benign tumours that can cause different symptoms when they compress the surrounding tissue.<sup>[1]</sup> Disturbances in the frontal sinus drainage may cause symptoms of sinusitis, as well as unilateral localised or bilateral headache.<sup>[2]</sup> Paranasal sinus computed tomography (CT) is the most useful in the diagnosis. The type of surgery is determined according to the size of the mass and the relationship with the surrounding tissues. Surgery is open, or endoscopic, or a combination of the two methods is used. We present a case of a frontal recess osteoma causing severe headache in the context of the literature.

#### Case Report

A 53-year-old male patient presented with severe pain in the left side and complaints in the left eye at the outpatient clinic. The patient had previously

received 10 days of antibiotic treatment in other centres. A paranasal sinus CT scan showed a mass of 17×11 mm in diameter, occupying the lower third of the frontal sinus, filling the left frontal recess and disrupting the sinus drainage (Fig. 1). The septum deviations that prevented reaching the mass on the left side were intervened. A mass filling the frontal recess and extending the frontal sinus was mobilised and removed in one piece (Fig. 2, 3). The mass was in contact with the lamina papyracea and the anterior headbase. No defect was observed in the lamina papyracea. However, there was a defect of 1×1 cm in the anterior osseous area of the skull base. However, no cerebrospinal fluid fistula was detected. The patient was followed up for 4 days in the clinic. During this period, he was given antibiotic treatment of 1 g ceftriaxone three times a day. The patient was discharged on the 4<sup>th</sup> day. At the 5<sup>th</sup>-month follow-up, the patient's symptoms completely disappeared and no problems were observed.

The current affiliation of the author: Department of Otorhinolaryngology, Gaziosmanpaşa University Faculty of Medicine, Tokat, Turkey

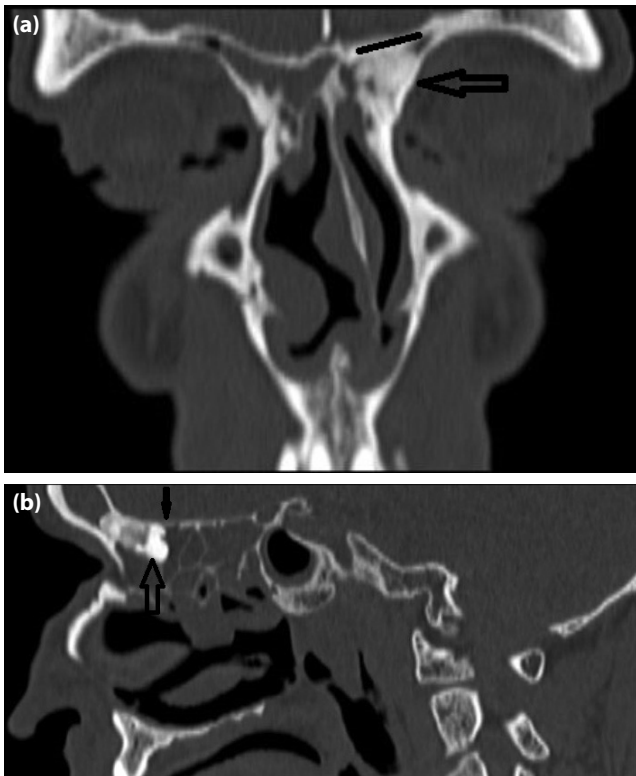
Department of Otorhinolaryngology, Tokat State Hospital, Tokat, Turkey

Submitted: 14.01.2018 Accepted after revision: 18.06.2018 Available online date: 01.10.2018

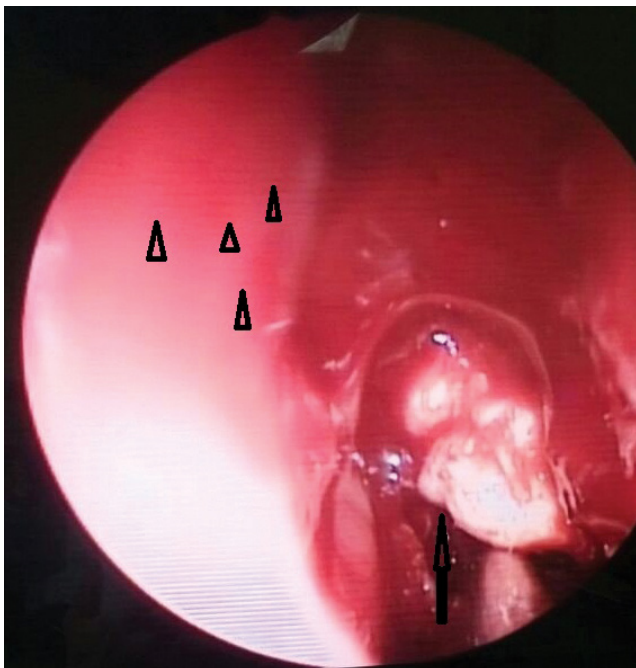
**Correspondence:** Dr. Ceyhun Aksakal. Tokat Devlet Hastanesi, Kulak Burun Boğaz Polikliniği, 60100 Tokat, Turkey.

**Phone:** +90 - 356 - 212 95 00 **e-mail:** aksakalceyhun@gmail.com

© 2020 Turkish Society of Allergy



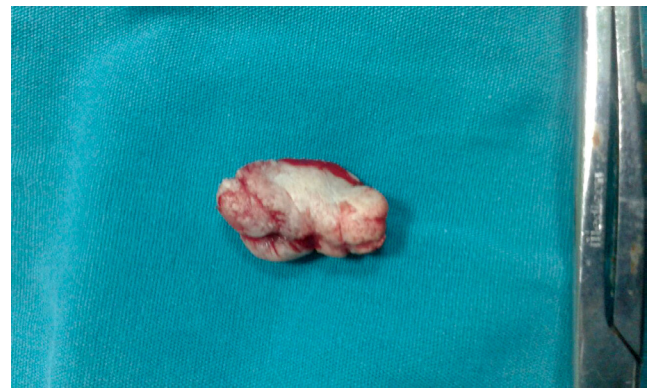**Figure 1.** (a) Coronal section of computerised tomography scan of the patient. Osteoma (black arrow), nasal septum (white arrowhead). (b) Sagittal section. Osteoma (black arrow), anterior skull base (oblique black line).



**Figure 2.** Intraoperative endoscopic view of the mass. Osteoma (black arrow), nasal septum (black arrowheads).

## Discussion

Osteomas are benign, slowly growing, well-limited tumours of the paranasal sinuses. They are primarily observed in the frontal sinuses, followed by the



**Figure 3.** Post-operative picture of the mass.

ethmoid sinuses.<sup>[3]</sup> There is a male predominance among the affected populations.<sup>[4]</sup> Our patient was a 53-year-old male patient. Osteomas are often incidentally detected to be asymptomatic. Paranasal sinus CT is the gold standard in the diagnosis. CT shows a radiopaque mass with well-defined borders, which can cause various symptoms depending on the size of the lesion and the mass. Headache is observed especially in case of frontal osteomas. However, frontal osteomas are incidentally detected simultaneously in non-symptomatic headaches. Radiological imaging is important in this context. In addition, frontal osteomas must be considered in the differential diagnosis of patients applying to the neurology clinic with headache.<sup>[5]</sup> Obliteration of the frontal recess can cause sinusitis symptoms and severe headache by disrupting the sinus drainage. In our case, the osteoma that obstructed the frontal recess was under pressure in the lamina papyracea. There was severe pain on the left side of the forehead and numbness in the left eye.

The treatment for symptomatic frontal sinus osteomas is surgery. The type of surgery is determined based on the size and location of the osteoma. According to Chiu et al's<sup>[6]</sup> classification, the frontal osteomas are differentiated based on the occupation of the frontal recess. Grade 1 and 2 tumours are treated using an open approach, whereas grade 3 and 4 tumours can be treated by the endoscopic method. Our case was grade 1, and an endoscopic approach was planned.

In our case, we osteotomised the osteomas by excising from the surrounding tissues. Sieńkiewicz A.<sup>[7]</sup> applied endoscopic approach to all the eight frontal osteoma series and obtained complete cure in all the patients.<sup>[8]</sup> In another series of 60 patients reported

by Turri-Zanoni et al.,<sup>[9]</sup> the authors had applied endoscopic approach to 31 patients, combined approach to 25 patients and open approach to 4 patients, with no long-term recurrences being observed during the periodic follow-ups.<sup>[10]</sup> It has been emphasised that the endoscopic approach has low post-operative morbidity in these series. In our case, we performed endoscopic excision of the frontal recess and filling osteoma that prevented the sinus drainage.

In conclusion, frontal recess osteomas can lead to different symptoms depending on the region where they are pressed, and high success rates can be obtained using an appropriate surgical treatment.

**Informed Consent: Written informed consent was obtained from the patient for the publication of the case report and the accompanying images.**

**Conflict-of-interest issues regarding the authorship or article: None declared.**

**Peer-review: Externally peer-reviewed.**

## References

1. Huang HM, Liu CM, Lin KN, Chen HT. Giant ethmoid osteoma with orbital extension, a nasoendoscopic approach using an intranasal drill. *Laryngoscope* 2001;111(3):430–2.
2. Buyuklu F, Akdogan MV, Ozer C, Cakmak O. Growth characteristics and clinical manifestations of the paranasal sinus osteomas. *Otolaryngol Head Neck Surg* 2011;145(2):319–23. [\[CrossRef\]](#)
3. Cheng KJ, Wang SQ, Lin L. Giant osteomas of the ethmoid and frontal sinuses: Clinical characteristics and review of the literature. *Oncol Lett* 2013;5(5):1724–30. [\[CrossRef\]](#)
4. Selva D, White VA, O'Connell JX, Rootman J. Primary bone tumors of the orbit. *Surv Ophthalmol* 2004;49(3):328–42.
5. Ata N, Tezer MS, Koç E, Övet G, Erdur Ö. Large Frontoorbital Osteoma Causing Ptosis. *J Craniofac Surg* 2017;28(1):e17–e18. [\[CrossRef\]](#)
6. Chiu AG, Schipor I, Cohen NA, Kennedy DW, Palmer JN. Surgical decisions in the management of frontal sinus osteomas. *Am J Rhinol* 2005;19(2):191–7. [\[CrossRef\]](#)
7. Sieńkiewicz A, Lyson T, Piszczatowski B, Rogowski M. Endoscopic treatment of adversely located osteomas of the frontal sinus. *Ann Otol Rhinol Laryngol* 2012;121(8):503–9.
8. Ledderose GJ, Betz CS, Stelter K, Leunig A. Surgical management of osteomas of the frontal recess and sinus: extending the limits of the endoscopic approach. *Eur Arch Otorhinolaryngol* 2011;268(4):525–32. [\[CrossRef\]](#)
9. Turri-Zanoni M, Dallan I, Terranova P, Battaglia P, Karligiotis A, Bignami M, et al. Frontoethmoidal and intraorbital osteomas: exploring the limits of the endoscopic approach. *Arch Otolaryngol Head Neck Surg* 2012;138(5):498–504.
10. Bolzoni Villaret A, Schreiber A, Esposito I, Nicolai P. Endoscopic ultrasonic curette-assisted removal of frontal osteomas. *Acta Otorhinolaryngol Ital* 2014;34(3):205–8.