



CASE REPORT

Stellat ganglion blockage in the treatment of chronic refractory angina pectoris

Kronik refrakter angina pektoris tedavisinde stellat ganglion blokajı

Ferdi GÜLAŞTI,^{1*} Sevil GÜLAŞTI,^{2**} Sinem SARI,³ Osman Nuri AYDIN⁴

Summary

In addition to medical approaches, laser revascularization, transmyocardial laser revascularization, angiogenesis, growth factor gene therapy, thoracic epidural anesthesia, and spinal cord stimulation are used to treat chronic refractory angina pectoris. A unilateral left stellate ganglion block is another alternative. It may particularly be considered as a palliative intervention in patients with a short life span. Described here is the case of a 66-year-old male patient for whom a unilateral left stellate ganglion blockade was used to treat chronic refractory angina pectoris.

Keywords: Chronic refractory angina pectoris; late heart failure; palliative treatment; unilateral left stellate ganglion blockade.

Özet

Kronik refrakter angina pektoris tedavisine medikal yaklaşım, lazer revaskülarizasyon, transmyokardiyal lazer revaskülarizasyon, angiogenesis, growth faktör gen terapisi, torakal epidural anestezi ve spinal kord simülatörü kullanılmakla birlikte, unilateral sol stellat ganglion blokajı bir alternatif olarak önerilmektedir. Özellikle yaşam süresi kısa olan hastalarda tercih edilebilecek bir palyatif bir girişim olarak düşünülmelidir. Bizde 66 yaşında erkek hasta son dönem kalp yetersizliği ile takip edilen ve kronik refrakter angina pektorisin tedavisinde unilateral sol stellat ganglion blokajı yapılan olguyu sunduk.

Anahtar sözcükler: Kronik refrakter angina pektoris; son dönem kalp yetmezliği; palyatif tedavi; unilateral sol stellat ganglion blokajı.

Introduction

In recent years, due to the improvements in the treatment of coronary artery disease and other areas of medicine, life expectancy is increasing and the number of patients with cardiac disease is increasing. In addition to medical treatment, unilateral left stellate ganglion blockade can be used to treat angina-related chest pain. Although the use of chronic refractory angina pectoris is not common in patients with no curative cardiac treatment chances, unilateral left stellate ganglion blockade is an attempt to achieve palliative success.

We present a patient with chronic refractory angina pectoris who has recently been diagnosed with

heart failure and who underwent unilateral left stellate ganglion blockade.

Case Report

A 66-year-old male patient admitted to the emergency room with chest pain and shortness of breath. The patient has been followed up with coronary artery disease, heart failure, and diabetes mellitus type 2 diagnoses, and the diagnosis of ST elevation myocardial infarction (NONSTEMI) was followed up with coronary intensive care unit. 2 coronary artery bypass grafting (CABG) were performed before and subsequently was percuta-

*The current affiliation of the author: Department of Anaesthesiology and Reanimation, Bursa City Hospital, Bursa, Turkey

**The current affiliation of the author: Department of Cardiology, Bursa City Hospital, Bursa, Turkey

¹Department of Anaesthesiology and Reanimation, Kütahya Gediz State Hospital, Kütahya, Turkey

²Department of Cardiology, Kütahya Gediz State Hospital, Kütahya, Turkey

³Department of Anaesthesiology, Adnan Menderes University Faculty of Medicine, Aydın, Turkey

⁴Department of Algologie, Adnan Menderes University Faculty of Medicine, Aydın, Turkey

Submitted: 16.03.2018 Accepted after revision: 11.09.2018 Available online date: 25.09.2018

Correspondence: Dr. Ferdi Gülaştı. Kütahya Gediz Devlet Hastanesi, Anesteziyoloji ve Reanimasyon Kliniği, Kütahya, Turkey.

Phone: +90 - 505 - 492 96 50 **e-mail:** ferdigulasti@gmail.com

© 2021 Turkish Society of Algology

neous intervention was applied to the circumflex artery (CX), followed by 2 (CX) and percutaneous interventions was applied to the left coronary artery (LMCA). On echocardiography; left ventricular ejection fraction (EF) was assessed as 25%. The laboratory values of the patient were pathologically determined as blood glucose 204 mg/dl, troponin 372 and haemoglobin 10.4 gr/dl.

The patient had to go to the hospital in the last year, 11 times with decompensated heart failure and persistent angina pectoris. In the recent coronary angiography of the patient; LMCA 90%; CX proximal 99%; 99% proximal left anterior descending artery (LAD); 99% in the right coronary artery 99% narrow artery and diffuse atherosclerosis in all coronaries were observed and the patient's saphenous grafts were found to be occluded (Fig. 1). The patient underwent a LMCA bifurcation and further attempts to be realized by cardiology team were considered risky. Medical treatment of the patient was as follows; ramipril 2.5 mg, metoprolol 50 mg, spiro lactone 25 mg, ticagrelor 90 mg, acetylsalicylic acid 100 mg, furosemide 40 mg, ranolozin 375 mg and trimatezadin 35 mg. The patient was evaluated in cardiology and algology clinic for pain control upon since reattemptive invasive intervention wasn't considered by the cardiology-cardiovascular council. Because the patient had terminal period heart failure, stellate ganglion blockade was decided.

The patient was treated with 1 mg intravenous midazolam + 50 mcg fentanyl, after 6, vertebra-level scopi coincidence with contrast material, ganglion blockade with left stellate ganglion 40 mg bupivacain + 8 mg dexamethasone (Fig. 2). The angina complaint of the patient, who had no complication after the procedure, disappeared. The patient died due to decompensated heart failure 3 days after the procedure.

Discussion

It is thought that there are special nociceptors in the heart. Heart-related pains are common and moderate. In contrast to pain severity, nausea, vomiting due to neuroendocrine stress response, blood pressure and heart rate changes can be accompanied by the actual visceral pain as well as the reflected pain spreading to the upper part of the neck, shoulder, chest and abdominal wall can be seen.

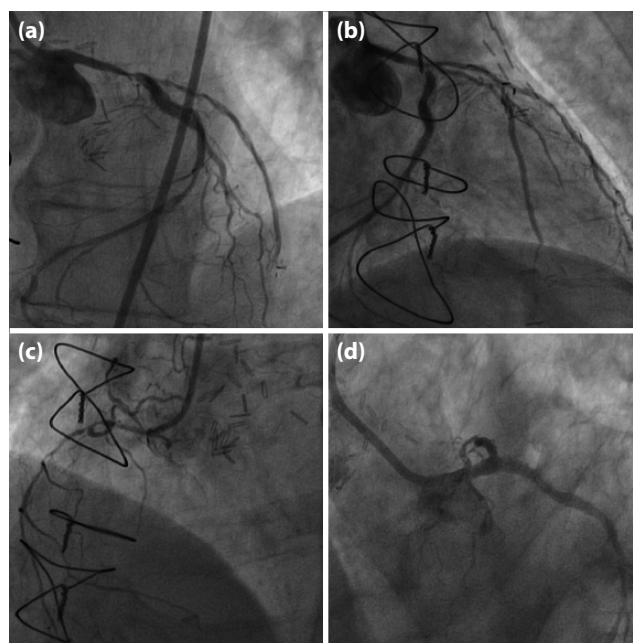


Figure 1. (a, b) LMCA 90%; CX proximal 99%; 99% stenosis at LAD proximal. (c) 99% stenosis in right coronary artery. (d) Post LMCA intervention.

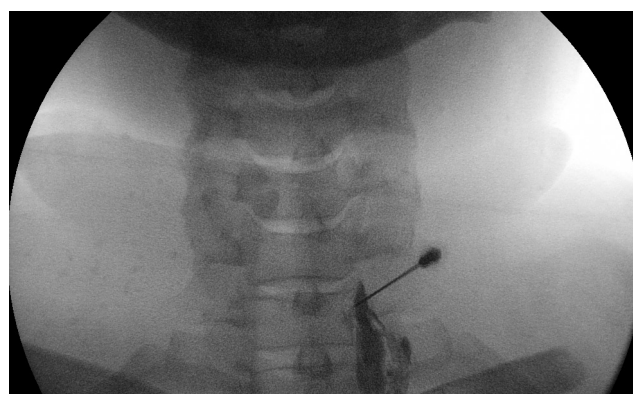


Figure 2. Unilateral left stellate ganglion blockade done for chronic refractory angina pectoris.

Angina pectoris refractory to medical therapy, angioplasty and coronary bypass surgery cannot be controlled with a combination of, angina due to the fact that coronary insufficiency is a chronic condition that is characterized by the presence of angina.^[1] The patient should be evaluated by the heart team, where the ischemic origin of the angina and the revascularization cannot be applied. The majority of patients with ischemic heart disease can be treated with medication and revascularization procedures. While the development of cardiovascular care increases the number of patients with end-stage coronary artery and refractory anger also increases. However, there is still no standard approach to refractory angina pectoris. In these patients, quality of life has deteriorated due to repetitive and continuous pain, poor general health status, psychological distress

and limited activity.^[2] In order to exclude the development of a new disease that can be treated with revascularization, patients are advised to have regular angiography. Our patient was frequently admitted to emergency room with recurrent chest pains and had a severe activity limitation.

In addition to medical treatment in patients with chronic refractory angina pectoris, additional treatment methods include laser revascularization, transmyocardial laser revascularization, angiogenesis, growth factor and gene therapy.^[3] In addition, the specialists of algology or anaesthesiology are involved in the treatment with thoracic epidural anaesthesia for palliative purposes, unilateral left stellate ganglion blockade and spinal cord simulator.^[3] It appears that the unilateral left stellar ganglion blockade is not a protocol for the use of cardiac pathologies. In addition to persistent angina patients with unilateral left stellar ganglion blockade, there are case reports in the literature used in the treatment of long QT syndrome and refractory ventricular tachycardia (VT storm).^[4,5] One-sided stellat ganglion blockage can only be done in the form of a block with local anaesthetic agent; local anaesthetic agent +6% phenol mixtures can be done applied. After diagnostic block, stellar ganglia radiofrequency thermo coagulation can also be applied.

Cervicotoracic (stellate) block is an attempt to diagnose and treat the symptoms of the head, neck, upper chest and upper extremities of complex regional pain syndromes (CRPS), sympathetic pain and symptoms.^[6] Although the technique used widely during stellate ganglionic blockade is anterior paratracheal technique, lateral and posterior approaches are also defined.^[6]

SGB can be applied with two finger methods from C6 (Chassignac's tubercle) and C7 levels.^[6] It provides blockages from all cervical ganglions and upper thoracic ganglions to T5 ganglions depending on the drug volume. At the end of the operation, pocsosis, myositis, enthalymia, nasal deconjesion and anhrozia in the neck and Horner's syndrome occurs at the same side.^[6,7] Because it is easier to palpate the SGB, as it is more distant from the pleura, and because the risk of vertebral artery puncture is lower, it is preferred to do it at C6 level.^[6] In this study, we aimed to investigate the relationship between the severity of

coronary artery disease and the risk of coronary artery disease in patients with coronary artery disease (CAD). In our case, the anterior paratracheal stellate ganglion blockade was performed with two fingers and the complication was not developed.

In a prospective study they performed, Saraste et al., found changes in myocardial perfusion reserve in patients who underwent SCS treatment for refractory angina pectoris.^[8] Patients over 80 years of age who were admitted as contraceptive for SCS treatment, those with ventricular injection fraction <40%, acute coronary syndrome, decompensated heart failure, VF, ventricular tachycardia continuing for 3 months, severe asthma, 2nd and 3rd degree AV block patients were not included in the study.^[9] In addition to being EF: 25% of our patient, recent heart failure is present, since life expectancy of less than 1 year assessed by the heart team we thought it would not be suitable for SCS treatment. However, because the aneurysm was severe, we thought that thoracic epidural anaesthesia or unilateral left stellate ganglion blockade could be applied. We considered that partial injection of thoracic epidural anaesthesia should be performed, the epidural catheter should be kept in place, but there is no catheter in the left unilateral ganglia block, and the number of invasive procedures would provide a smaller number of long-term blockages. In our patient, we provided unilateral left stellate ganglion blockade without complications.

Result

Cardiology, anaesthesiology and algology experts should keep in mind that unilateral left stellate ganglion blockade is a part of palliative care in patients with chronic refractory angina during the last stage of heart failure.

Informed Consent: Written informed consent was obtained from the patient for the publication of the case report and the accompanying images.

Conflict-of-interest issues regarding the authorship or article: None declared.

Peer-review: Externally peer-reviewed.

References

1. McGillion M, Arthur HM, Cook A, Carroll SL, Victor JC, L'allier PL, et al. Management of patients with refractory angina: Canadian Cardiovascular Society/Canadian Pain Society

- joint guidelines. *Can J Cardiol* 2012;28(2 Suppl):S20–41.
2. Brorsson B, Bernstein SJ, Brook RH, Werkö L. Quality of life of patients with chronic stable angina before and four years after coronary revascularisation compared with a normal population. *Heart* 2002;87(2):140–5. [\[CrossRef\]](#)
 3. Chumburidze VB, Kharchilava NA, Aladashvili AV. The problem of chronic refractory angina pectoris. *Georgian Med News* 2005;(118):26–8.
 4. Rajesh MC, Deepa KV, Ramdas EK. Stellate Ganglion Block as Rescue Therapy in Refractory Ventricular Tachycardia. *Anesth Essays Res* 2017;11(1):266–7. [\[CrossRef\]](#)
 5. Egawa H, Okuda Y, Kitajima T, Minami J. Assessment of QT interval and QT dispersion following stellate ganglion block using computerized measurements. *Reg Anesth Pain Med* 2001;26(6):539–44. [\[CrossRef\]](#)
 6. Sinem Sarı, Osman Nuri Aydın. Complication belong to Stellate ganglion blockade after cervical trauma. *Agri* 2014;26(2):97–100. [Article in Turkish] [\[CrossRef\]](#)
 7. Cousins MJ, Bridenbaugh PO. *Neural Blockade*. 3rd ed. New-York: Lippincott- Raven; 1998. p. 411–47.
 8. Schlack W, Schäfer S, Thämer V. Left stellate ganglion block impairs left ventricular function. *Anesth Analg* 1994;79(6):1082–8. [\[CrossRef\]](#)
 9. Saraste A, Ukkonen H, Varis A, Vasankari T, Tunturi S, Taittonen M, et al. Effect of spinal cord stimulation on myocardial perfusion reserve in patients with refractory angina pectoris. *Eur Heart J Cardiovasc Imaging* 2015;16(4):449–55. [\[CrossRef\]](#)