

## CASE REPORT

# Urothelial cell carcinoma of bladder in the second trimester of pregnancy: A clinical case presentation

Turgay Kacan<sup>1</sup>

<sup>1</sup>Department of Urology, Ankara Bilkent City Hospital, Ankara, Turkiye

### Abstract

Bladder cancer in pregnant women is a rare and challenging condition to manage due to its potential impact on both the mother and the fetus. Bladder cancer may be incidentally detected or manifest with macroscopic hematuria and irritative symptoms. However, the physiological processes occurring during pregnancy, influenced by hormonal changes, can complicate the diagnosis by masking these symptoms. Due to the limited number of cases reported in the literature, there is a lack of guideline recommendations for the follow-up and treatment of bladder tumors in pregnant individuals.

In this case report, we aim to present a patient with transitional cell urothelial cancer who presented with macroscopic hematuria in the second trimester, a detected mass in bladder on ultrasound, and underwent complete resection by bipolar transurethral resection.

### Article Info

Received Date: 14.03.2024

Revision Date: 14.03.2024

Accepted Date: 15.03.2024

### Keywords:

Pregnancy,  
Transurethral resection of  
bladder,  
Urinary bladder neoplasms

**Correspondence Address:** Üniversiteler Mahallesi 1604. Cadde No: 9 Çankaya Ankara - Türkiye  
**Phone:** +90 538 773 38 32 / **e-mail:** turgaykacan@gmail.com

Follow this and additional works at: <https://achmedicaljournal.com>

## Introduction

Over the course of pregnancy, cancer is a rare condition. Breast malignancy, cervical malignancy, Hodgkin's disease, malignant melanoma, and leukemias being the most commonly observed at the same time as this period.<sup>1</sup> Bladder cancer (BC), however, is extremely rare. Diagnosing it can be challenging during pregnancy due to the physiological changes, which may overlap with symptoms of hematuria, irritative voiding, or bladder outlet symptoms. Urinary ultrasonography, cystoscopy, and magnetic resonance imaging (MRI) are regarded as reliable diagnostic methods throughout pregnancy.<sup>2</sup> However, careful evaluation is required due to the displacement of the bladder caused by the enlargement of the uterus and physiological hydronephrosis.

Diagnosing and managing malignancy during pregnancy is challenging due to its impact on both the mother and the fetus. Specific treatment guidelines and intervention indications for BC during pregnancy have not been established, given its rarity and the limited number of case reports in the literature.

## Case

A 28-year-old pregnant patient at 22 weeks of gestation (Gravida 2, Parity 1, Abortion 0) presented to the urology clinic with painless, macroscopic hematuria with clots for the last month. She had no additional medical history, medication use, or smoking history. Abdominal examination revealed a uterus compatible with a 22-week gestation. Complete blood count revealed Hb: 10.9 g/dl, Htc: 34.3%. Urinalysis was consistent with macroscopic hematuria. Urine culture showed no growth. Urinary ultrasonography detected a lesion in the left lateral wall of the bladder, measuring 28x22x25 mm, showing papillary extension into the bladder, with irregular borders and vascularity. The upper urinary system was normal. At 23 weeks of gestation, cystoscopy was performed under spinal anesthesia, revealing a tumoral lesion consistent with the ultrasonography findings (Figure 1). The tumor was completely resected with bipolar transurethral resection (Figure 2). The histopathological diagnosis was non-invasive, low-grade urothelial carcinoma (pTa, LG). No intraoperative or postoperative complications were observed. Subsequent cystoscopies in the early postpartum period and at 3 months showed no recurrence. The patient was included in the routine BC follow-up program after delivery.

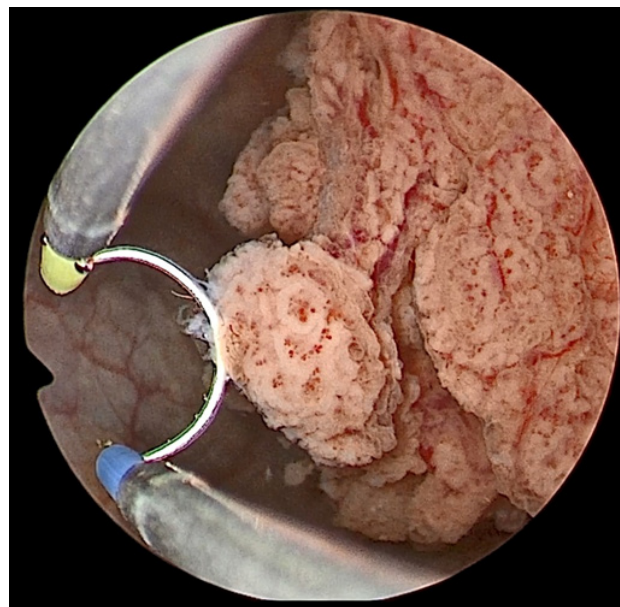


Figure 1: Bladder papillary urothelial carcinoma located on the left lateral wall. Bipolar resectoscope loop width 5 mm.

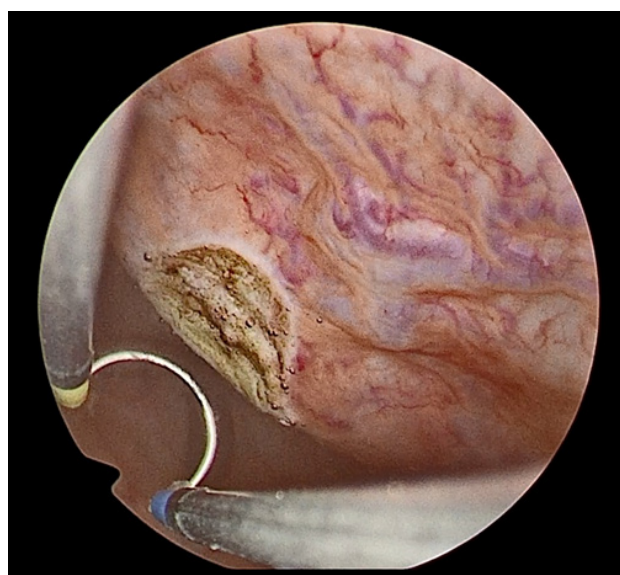


Figure 2: Completely resected urothelial carcinoma tumor base.

## Discussion

Bladder cancer is predominantly observed in the elderly, less frequently in young individuals, and extremely rarely in pregnant women. The first documented case of bladder tumor during pregnancy dates back to 1927, and approximately 50 cases have been reported in the literature to date.<sup>3</sup>

While BC during pregnancy may present symptoms such as irritative symptoms, microscopic or macroscopic hematuria, recurrent urinary tract infections, and bladder outlet obstruction, it can also be in-

identally detected during routine transvaginal ultrasonography.<sup>4-6</sup> In this case, BC became symptomatic with the classical symptom of macroscopic hematuria.

In cases where malignancy is suspected, ultrasonography is preferred as the safest imaging method for pregnant women. Even if the diagnosis is incidentally made during routine follow-up with transvaginal ultrasonography performed by obstetricians, it should be noted that it is limited to the pelvic area. Therefore, in symptomatic patients, a complete urinary system ultrasonography should be performed. In the differential diagnosis, leiomyomas, schistosomiasis, endometriosis, and particularly placenta percreta invading the bladder, which can cause life-threatening bleeding, should be considered.<sup>7-9</sup> When malignancy is detected on ultrasonography, the safest advanced imaging method that can be applied is MRI, and it is preferably performed after the first trimester. However, the use of gadolinium-enhanced MRI during pregnancy, especially in the first 24 weeks, should be avoided due to the uptake of gadolinium by the embryo, excretion through the urinary tract, and re-entry into the fetal circulation.<sup>10</sup>

During pregnancy, the treatment of BC is not different from non-pregnant patients. If ultrasonography or flexible cystoscopy suggests invasive or advanced disease, staging MRI should be performed, and treatment should be planned accordingly. As in most patients, if ultrasonography or flexible cystoscopy suggests noninvasive disease, transurethral resection of the bladder tumor should be performed. The timing of the intervention depends on various factors such as the stage and aggressiveness of cancer, the stage of pregnancy, and the condition of the mother and fetus. Treatment decisions should also be shaped according to the desires of the pregnant woman. Early intervention can pose a risk to the fetus's life, while delayed treatment can lead to the progression of the disease. Surgical intervention is generally avoided during the first three months when organogenesis occurs, while the second trimester is generally safe for intervention. If cancer is diagnosed in the late second trimester or third trimester, intervention may be better performed at 28 weeks of gestation when fetal lungs are mature. Although congestion due to pregnancy and possible distortion of the bladder may pose technical challenges, transurethral resection of the bladder tumor under spinal or general anesthesia is safe during pregnancy. Serious complications of this procedure have not been reported in pregnant patients.

Transurethral resection using monopolar or bipolar energies has limited experience regarding its effects on the fetus and outcomes of pregnancy, making the effects poorly defined. However, bipolar loop resection with saline irrigation appears to be a safe procedure.<sup>3</sup> In this case, complete resection was performed using bipolar energy, and no complications were encountered. The optimal management of bladder tumors during pregnancy has not been determined due to their rarity and limited reported experiences in the literature. Bipolar transurethral tumor resection in the second trimester is a safe surgical approach. This case illustrates the need for a careful evaluation of all treatment options during pregnancy, including early surgical intervention when appropriate.

## References

1. Pavlidis NA. Coexistence of Pregnancy and Malignancy. *Oncologist*. 2002;7(4):279-287. doi:10.1634/theoncologist.2002-0279
2. Khochikar M V. Management of urological cancers during pregnancy. *Nat Rev Urol*. 2010;7(4):195-205. doi:10.1038/nrurol.2010.25
3. Hoshina H, Taguchi S, Suyama H, et al. Surgical resection of retinoblastoma-associated bladder leiomyosarcoma during pregnancy: a case report. *BMC Urol*. 2023;23(1). doi:10.1186/s12894-023-01298-3
4. Muezzinoglu T, Inceboz U, Baytur Y, Nese N. Bladder carcinoma in pregnancy: Unusual cause for frequent urinary tract infection - Case report. *Arch Gynecol Obstet*. 2013;287(4):833-834. doi:10.1007/s00404-012-2552-7
5. Lakmichi MA, Zehraoui R, Dahami Z, et al. Bladder cancer in the second trimester of pregnancy: Tough decisions. A case report with review of the literature. *Ther Adv Urol*. 2012;4(3):139-142. doi:10.1177/1756287212441961
6. Yasemin A, Karsidag K, Giray B, Buyukbayrak EE. Bladder Cancer Diagnosed at Routine Obstetric Evaluation ESGO Conference View Project Purse-String Double-Layer Closure for Cesarean Incision (Turan Technique) View Project. <https://www.researchgate.net/publication/312033531>
7. Balan R, Radu VD, Giuşca SE, et al. A rare cause of massive hematuria: Placenta percreta with bladder invasion. *In Vivo (Brooklyn)*. 2021;35(6):3633-3639. doi:10.21873/invivo.12670
8. Töz E, Ince O, Apaydin N, Gürbüz T, Dayanikli N, Ayaz D. A case of bladder endometriosis that

became symptomatic during the third trimester. *Case Rep Womens Health.* 2015;6:1-3. doi:10.1016/j.crwh.2015.02.001

9. Zachoval R, Dukatova K, Svabik K. Vaginal ultrasound for imaging of a urinary bladder mass and treatment of a large leiomyoma of the urinary bladder in pregnancy. *Int Urogynecol J.* 2018;29(4):601-602. doi:10.1007/s00192-017-3505-2

10. Shellock FG, Kanal E. Safety of magnetic resonance imaging contrast agents. *Journal of Magnetic Resonance Imaging.* 1999;10(3):477-484. doi:10.1002/(SICI)1522-2586(199909)10:3<477::AID-JMRI33>3.0.CO;2-E