

## CASE REPORT

# Neuromyelitis Optica associated with Myasthenia Gravis: A Case Report

Selin Betas Akin,<sup>1</sup> Tutku Atay,<sup>1</sup> Abdullah Guzel,<sup>1</sup> Gokce Zeytin Demiral,<sup>1</sup> Ulku Turk Boru<sup>1</sup>

<sup>1</sup>Department of Neurology, School of Medicine, Afyonkarahisar Health Sciences University, Afyonkarahisar, Turkiye

### Abstract

Neuromyelitis optica (NMO, Devic syndrome) is an inflammatory, demyelinating central nervous system disorder typically associated with optic neuritis and transverse myelitis involving three or more segments in the spinal cord. Myasthenia Gravis (MG) is an autoimmune disease characterized by weakness in fatiguing muscles due to impaired neuromuscular transmission. NMO can coexist with autoimmune diseases, and its association with myasthenia gravis is common. Studies in existing patients with both NMO and MG support that MG symptoms often appear earlier and tend to be milder. Here, we present a case of a 45-year-old woman with concurrent NMO and MG, aligning with findings from previous studies.

### Article Info

Received Date: 04.01.2024  
Revision Date: 08.02.2024  
Accepted Date: 09.02.2024

### Keywords:

Demyelinating diseases,  
Neuromuscular diseases,  
Myasthenia Gravis,  
Devic disease

**Correspondence Address:** Afyonkarahisar Sağlık Bilimleri Üniversitesi Afyonkarahisar - Türkiye  
**Phone:** +90 543 972 00 52 / **e-mail:** selin\_\_betas@hotmail.com

Follow this and additional works at: <https://achmedicaljournal.com>

### Introduction

Neuromyelitis optica (NMO, Devic syndrome) is an inflammatory, demyelinating central nervous system disorder typically associated with optic neuritis and transverse myelitis involving three or more segments in the spinal cord. Despite being recurrent, it differs from Multiple Sclerosis in its more severe course, less involvement of the brain, and association with a longitudinally extensive lesion in the spinal cord. Additionally, NMO is linked to the serum autoantibody NMO-IgG, targeting aquaporin-4, and is recurrent in over 90% of patients.<sup>1</sup> Pathophysiology: Aquaporin-4 immunoglobulin-G (IgG) is thought to bind to aquaporin-4 on astrocytes, leading to complement-dependent cytotoxicity, which in turn results in leukocyte infiltration, cytokine release, and disruption of the blood-brain barrier.<sup>2</sup> These initial events contribute to oligodendrocyte death, myelin loss, neuronal death, and consequently, clinical neurological impairment. Especially in regions where aquaporin-4 expression is high, such as the optic nerve and spinal cord, these autoantibodies cause damage and inflammation, leading to blindness, paralysis, and chronic disability.<sup>3</sup> Myasthenia Gravis (MG), on the other hand, is an autoimmune disease characterized by weakness in fatiguing muscles due to impaired neuromuscular transmission.<sup>4</sup> NMO can coexist with autoimmune diseases, and the association with myasthenia gravis is common. Autoimmune myasthenia gravis is 100 times more common in patients with NMO compared to the general population (2% vs. 0.02%).<sup>5</sup> A case is presented where MG symptoms were milder than NMO symptoms in cases of coexistence of MG and NMO.

### Case

A 45-year-old female patient presented to the neurology clinic with a complaint of decreased vision in the left eye for the last two days. In her medical history, she reported experiencing weakness throughout the body and drooping of the right eyelid towards the evening while performing daily activities in 2011. Following investigations, she was diagnosed with MG based on a positive Anti-Ach receptor antibody result. The cranial MRI at that time was normal, and repetitive EMG revealed neuromuscular junction involvement consistent with the diagnosis, along with a positive Anti-Ach receptor antibody in blood tests. The patient was started on Pyridostigmine bromide 60 milligrams (mg) tablet, 360 mg/day,

and Azathioprine 25 mg tablet, 75 mg/day during that period. Upon further detailing the patient's history, it was found that in 2019, she had a sudden onset of complete vision loss in the right eye and balance disturbance. The family history of the patient was unremarkable. Neurological examination revealed ptosis in the right eye and increased deep tendon reflexes. A relative afferent pupillary defect was diminished on the right side. Examination of the fundus of the eye revealed a pale right optic disc and a slightly swollen left optic disc. The patient's visual acuity was measured at counting fingers from 30 centimeters in the left eye, while it was measured as 20/20 in the right eye. There was concentric narrowing in the arcuate region of the left eye's visual field. The patient was classified as Class 1 in the Myasthenia Gravis Foundation of America (MGFA) classification. For central pathologies, cranial, cervical, and orbital MRIs were performed. Orbital MRI, after intravenous contrast injection, revealed contrast enhancement in both the right and left optic nerves (Figure-1). Cranial and spinal imaging were unremarkable.

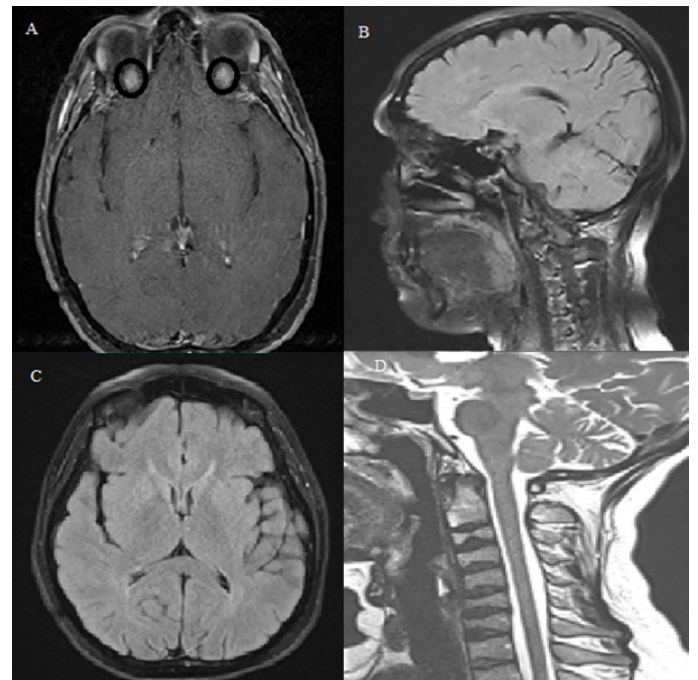


Figure-1: A: The patient's T2 sequence contrast-enhanced orbital MRI imaging shows bilateral contrast uptake in the optic nerve in the transverse section, suggesting the presence of optic neuritis with some degree of uncertainty indicated by the question mark.

B,C,D: The patient's T2 sequence contrast-enhanced brain MRI and cervical MRI images were obtained. No neuropathological findings were detected.

Considering the patient's history of bilateral vision loss at different times, a possible coexistence of demyelinating disease and MG was considered. Vasculitic, infectious, and paraneoplastic markers were found to be negative. Oligoclonal band and NMO-MOG antibodies were requested. The Aquaporin-4 receptor result was reported positive. Our patient met the diagnostic criteria for NMO with the positivity of one of the absolute criteria (optic neuritis) and the presence of aquaporin-4 antibody positivity in the serological examination. Additionally, contrast enhancement was observed in bilateral optic nerves on orbital MRI, serving as supporting evidence. In the current patient, the coexistence of NMO and MG was considered in the context of an acute NMO presentation, and the patient was treated with 1000 mg pulse steroids for 5 days. Oral corticosteroid treatment was continued as maintenance therapy. The patient's vision complaint partially improved. One month after treatment, the patient's visual acuity in the left eye improved to 20/30, while it remained normal in the right eye. During the follow-up period, there was no worsening of symptoms observed, and the symptoms of MG were under control.

## Discussion

Myasthenia Gravis (MG) and neuromyelitis optica (NMO) are autoimmune disorders mediated by humoral immunity targeting acetylcholine receptor (AChR) and aquaporin-4 (AQP4), respectively. MG affects the peripheral neuromuscular junction (NMJ) outside the central nervous system (CNS), while NMO primarily impacts the central nervous system. Due to autoimmune channelopathies in both the peripheral and central nervous systems, MG and NMO share many similarities: they develop based on the relationship between genetic factors and environmental influences, both are mediated by T cell-mediated, B cell-dependent immunopathology, and are influenced by the effects of antibodies and complement. It is now recognized that complement dysfunction is central to the pathogenesis. Human leukocyte antigen (HLA) genes are associated with these two autoimmune diseases in terms of genetic factors. Antigen-presenting cells (APCs) and lymphocytes demonstrate the importance of specific adaptive autoimmune responses in transferring signals from the activated innate immune system, contributing to the establishment of long-lasting autoimmune memory. Epigenetic mechanisms link environmental factors

and genetics in the disease, including microRNAs, DNA methylation, and others.<sup>6</sup> When environmental factors are evaluated, many such factors, including diet, vitamin D, and microbiota, contribute as predisposing factors to the onset and severity of autoimmune diseases, or they may exacerbate as triggering factors, such as infections, pollutants, and pharmacological molecules.<sup>7,8</sup> These diseases share some common features, including genetic predispositions, environmental factors, impaired tolerance, collaboration of T cells and B cells, and T helper cell (Th1/Th2/Th17) dysregulations, abnormal cytokine, antibody secretion, complement activation, among others. However, some aspects of the immune mechanisms differ. Both targets (AChR and AQP4) are expressed in the periphery and CNS, but MG mainly affects the NMJ outside the CNS, while NMO affects the central nervous system.<sup>9</sup> Relationships between NMO and other autoimmune diseases exist, with 30% of NMO patients having a concurrent autoimmune disease, and 40% having other autoantibodies without a distinct accompanying disease.<sup>1</sup> Common coexisting diseases with NMO include systemic lupus erythematosus, MG, and antiphospholipid syndrome.<sup>10</sup>

The coexistence of MG and NMO among these mentioned diseases is of particular interest to researchers because it is more frequent than expected in the general population.<sup>8</sup> In a study of 177 NMO patients, 2% had accompanying MG, and 11% had AChR antibodies.<sup>11</sup> In another study involving 164 MG patients, 10-15% had CNS involvement resembling NMO, and half of them had positive AQP4-IgG.<sup>12</sup> The course of MG in the context of this coexistence is generally benign, but central nervous system involvement, especially when accompanied by thymomas, can be potentially more severe.<sup>8,11</sup> In most cases, MG symptoms develop before the onset of NMO, and early-onset AChR-MG is often detected in these patients.<sup>8</sup>

Studies support that AQP4-IgG positive NMO is more associated with MG, and they argue that thymectomy may predispose to the development of NMO.<sup>13</sup> In this association, since MG symptoms typically start first, performing thymectomy in patients with existing thymic pathology may exacerbate NMO symptoms. This situation could pose challenges in treatment. Especially in MG patients presenting with atypical symptoms, the coexistence of NMO should be considered.

## Conclusion

Neuromyelitis optica and Myasthenia Gravis are two diseases that can coexist through autoimmune mechanisms. In these patients, MG symptoms typically start earlier and have a better prognosis.

In the presented case, the diagnosis of MG was made in 2011 before the diagnosis of NMO, and the clinical history of the patient shows a more favorable course for MG, consistent with findings in clinical studies. Following the diagnosis of the disease, Azathioprine treatment has been completely discontinued, and the use of Pyridostigmine HCl has been reduced from 360 mg/day to 120 mg/day, allowing the patient to maintain their daily life. However, it should not be forgotten that NMO can have an aggressive course, especially in cases of atypical MG symptoms. Therefore, this association should be kept in mind.

## References

1. Wingerchuk, D.M., Weinshenker, B.G. Neuromyelitis optica. *Curr Treat Options Neurol* 10, 55–66 (2008). <https://doi.org/10.1007/s11940-008-0007-z>
2. Ratelade, Julien, and AS22713791 Verkman. “Neuromyelitis optica: aquaporin-4 based pathogenesis mechanisms and new therapies.” *The international journal of biochemistry & cell biology* 44.9 (2012): 1519-1530.)
3. Graber, David J., et al. “Neuromyelitis optica pathogenesis and aquaporin 4.” *Journal of neuroinflammation* 5.1 (2008): 1-21
4. Oflazer, Piraye, Durmuş-Tekçe, Hacer, & Deymeer, Feza. (2020, July 23). KAS VE NÖROMÜSKÜLER KAVŞAK HASTALIKLARI. Istanbul Tıp Fakültesi Nöroloji Anabilim Dalı. <http://www.itfnoroloji.org/kas/kasindex3.htm>
5. Zekeridou, Anastasia, and Vanda A. Lennon. “Aquaporin-4 autoimmunity.” *Neurology-Neuroimmunology Neuroinflammation* 2.4 (2015)
6. Z, Yan Y. Immunopathogenesis in Myasthenia Gravis and Neuromyelitis Optica. *Front Immunol*. 2017 Dec 12;8:1785. doi: 10.3389/fimmu.2017.01785. PMID: 29312313; PMCID: PMC5732908
7. Berrih-Aknin, Sonia. “Myasthenia Gravis: paradox versus paradigm in autoimmunity.” *Journal of autoimmunity* 52 (2014): 1-28.
8. Leite MI, Coutinho E, Lana-Peixoto M, et al. Myasthenia gravis and neuromyelitis optica spectrum disorder: a multicenter study of 16 patients. *Neurology*. 2012;78(20):1601-1607. doi:10.1212/WNL.0b013e31825644ff
9. McKeon A, Lennon VA, Jacob A, Matiello M, Lucchinetti CF, Kale N, et al. Coexistence of myasthenia gravis and serological markers of neurological autoimmunity in neuromyelitis optica. *Muscle Nerve* (2009) 39:87–90. 10.1002/mus.21197
10. Wang Z, Yan Y. Immunopathogenesis in Myasthenia Gravis and Neuromyelitis Optica. *Front Immunol*. 2017 Dec 12;8:1785. doi: 10.3389/fimmu.2017.01785. PMID: 29312313; PMCID: PMC5732908.
11. Vaknin-Dembinsky A, Abramsky O, Petrou P, Ben-Hur T, Gotkine M, Brill L, et al. Myasthenia gravis associated neuromyelitis optica like disease: an immunological link between the central nervous system and muscle. *Arch Neurol* (2011) 68:1557–61. 10.1001/archneurol.2011.200
12. Iyer A, Elson L, Appleton R, Jacob A. A review of the current literature and a guide to the early diagnosis of immune disorders associated with neuromyelitis optica. *Autoimmunity* (2014) 47:154–61. 10.3109/08916934.2014.883501
13. Jarius, S., et al. “Neuromyelitis optica spectrum disorders in patients with myasthenia gravis: ten new aquaporin-4 antibody positive cases and a review of the literature.” *Multiple Sclerosis Journal* 18.8 (2012): 1135-1143