

RESEARCH ARTICLE

What are the factors affecting the mound displacement detected in endoscopic treatment failure of vesicoureteral reflux

Gokhan Demirtas¹, Tugrul Tiryaki²

¹Department Of Pediatric Urology, Sincan Training And Research Hospital

²Department Of Pediatric Urology, University Of Health Science Ankara City Hospital

Abstract

Article Info

Received Date: 08.01.2024

Revision Date: 08.02.2024

Accepted Date: 09.02.2024

Keywords:

Vesicoureteral reflux,

Children,

Endoscopic surgery

ORCID's of the authors:

GD : 0000-0003-0787-2330

TT : 0000-0002-9544-1137

Introduction: Success rates of endoscopic treatment for vesicoureteral reflux range from 50-100%. Various factors predict outcomes after endoscopic injection. Mound displacement is one of the most critical factors for failure. We observed mound displacement in most of the patients with endoscopic injection failure. We aimed to evaluate predisposing factors for mound displacement in patients with endoscopic injection for vesicoureteral reflux.

Methods: In 2020, operative images were taken and archived in cases where the endoscopic injection was applied due to vesicoureteral reflux. The localization of the bulking agent was evaluated during the redo procedure in 11 patients who were re-admitted due to the failure of the injection procedure. In addition, age, gender, side and degree of reflux, bladder thickness in US, and bladder trabeculation were evaluated.

Results: Local migration of bulking agent was seen in 11 patients at cystoscopy after initial treatment failure. Our repeat endoscopic injection rate was 11/80 (13.75%). Bladder wall thickness and/or trabeculation, constipation, and post-voiding residue (over 20 ml) were significantly higher in patients with mound displacement.

Conclusion: Patients with thick bladder walls with increased PVR and accompanying constipation have the risk of mound displacement. Therefore, we recommend performing a cystoscopy in all cases with recurrence to evaluate the location of the bulking agent. If the mound displacement is noted, we recommend reinjection. Patients with a thick bladder wall, postvoiding residue, and concomitant constipation are at increased risk of bulking agent displacement. If migration of bulking agent is detected, we recommend reinjection with Double HIT or multi-site injection techniques.

Correspondence Address: Gökçek Mah. 250 Cad. 2/A Sincan /Ankara - Türkiye

Phone: +90 506 634 02 17 / **e-mail:** drgokhandemirtas@gmail.com]



Copyright© 2023. Dey et al. This article is distributed under a Creative Commons Attribution 4.0 International License.

Follow this and additional works at: <https://achmedicaljournal.com>

Introduction

Endoscopic vesicoureteral reflux (VUR) treatment has gained popularity as an alternative to open surgeries in the past 30-40 years. It has been widely used since the application materials are easy to use without complication in outpatients.¹⁻³ Unfortunately, recurrence rates of VUR after endoscopic injection appear to be around 15–20 % .⁴

The efficacy of Dx/HA injection has been difficult to fully define, given that reported success rates range from 50% to 100% .^{5,6} Various factors that predict outcome after an endoscopic injection, such as gender,⁷ age,⁷ preoperative VUR grade,⁸⁻¹² renal scarring,¹² surgeon experience,^{8,9,13} injected volume,^{10,13} mound appearance,^{10,14} and dysfunctional voiding,¹⁵ had been determined.

However, in our cystoscopic evaluation of patients who were reoperated for the failure of the STING procedure, we observed mound displacement in most of the patients (figure1). Therefore, this study aimed to determine the factors causing the mound displacement in the cases where reinjection was applied for the failure of the STING procedure.

Figure 1

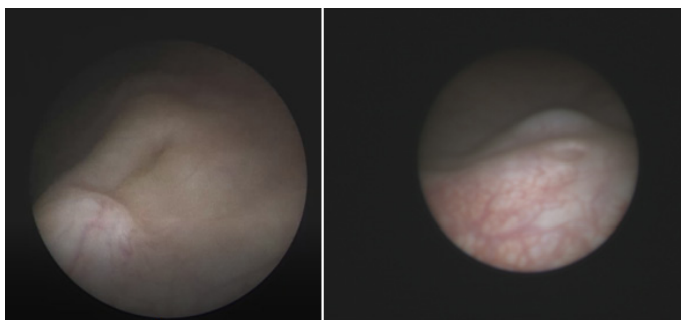


Figure 1. Displacement of the mound in subureteric injection. The mound moved the caudal direction of the orifice and the cranial direction in the left and right images, respectively

Material and Methods

Eighty cases of VUR who underwent subureteric Diethylaminoethyl-Dextran (DEAE-Dextran)+Hyalurinic acid (HA) (Dexell, Istem Medical Ankara Turkey) injection was prospectively evaluated in the study between January 01 and December 31, 2020. The local ethics committee approved this study (ref. No. E2-21-798).

1 ml of the bulking agent was routinely injected with the classical STING method. Additional 1 ml bulking agent was used in cases where coaptati-

on could not be achieved. No routine VCUg was performed in the follow-up after the STING application. Patients who did not experience recurrent urinary tract infections after STING were considered to have had successful treatment, and no imaging was performed to determine the location of the bulking agent in these patients. However, VCUg was performed in cases with recurrent urinary tract infections in the follow-up. In cases with persistent VUR, cystoscopy was performed again, and the location of the injection bulking agent and hydrodistension at the ureteral orifice was evaluated. We only performed repeat cystoscopy on the patients with clinical failure and persistent VUR on cystogram and compared these patients with those with clinical success.

We tried to determine whether the injection was done with the proper technique by comparing the archive images of the interventions belonging to the endoscopic procedures. We compared the reoperation image records of the patients we encountered with recurrence during the follow-up with the image records of the first intervention in which we performed the endoscopic injection. The STING was applied again in cases with local migration of the injection bulking agent and/or ureteral hydrodistention. Open surgery was performed in cases where the bulking agent was found to be in place on cystoscopy, but the VUR persisted despite this.

Cases with secondary VUR, such as neurogenic bladder, duplicated system, or posterior urethral valve, and cases with the first injection performed in another medical center were excluded from the study. We evaluated patients with clinical failure for mound displacement and other cases in terms of age, gender, side and degree of reflux, bladder thickness in ultrasound (US), and bladder trabeculation in cystoscopy. Urinary tract dysfunction was evaluated using the symptom-scoring questionnaire Akbal et al. prepared.¹⁶ Constipation was evaluated according to the ROMA IV criteria.¹⁷ Bladder wall thickness was measured as the ventral wall thickness in the full bladder in US.¹⁸ Two groups were compared by Chi-square test. Statistical significance was considered $p < 0.05$. The SPSS 17.0 software program was used to perform statistical analysis.

Results

Eighty cases aged between 5 months and 17 years (mean 4.54+3.26 years; median 4.00+3.26 years) were evaluated. Twenty-two of the cases were

male, and 58 were female. In 14 cases referred to our clinic due to unsuccessful STING applications from other medical centers, two cases underwent ureteroneocystostomy, and 9 cases had neurogenic bladder, posterior urethral valve, or duplicated system excluded from the study. Reinjection was performed in 11 cases with persistent VUR among 80 cases whose first injections were made in our clinic. Mound displacement is noted in 7 cases and disappears in 4 cases total of 11 patients (13.75%) who underwent the first injection in our clinic. A total of 11 cases (2 male, 9 female; 2-6.5 years, average 3.86+1.55 years; median 4.00+1.55 years) reinjection was applied.

No statistically significant difference was noted between the ages of the cases with the migration of the bulking agent and the cases without migration ($p=0.246$). Furthermore, when the two groups were compared in terms of gender, no significant difference was found ($p=0.514$). Finally, no significant difference was found in comparing the side (unilateral/bilateral) and grade of reflux ($p=0.481$, $p=0.560$) (Table 1, 2, 3). A statistically significant difference in terms of symptom score was not detected between the two groups ($p=0.472$).

Table 1 Gender distribution of the two groups

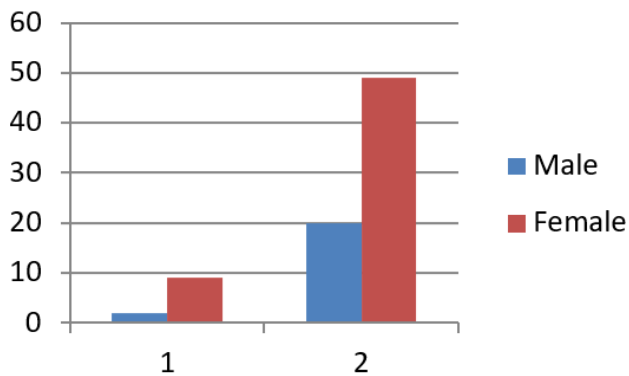


Table 2 Side of the VUR in patients with Redo and first injection

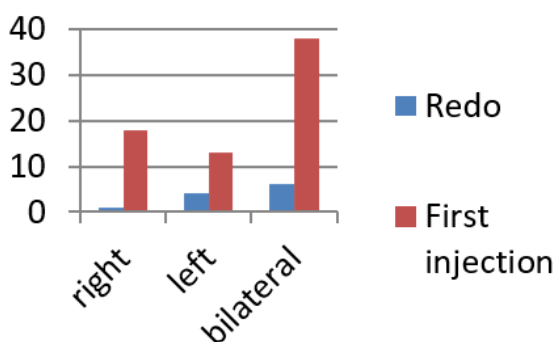
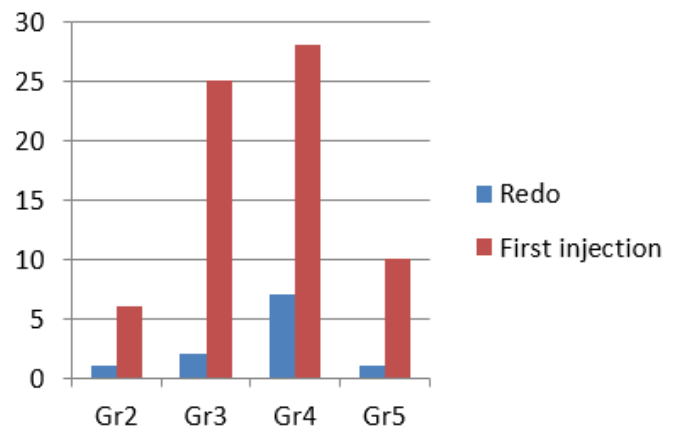


Table 3 Grade of the reflux in two groups



When the patients were evaluated in terms of bladder wall thickness and/or trabeculation, there was a significant difference ($p=0.001$). It was determined that the bladder wall thickness was more than 3 mm in cases where the bulking agent was displaced locally, and the trabeculation was more than in the non-displaced group. Also, it was observed that constipation was accompanied significantly more frequently where the bulking agent was changed ($p=0.003$). In addition, the post-voiding residue (over 20 ml) was significantly higher where the bulking agent was displaced ($p=0.001$).

Discussion

Cystoscopy was performed in 11 patients (13,75%) with recurrent febrile urinary tract infections and persistent reflux after the first injection in our series. In the cystoscopy evaluation of these eleven cases, it was found that the mound was displaced or not seen. Therefore, we performed the second injection in these 11 cases whose endoscopic treatment was unsuccessful in our series. Mound creation was determined by evaluating the archive images of 11 patients whose first injections were made in our clinic. We observed that it significantly increased the bladder wall thickness and trabeculation of the cases with local migration of the bulking agent compared to the other cases. Again in these cases, PVR was found to be significantly higher, and constipation was more common. With all these findings, it is possible to say that the risk of local migration of the bulking agent increases because of abnormal bladder dynamics in patients with bladder bowel dysfunction, a high amount of postvoiding residual urine, and a bladder thicker than 3 mm.

In a systematic meta-analysis evaluating the endoscopic treatment of pediatric VUR, the estima-

ted success rate for endoscopic therapy after a single injection was 78 % for grades I and II, 72 % for grade III, 63 % for IV, and 50 % for grade V VUR.¹⁹ The literature has reported that mound displacement is observed especially in cases with voiding dysfunction. Capozza et al. suggested that voiding dysfunction could contribute to endoscopic injection failure.¹⁵ They theorized that elevated intravesical pressures could displace or shift the injection mound or cause migration from the original site of implantation. They found that a high percentage of those patients who had failed initial endoscopic treatment had evidence of voiding dysfunction on clinical evaluation. Capozza et al. reported on 45 failures with the Dx/HA copolymer and found that 60% had mound displacement and 33% had an absence of the mound on reinspection.²⁰ They reported a high percentage of their cases with failed dextranomer microspheres and suspected high intravesical pressures noted by voiding diaries. Trsinar et al. also observed displacement of failed injection mounds and theorized that this was due to voiding dysfunction, although no urodynamic studies or voiding diaries were presented.²¹ Kirsch et al.²² reported on 18 patients who underwent reinjection for primary failures and found that 61% had shifting of the mound away from the injection site. In the remainder of the patients, the mound was either absent or present and indeterminate. Higham-Kessler et al. reported a multi-institutional review of failures after Dx/HA injections for VUR.²³ Eighty patients (97 ureters) who failed a single injection underwent mound observation prior to a second injection or at the time of open surgery. They found that in those with a mound abnormality, 49% of the mound had shifted, 22% of the mound was absent, and 10% there was a significant mound volume loss. In 15%, the mound was in the perfect location despite persistent VUR. In such a case, the question of whether the injection was made in the right place in the first application comes to mind. While the first injection images of the cases with VUR recurrence were evaluated in our study, there is no data on the evaluation of the first injection image in all these studies. When the archive images were examined retrospectively, it was determined that the mound was formed by appropriate injection in the first attempts in our series. In addition, voiding dysfunction was evaluated clinically in these studies. In such patients, STING and bladder rehabilitation are expected to prevent local

migration of the bulking agent and recurrence. Although some studies noted no differences in the ureter or patient resolution between endoscopic Dx/HA injection techniques, the HIT or double HIT procedure is associated with better VUR correction rates.^{24,25} In the Double HIT technique, coaptation in the distal of the ureter continues in the local migration that may be towards the caudal. Therefore, injection with the Double HIT technique should be attempted first in cases with a thick trabeculate bladder wall, high amount of PVR, and accompanied constipation.²⁶ The most important limitation of our study is that we performed repeat cystoscopy and VCUG only in case of clinical failure. In clinically successful cases, the comparison was not possible since it is not known how the mound created by injection is.

In conclusion, the reinjection rate after the STING procedure is 13.75% in our series. Mound displacement is noted in all of these patients. Bladder wall thickness and/or trabeculation, constipation and post-voiding residue were significant factors for bulking agent displacement.

References

1. Herbst KW, Corbett ST, Lendvay TS, Caldame AA. Recent trends in the surgical management of primary vesicoureteral reflux in the era of dextranomer/hyaluronic acid. *J Urol* 2014; 191:1628–33.
2. Hacker FM, Frech-Dorfler M, vonRotz M, Rudin C. Endoscopic hyaluronic acid/dextranomer gel implantation is effective as first-line treatment of vesicoureteral reflux in children: a single center experience. *Eur J Pediatr Surg* 2011;21: 299-303.
3. Lackgren G, Stenberg A. Endoscopic treatment of vesicoureteral reflux: current practice and the need for multifactorial assessment. *Ther Adv Urol* 2009;1:131-41.
4. Hoberman A, Greenfield SP, Mattoo TK, Keren R, Mathews R, Pohl HG et al. The RIVUR Trial Investigators, Antimicrobial Prophylaxis for Children with Vesicoureteral Reflux. *N Engl J Med*. 2014;370:2367–76.
5. Dave S, Lorenzo AJ, Khoury AE et al. Learning from the learning curve: factors associated with successful endoscopic correction of vesicoureteral reflux using dextranomer/hyaluronic acid copolymer. *J Urol* 2008;180:1594–9.
6. Puri P, Chertin B, Velayudham M, Dass L, Colhoun Treatment of vesicoureteral reflux by endos-

- copic injection of dextranomer/hyaluronic acid copolymer: preliminary results. *J Urol* 2003;170:1541–4.
7. Puri P, Kutasy B, Colhoun E, Hunziker M. Single center experience with endoscopic subureteral dextranomer/hyaluronic acid injection as first line treatment in 1,551 children with intermediate and high grade vesicoureteral reflux. *J Urol* 2012; 188:1485–9.
 8. Routh JC, Inman BA, Reinberg Y. Dextranomer /hyaluronic acid for pediatric vesicoureteral reflux: systematic review. *Pediatrics* 2010;125:1010–9.
 9. Lorenzo AJ, Salle JLP, Barroso U, Cook A, Grober E, Wallis MC, et al. What are the most powerful determinants of endoscopic vesicoureteral reflux correction? Multivariate analysis of a single institution experience during 6 years. *J Urol* 2006;176:1851–5.
 10. Yucel S, Gupta A, Snodgrass W. Multivariate analysis of factors predicting success with dextranomer/hyaluronic acid injection for vesicoureteral reflux. *J Urol* 2007; 177:1505–9. doi: 10.1016/j.juro.2006.11.077.
 11. Routh JC, Reinberg Y. Predicting success in the endoscopic management of pediatric vesicoureteral reflux. *Urology* 2010;76:195–8.
 12. Haid B, Berger C, Roesch J, Becker T, Koen M, Langsteger W. et al. Persistence and recurrence of vesicoureteric reflux in children after endoscopic therapy — implications of a risk-adapted follow-up. *Cent Eur J Urol* 2015;68:389–95.
 13. Chandrasekharam VVS. Do Volume of Injection and Learning Curve Influence the results of Endoscopic Correction of Vesicoureteric Reflux Using Dextranomer/Hyaluronic Acid? A Single Surgeon Experience. *J Laparoendosc Adv Surg Tech A* 2021;31:220-224.
 14. Lavelle MT, Conlin MJ, Skoog SJ. Subureteral injection of Deflux for correction of reflux: analysis of factors predicting success. *Urology* 2005;65:564–7.
 15. Capozza N, Lais A, Nappo S, Caione P. The role of endoscopic treatment of vesicoureteral reflux: a 17-year experience. *J Urol* 2004;172:1626–8.
 16. Akbal C, Genc Y, Burgu B, Ozden E, Tekgul S. Dysfunctional voiding and incontinence scoring system: quantitative evaluation of incontinence symptoms in pediatric population. *J Urol*. 2005 Mar; 173(3):969-73
 17. Palsson OS, Whitehead WE, van Tilburg MA, et al. Rome IV Diagnostic Questionnaires and Tables for Investigators and Clinicians. *Gastroenterology*, 13 Feb 2016, :S0016-5085(16)00180-3
 18. Müller L, Bergström T, Hellström M, Svensson E, Jacobsson B. Standardized ultrasound method for assessing detrusor muscle thickness in children *J Urol*. 2000 Jul;164(1):134-8.
 19. Elder JS, Diaz M, Calamone AA, Greenfield S, Hurwitz R, Kirsch A. et al. Endoscopic therapy for vesicoureteral reflux: a meta-analysis. I. Reflux resolution and urinary tract infection. *J Urol*. 2006;175:716–22. doi: 10.1016/S0022-5347(05)00210-7.
 20. Capozza N, Lais A, Matarazzo E, Nappo S, Patricolo M, Caione P. Influence of voiding dysfunction on the outcome of endoscopic treatment for vesicoureteral reflux. *J Urol* 2002;168:1695–8.
 21. Trsinar B, Cotic D, Oblak C. Possible causes of unsuccessful endoscopic collagen treatment of vesicoureteral reflux in children. *Eur Urol* 1999;36:635–9.
 22. Kirsch AJ. Injection therapy for reflux: Why it Works and why it fails. *J Urol* 2012;188:16–7.
 23. Higham-Kessler J, Reinert SE, Snodgrass WT, Hensle TW, Koyle MA, Hurwitz RS et al. A review of failures of endoscopic treatment of vesicoureteral reflux with dextranomer microspheres. *J Urol* 2007;177:710–5.
 24. Te-Lu Yap, Yong Chen, Shireen A. Nah, Caroline Choo Phaik Ong, Anette Jacobsen, Yee. Low STING versus HIT technique of endoscopic treatment for vesicoureteral reflux: A systematic review and meta-analysis. *J Pediatric Surgery* 2016;51 2015–2020.
 25. Sean T. Watters, Jennifer Sung, Steven J. Skoog. Endoscopic treatment for vesicoureteral reflux: How important is technique? *J Pediatric Urology* 2013;9, 1192-1197
 26. Jonathan F. Kalisvaart, Hal C. Scherz, Scott Cuda, Jonathan D. Kaye, Andrew J. Kirsch Intermediate to long-term follow-up indicates low risk of recurrence after Double HIT endoscopic treatment for primary vesico-ureteral reflux *J Pediatr Urology* 2012; 8:359-365.