

Multidisciplinary Approach and Clinical Algorithm in Resection and Reconstruction for Chest Wall Tumor

Toraks Duvarı Tümörlerinde Göğüs Duvarı Rezeksiyonu-Rekonstrüksiyonunda Multidisipliner Yaklaşım ve Klinik Algoritmamız

Recep DEMİRHAN,¹ Gökhan TEMİZ,² Kaan GİDEROĞLU,² Emre GÜVERCİN,²
Engin Ersin ŞİMŞEK,³ Gaye TAYLAN FİLİNTE,² Kadir Burak ÖZER¹

¹Department of Thoracic Surgery, Kartal Dr. Lütfi Kırdar Training and Research Hospital, İstanbul, Turkey

²Department of Plastic Surgery, Kartal Dr. Lütfi Kırdar Training and Research Hospital, İstanbul, Turkey

³Department of Family Medicine, Kartal Dr. Lütfi Kırdar Training and Research Hospital, İstanbul, Turkey

Summary

Background: The aim of this study was to retrospectively review files of patients who had tumor resection and reconstructive surgery performed by thoracic and plastic surgeons due to chest wall tumor, and to create reconstruction algorithm.

Methods: Records of 45 patients who underwent surgery for chest wall tumor between 2006–2014 were included in this study. Data including age, sex, tumor localization, defect size, quantity of resected costa and bone, and method of skeletal and soft tissue reconstruction were gathered retrospectively from patient files.

Results: The largest defect was 325 cm² and smallest was 36 cm². Titanium mesh was used in 54% of patients, while prolene mesh was used in 32%. Pectoralis kite flap (n=14), latissimus dorsi muscle-skin muscle flap (n=12), latissimus dorsi muscle flap and pectoral kite flap (n=5), vertical rectus abdominus skin muscle flap (n=6), omentum flap (n=3), transvers rectus abdominus skin muscle flap (n=3), free anterolateral thigh flap (n=2), and local rotation flap (n=1) were used for soft tissue reconstruction.

Conclusion: Algorithm for soft and skeletal tissue reconstruction was created in accordance with obtained data.

Keywords: Algorithm; multidisciplinary approach; chest wall reconstruction; chest wall resection; chest wall tumor.

Özet

Amaç: Bu çalışmada multidisipliner yaklaşımla toraks duvarı tümörü nedeniyle rezeksiyon ve onarım yapılan hastaların geriye dönük olarak incelenerek bir rekonstrüksiyon algoritması oluşturulması planlandı.

Gereç ve Yöntem: Hastanemizde 2006–2014 yılları arasında toraks duvarı tümörü nedeniyle ameliyat edilen 45 hasta çalışmaya dahil edildi. Hastaların yaşı, cinsiyeti, tümör lokalizasyonu, rezeksiyon sonrası oluşan defekt boyutları, kot rezeksiyonu yapılıp yapılmadığı, iskelet rekonstrüksiyon yöntemi, yumuşak doku onarımının hangi fleple yapıldığı, hastaların dosyalarından geriye dönük olarak tarandı.

Bulgular: Onarılan en büyük defekt 325 cm², en küçük defekt 36 cm² idi. Olguların %54'ünde titanyum mesh %32'sinde ise prolene mesh kullanıldığı saptandı. Yumuşak doku onarımında ise pektoralis majör kite flap (n=14), latissimus kas-kas deri flebi (n=12), latissimus kas deri flebi ile kombine pektoral kite flep (n=5), vertikal rektus abdominus kas deri flebi (n=6), omentum flebi (n=3), transvers rektus abdominus kas deri flebi (n=3), serbest anterolateral uyluk flebi (n=2) ve lokal rotasyon flebi (n=1) kullanıldığı tespit edildi.

Sonuç: Elde edilen veriler ışığında iskelet ve yumuşak doku rekonstrüksiyonu için algoritmalar oluşturuldu.

Anahtar sözcükler: Algoritma; multidisipliner yaklaşım; toraks duvarı rekonstrüksiyonu; toraks duvarı rezeksiyonu; toraks duvarı tümörü.

Correspondence: Dr. Recep Demirhan.
Saraylar Caddesi, Başarar Apt., No: 42/2,
Cevizli, Kartal, İstanbul
Phone: +90 216 - 458 30 11

Received: 11.07.2016
Accepted: 19.07.2016
Online date: 22.07.2016
e-mail: recepdemirhan@hotmail.com



Introduction

Large chest wall defects can occur as result of resection due to etiologies such as tumor or radionecrosis in chest wall. Soft tissue and bony skeleton may be affected.^[1,2] There may be synthetic vascular structures at base of defect, and in addition, defects of diaphragm or anterior abdominal wall can develop. Large areas of damage, loss of skeletal support, and deep dead spaces are characteristic features of these defects. When contribution of chest wall to respiration, its role in protecting vital organs, and support provided to shoulder joint are considered, importance of reconstruction is evident.^[2,3] After reconstruction of skeletal defects larger than 5 cm, robust soft tissue coverage is the goal. Generally, pedunculated muscle and musculoskeletal flaps are currently preferred for reconstruction of chest wall defects.^[4]

The present study investigated type of flap used and short- and long-term complications of 45 patients who underwent full-thickness chest wall resection and reconstruction in order to formulate a repair algorithm.

Patients and Methods

Records of 45 patients who were operated on in chest surgery and reconstructive surgery clinics between 2006 and 2014 were analyzed retrospectively, after local ethic comitee approval. Demographic data (age and gender) of patients were recorded, as well as primary or recurrent nature, size of defect, presence of bone resection, and number of resected ribs. Methods used for skeletal reconstruction were evaluated based on type of defect. Results of follow-up were also recorded, including postoperative complications and methods used to address them.

Results

Study population consisted of 26 female and 19 male patients with overall mean age of 53.4 years. Mean

follow-up period was 58 months. In all patients, etiological factors were chest wall tumor and related complications. Nine patients were recurrent cases who had previously undergone primary repair. All patients underwent full-thickness chest wall resection. Nearly 2 (range: 1-4) ribs were resected in each patient. Patients had undergone sternal resection (n=9), concurrent rib, and clavicular resection (n=10). Largest defect was 325 cm² and smallest was 36 cm². Pectoralis kite flap (n=11), latissimus dorsi muscle-skin muscle flap (n=12), latissimus dorsi skin-muscle flap combined with pectoralis kite flap (n=5), vertical rectus abdominus skin-muscle flap (VRAM) (n=5), omentum flap (n=3), transverse rectus abdominis skin-muscle flap (TRAM), rotation-advancement flap (n=4), and free anterolateral thigh flap (ALT) (n=2) were used to reconstruct defects (Figures 1a–d). In 24 patients, titanium mesh was used, and prolene mesh was used for reconstruction of skeletal tissue in 14 patients (Table 1). Total flap loss was not observed in any patient. In 2 of 3 patients who developed infections, synthetic materials (prolene and titanium mesh) were used. In 1 patient, reconstruction of skeletal tissue was not performed. For 1 patient, in whom alloplastic material was not used, antibiotherapy and local wound care were sufficient to defeat infection. When titanium or prolene mesh was used, infection could not be brought under control with wound care and systemic antibiotherapy. Complete removal of synthetic materials was necessary before infection regressed and complete wound healing occurred. In 3 of 6 patients with partial flap loss, due to possibility of extrusion of mesh, defects were debrided in early phase and closed with local flaps to protect defect from mesh infection. Minimal complications such as minor hematoma and delay in wound healing were seen and treated successfully without additional surgical intervention (Table 2). Soft tissue reconstruction algorithm was formulated based on location and size

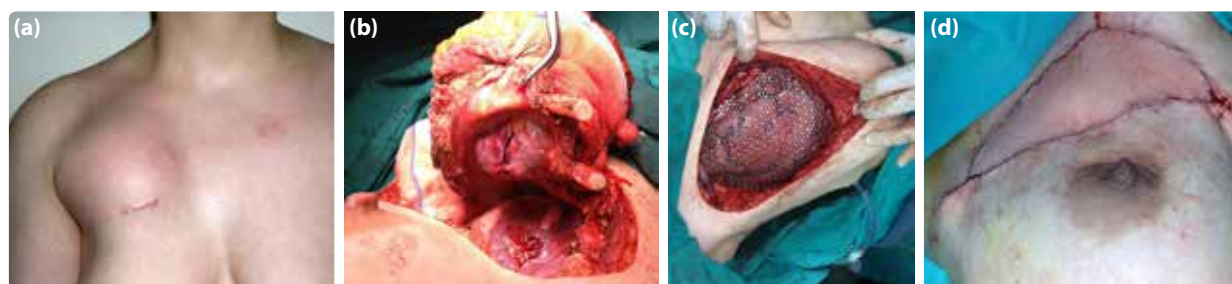


Figure 1. (a) Malignant mesenchymal tumor localized on the anterior chest wall with clavicular involvement. (b) Image obtained during resection. (c) Skeletal tissue reconstruction with titanium mesh. (d) The image taken after completion of the repair with latissimus dorsi skin-muscle flap.

Table 1. Type of flaps used for the patients, localization, and size of the defects, and numerical values related to resections applied for ribs, and bony structures

Flap group	Average defect area (cm ²)	Average number of resected ribs	Maximum number of resected ribs	Clavicular resection	Sternal resection	Localization
Pectoral kite flap (n=11)	154	1.6	3	4	2	11 upper 1/3
Latisimus dorsi (n=12)	176	2	3	2	2	4 upper 1/3 4 middle 1/3 2 upper and middle 1/3 2 lateral
Latisimus dorsi + pectoral kite (n=5)	210	2.8	4	3	1	5 upper 1/3
VRAM (n=6)	136	2.3	3	–	2	4 middle 1/3 2 lower 1/3
TRAM (n=2)	130	1.5	2	–	–	2 lower, and middle 1/3
Free ALT flap (n=2)	164	2.5	3	1	1	2 upper and middle 1/3
Omentum (n=3)	240	1.6	2	–	1	Together with lower abdominal wall 1/3
Rotation-advancement (n=4)	128	1.7	3	–	–	3 lower 1/3 1 lateral

VRAM: Vertical rectus abdominus skin-muscle flap; TRAM: transverse rectus abdominis skin-muscle flap; ALT: Anterolateral thigh flap.

of defect, previous surgery, and status of flap pedicles (damaged or intact) (Figure 2). Skeletal tissue reconstruction algorithm was also designed, based on location and size of defect (Figure 3).

Table 2. Complications, and their incidences

Complications	Sayı	Incidence (%)
Total flap loss	0	0
Partial flap loss (<50%)	6	13.3
Hematoma	4	8.8
Infection	3	6.6
Delay in wound healing	5	11.1
Dehiscence	4	8.8
Vascular thrombosis	0	0

Discussion

Musculoskeletal system of chest wall plays important role in protection of intrathoracic visceral organs, expansion of thoracic cage during respiration, and stabilization of shoulder joint. Therefore, all surgeons who will perform operations on this region should be familiar with its complex anatomy and physiology. There are intricate interrelationships between nerves, vessels, cartilage, and muscle within chest wall that can cause widespread distribution of numerous common pathologies.^[5] Soft tissue sarcomas constitute majority of malignant chest wall lesions, and 6% of all soft tissue sarcomas are observed in this region, including malignant fibrous histiosarcoma, liposarcoma, neurofibrosarcoma, angiosarcoma, and fibrosarcoma. Malignant lesions stemming from skeletal system constitute 55% of all malignant lesions of chest wall. Most frequently seen is chondrosarcoma, as well as osteo-

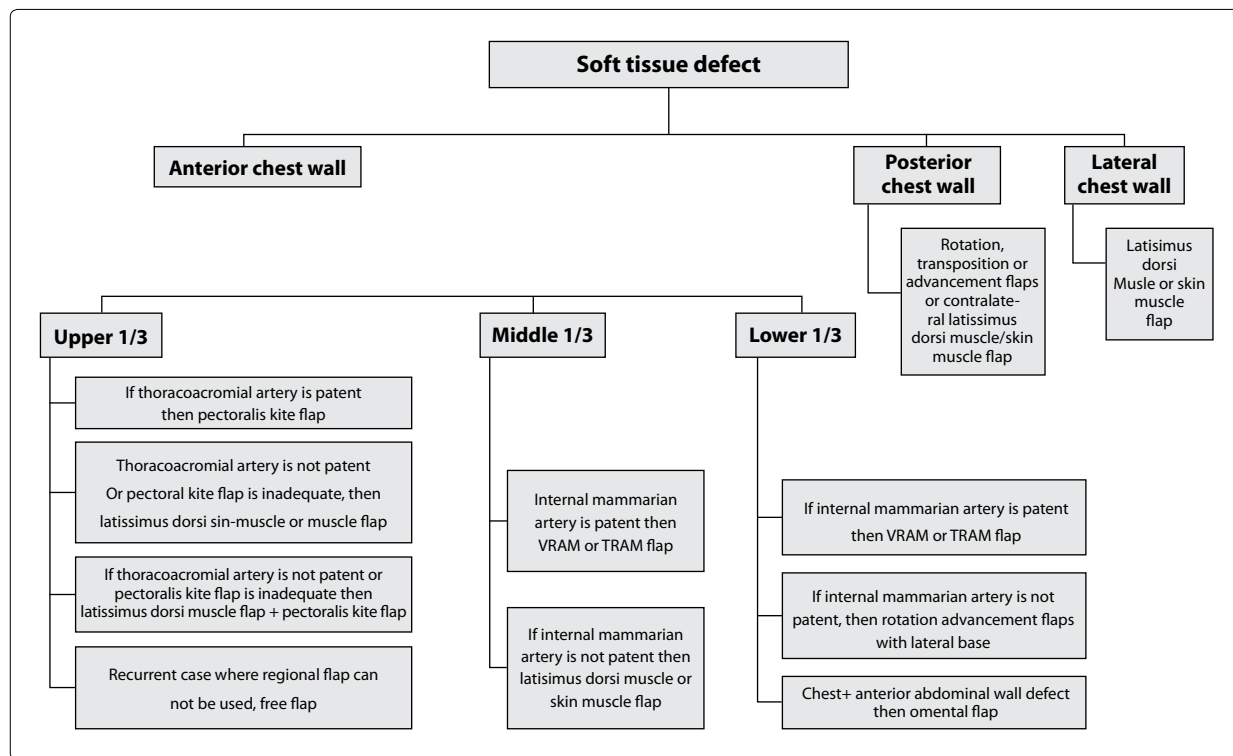


Figure 2. Algorithm formulated for soft tissue reconstruction.

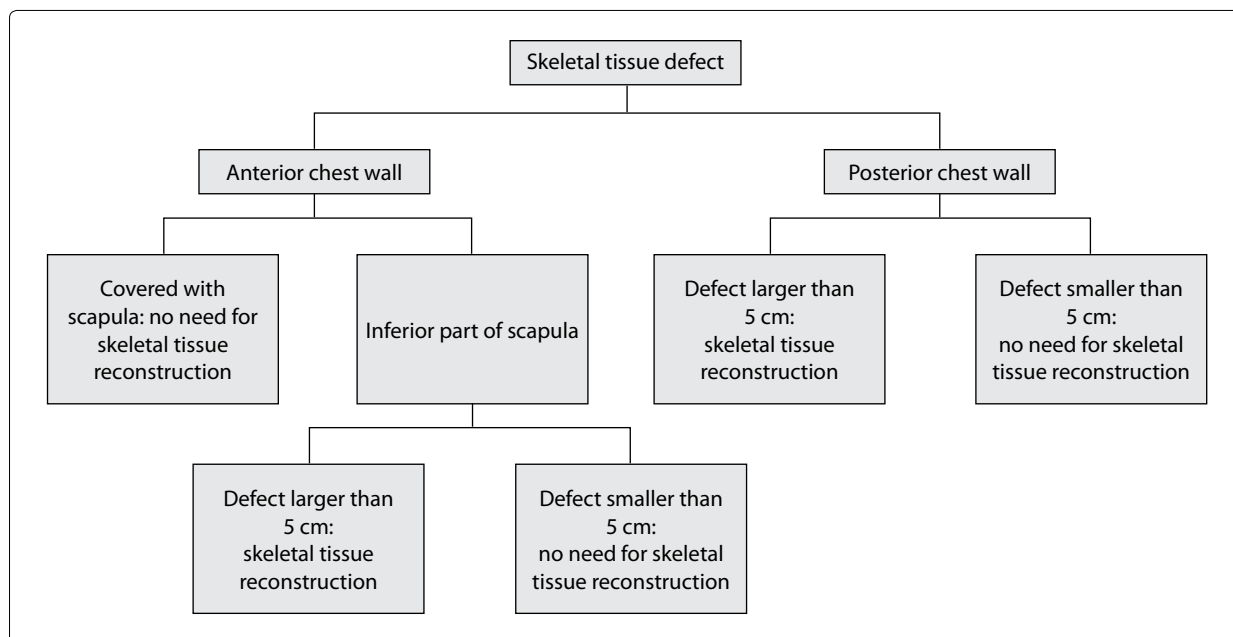


Figure 3. Algorithm formulated for skeletal tissue reconstruction.

sarcoma and Ewing sarcoma. In addition, breast or lung cancer, or metastatic lesions without primary foci may be encountered.^[6] Achievement of suitable surgical margins depends on histology of tumor. Surgical margin has key role in recurrence-free survival.^[2,7] Rate of local recurrence of chondrosarcoma has been re-

ported as highly dependent on surgical margin, ranging from 4% to 73%.^[8] In treatment of soft tissue sarcoma on lower and upper extremities, compartment resection approach has been the accepted mode of treatment, but no such approach has existed for chest wall sarcoma. Primary tumor easily infiltrates ribs and

skeletal tissue, necessitating resection of chest wall. In recurrent cases, even if infiltration of skeletal tissue does not occur, resection of chest wall should be performed to ensure disease-free surgical margin.^[9] For high-grade tumors, adequate surgical margin is 4 cm in width, while for low-grade tumors, surgical margins of 1–2 cm in width will usually suffice.^[7] Therefore, for satisfactory surgery, full-thickness chest wall resection should be performed in cases with chest wall sarcoma. Our principles for reconstruction after resection are as follows: (1) defects smaller than 4–5 cm do not require skeletal tissue reconstruction, (2) defects covered with posterior scapula do not require reconstruction, and (3) skeletal stabilization can be performed using autologous tissue, mesh, Gore-Tex® or methyl methacrylate. For soft tissue reconstruction, flaps are almost always required.^[5]

For reconstruction of central and lateral defects in infraclavicular region, latissimus dorsi muscle flap, free or pedicled TRAM or VRAM flaps are recommended. Pectoralis major muscle flap is apparently preferred for central defects in cases with sternal osteomyelitis or mediastinitis.^[10] In our cases, contrary to literature data, following reconstruction of lesions localized in infraclavicular region, remaining segment of pectoralis muscle was transferred over acromioclavicular artery to infraclavicular region.^[11] When defect extended beyond middle third of segment and pectoralis muscle was not sufficient to close the defect per se, latissimus dorsi muscle flap was also used to achieve durable reconstruction. As a result of resection, pectoralis muscle becomes nonfunctional, and in this case, use of ipsilateral latissimus dorsi muscle results in dysfunctional shoulder joint. Use of ipsilateral pectoralis muscle can achieve reconstruction of medium-sized defects without creating additional donor site morbidity.

Rectus abdominis muscle flap is one of the durable flaps used for repair of chest wall defects. Based on localization of skin island, it may be either transverse or vertical flap. Based on configuration of defect, skin island can be modified. This flap is often used for thoracic reconstruction due to its superior base; however, in the absence of internal mammary artery (IMA), many publications emphasize elevation of flap with intercostal artery support.^[12] We thought that this approach could increase complication rates, so we preferred to plan a contralateral flap. In cases with bilateral absence of IMA, reconstruction was achieved with different flaps.

Latissimus dorsi muscle and skin-muscle flaps may be preferred for reconstruction of lateral and anterior defects. Due to large muscle area, a large defect can be repaired with perfectly vascularized tissue graft.^[13] Muscle flap is covered with skin graft to ensure successful closure of defect. Size of this flap can somewhat prevent approach to midline, so for closure of defects near midline, generally, combined use of this flap with contralateral pectoralis major muscle flap was preferred.

Local flaps are frequently used for reconstruction of chest wall. Properly prepared local flaps can close defects that are suitable and in cases where defect size is not so great. Perforators of the superior epigastric artery with a base, or on lateral side, perforators of intercostal artery with a base, have been used successfully in reconstruction of inferiorly located defects.^[4]

In the literature, oncological indications for chest wall reconstruction have primarily been breast cancer and sarcoma.^[14] In present case series, none of patients had indication of invasive breast cancer; patients with advanced stage breast cancer are considered inoperable cases. In the literature, average postoperative morbidity rate for full-thickness chest wall reconstruction has been indicated as 18%. In oncological cases and cases with radionecrosis, morbidity rates have been reported as 11% and 50%, respectively.^[1] In present case study, average morbidity rate of 20% is consistent with literature findings. Although prevention of local recurrence does not always increase survival rate, it is known to improve patient quality of life.^[2,7]

One of the most important factors affecting hospital stay and onset of additional oncological treatment is infection in contaminated synthetic materials used for reconstruction of skeletal tissue.^[15] Infection can occur due to contamination of the material during surgery, as a result of dehiscence of suture lines, or synthetic material extrusion following partial necrosis of flap. Once infection develops in the synthetic material, treatment with systemic antibiotic and wound care cannot be achieved most of the times. In cases of suture dehiscence, if synthetic material is found on base of defect, revision should be performed at early stage. If partial flap necrosis is detected, necrotic portion at base of defect should be debrided. When necessary, defect should be closed with local flaps before development of infection in synthetic material. If chronic infection develops in the mesh and manifests with

unhealed wounds and chronic draining lesions, synthetic material under flap should be removed completely. Afterward, treatment should be continued with systemic antibiotherapy.

Following full-thickness resection of chest wall, single-section reconstruction of defects is a reliable and effective procedure. Closure of skeletal structure reconstructed with synthetic material using well-perfused tissue helps prevent local recurrence and decreases incidence of postoperative complications. To achieve optimal conditions for patient, treatment and monitoring with multidisciplinary team that includes thoracic and reconstructive surgeons is ideal approach. In well-planned cases, recurrences and complications can be minimized even in large, complicated defects.

Conflict of interest

None declared.

References

1. Bosc R, Lepage C, Hamou C, Matar N, Benjoar MD, Hivelin M, et al. Management of chest wall reconstruction after resection for cancer: a retrospective study of 22 consecutive patients. *Ann Plast Surg* 2011;67:263–8. [Crossref](#)
2. Demirhan R, Eryiğit H, Kaya B. Primary chest wall tumors: a 10-year experience. *Türk Göğüs Kalp Damar Cer Derg* 2009;17:278–81.
3. Netscher DT, Baumholtz MA. Chest reconstruction: I. Anterior and anterolateral chest wall and wounds affecting respiratory function. *Plast Reconstr Surg* 2009;124:240–52. [Crossref](#)
4. Ertaş MN, Yüce S, Özpolat B, Çelebioğlu S. Göğüs ve karın duvarı rekonstruksiyonlarında torakoepigastrik flep deneyimlerimiz. *Türk Plast Rekonstr Est Cer Derg* 2005;13:170–4.
5. David EA, Marshall MB. Review of chest wall tumors: a diagnostic, therapeutic, and reconstructive challenge. *Semin Plast Surg* 2011;25:16–24. [Crossref](#)
6. Haraguchi S, Hioki M, Takushima M, Yanagimoto K, Koizumi K, Shimizu K. Metastatic chest wall tumor suspected to be of lung origin by immunoreactivity for cytokeratin 7 and 20. *Jpn J Thorac Cardiovasc Surg* 2006;54:132–6.
7. King RM, Pairolero PC, Trastek VF, Piehler JM, Payne WS, Bernatz PE. Primary chest wall tumors: factors affecting survival. *Ann Thorac Surg* 1986;41:597–601. [Crossref](#)
8. Widhe B, Bauer HC; Scandinavian Sarcoma Group. Surgical treatment is decisive for outcome in chondrosarcoma of the chest wall: a population-based Scandinavian Sarcoma Group study of 106 patients. *J Thorac Cardiovasc Surg* 2009;137:610–4. [Crossref](#)
9. Tsukushi S, Nishida Y, Sugiura H, Nakashima H, Ishiguro N. Soft tissue sarcomas of the chest wall. *J Thorac Oncol* 2009;4:834–7. [Crossref](#)
10. Tizian C, Borst HG, Berger A. Treatment of total sternal necrosis using the latissimus dorsi muscle flap. *Plast Reconstr Surg* 1985;76:703–7. [Crossref](#)
11. Temiz G, Şirinoğlu H, Yeşiloğlu N, Sarıcı M, Çardak ME, Demirhan R, et al. A salvage maneuver for the caudal part of the pectoralis major muscle in the reconstruction of superior thoracic wall defects: The pectoralis kite flap. *J Plast Reconstr Aesthet Surg* 2015;68:698–704. [Crossref](#)
12. Arnold PG, Pairolero PC. Chest-wall reconstruction: an account of 500 consecutive patients. *Plast Reconstr Surg* 1996;98:804–10. [Crossref](#)
13. Shaw WW, Aston SJ, Zide BM. Reconstruction of the trunk. In: McCarthy JG, editor. *Plastic surgery*. Philadelphia: W.B. Saunders; 1990. p. 675–3796.
14. Riedel K, Kremer T, Hoffmann H, Pfannschmidt J, Reimer P, Dienemann H, et al. Plastic surgical reconstruction of extensive thoracic wall defects after oncologic resection. *Chirurg* 2008;79:164–74. [Crossref](#)
15. Huang H, Kitano K, Nagayama K, Nitadori J, Anraku M, Murakawa T, et al. Results of bony chest wall reconstruction with expanded polytetrafluoroethylene soft tissue patch. *Ann Thorac Cardiovasc Surg* 2015;21:119–24.