



A Rare Case: Pulmonary Xanthoma

Nadir Bir Vaka: Pulmoner Ksantom

Mehlika İşcan¹, Merve Ekinci², Nil Comunoğlu³, Mehmet Kamil Kaynak²

¹Thoracic Surgery Clinic, Gebze Fatih State Hospital, Kocaeli; ²Department of Thoracic Surgery, Cerrahpaşa School of Medicine, Istanbul University, Istanbul; ³Department of Pathology, Cerrahpaşa School of Medicine, Istanbul University, Istanbul, Turkey

ABSTRACT

Pulmonary xanthoma is a benign lesion that may be associated with hyperlipidemia due to lipid metabolism disorders. A 31-year-old male who had no known co-morbidities was admitted to the hospital with an intractable cough. Chest computed tomography (CT) revealed a relatively homogenous mass lesion with a diameter of 38 mm localized in the left upper lobe. Videothoracoscopic resection of the lesion was performed, and detailed pathological analyses were conclusive for pulmonary xanthoma. The patient was found to have hepatosteatosi and hyperlipidemia. No complications were reported, and the patient had no complaints for 12 months.

Key words: pulmonary xanthoma; videothoracoscopic surgery; hyperlipidemia

ÖZET

Pulmoner ksantom, lipid metabolizması bozukluklarına bağlı olarak hiperlipidemi ile ilişkili benign bir lezyondur. Komorbiditesi olmayan 31 yaşında erkek hasta inatçı öksürük nedeniyle hastaneye başvurdu. Toraks bilgisayarlı tomografide (BT) sol üst lobda 38 mm çapında homojen bir kitle lezyonu izlendi. Lezyonun videotorakoskopik rezeksiyonu sonrası tanısı pulmoner ksantom olarak raporlandı. Hastada hepatosteatoz ve hiperlipidemi tespit edildi. Hasta, ameliyat sonrasında 12 aydır başka bir problem olmaksızın takip edilmektedir.

Anahtar kelimeler: pulmoner ksantom; videotorakoskopik cerrahi; hiperlipidemi

Introduction

Xanthomas are benign lesions of lipid-laden histiocytes, which usually develop based on hyperlipidemia due to a defect in lipid transport metabolism, in the skin, tendons, and lower extremities¹. Pulmonary xanthomas have been reported very rarely. However, they may cause life-threatening complications². The possible degree and rate of growth of these lesions are yet to be determined. For this reason, such lesions should be resected when found. The current report aimed to present a case of pulmonary xanthoma, which was successfully treated with surgical excision.

Case

A 31-year-old male patient, having no history of smoking, asbestos, or chemical exposure applied with an intractable cough for 2 months. A chest radiograph revealed a left-hilar homogenous lesion. Computed tomography (CT) imaging of the chest showed a solid, cystic parenchymal or mediastinal lesion with a 30×38×36 mm size in the anterior segment of the left upper lobe that was adjacent to the pericardium (Fig. 1). Physical examination findings and routine blood tests were within normal limits. The body mass index was 30.5 kg/m². Forced Expiratory Volume in one second (FEV1) was 2600 mL (70% of predicted), and Forced Vital Capacity was 3050 mL (68%).

Preliminary diagnoses of a bronchogenic cyst, hydatid cyst, or pericardial cyst were performed, and the patient underwent biportal (ports at 5th and 7th intercostal spaces) video thoracoscopic left upper

İletişim/Contact: Mehlika İşcan, Thoracic Surgery Clinic, Gebze Fatih State Hospital, Kocaeli, Turkey • **Tel:** 0543 660 93 34 • **E-mail:** meblikaiscan@gmail.com • **Geliş/Received:** 25.11.2019 • **Kabul/Accepted:** 19.03.2020

ORCID: Mehlika İşcan, 0000-0001-9210-5851 • Merve Ekinci, 0000-0002-5867-1574 • Nil Çomunoğlu, 0000-0003-3573-2394 • Mehmet Kamil Kaynak, 0000-0002-4020-7554

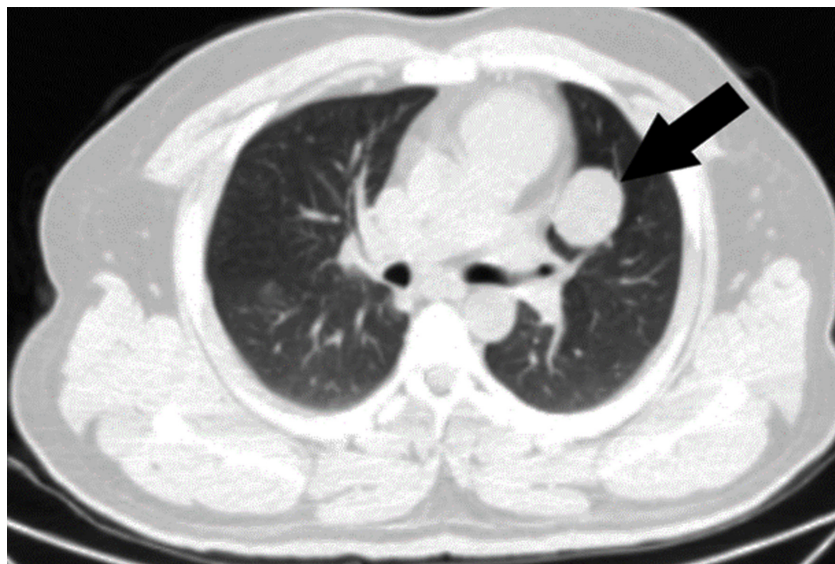


Figure 1. Chest CT shows a 4 cm lesion located at the anterior segment of the left upper lobe.

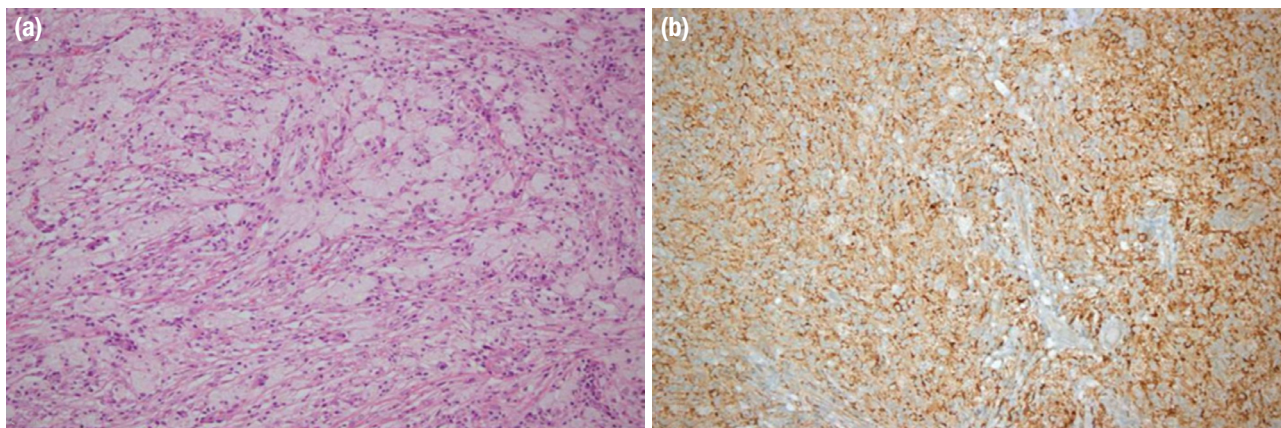


Figure 2. a, b. Xanthoma with foamy histiocytes (HE×40) 5b: (HE×200) (a). Widespread positive staining with CD68 in immunohistochemical examination (b).

lobe wedge resection under general anesthesia using double-lumen intubation with a safe surgical margin. Frozen section unveiled that there was no malignancy, but also did not provide a definitive pathologic diagnosis and further analysis was planned. The patient was discharged within 24 hours after the surgery without any complication.

No microorganism growth was observed in the microbiological examination of the resected material. The size of the lesion was reported to be 4x3x2 cm according to histopathological results. BRAF mutation test and tp64 results were negative. The detailed pathological report revealed xanthomatous tissue, inflammatory cell infiltration, including lymphocyte and plasma cells with lipid-loaded foamy histiocytes separated from the

lung parenchyma. Therefore, a pulmonary xanthoma diagnosis was made (Fig. 2).

Upon identifying the diagnosis, the patient was re-evaluated for systemic xanthomatous diseases. Physical examination revealed no xanthomatous skin lesions. However, total cholesterol, triglyceride, HDL and LDL levels were 259 mg/dL, 297 mg/dL, 31 mg/dL and 192 mg/dL respectively. Grade 1 hepatosteatosis was reported in liver ultrasonography. Echocardiography was normal. He had no family history of hyperlipidemia, early cardiac death, systemic disease, or any malignancies. The patient was then reached and referred to the Genetics and Internal Medicine departments; he was diagnosed with hyperlipidemia.

Discussion

Xanthoma is a benign proliferative lesion characterized by a localized accumulation of lipid-loaded histiocytes due to abnormalities in the transport of lipids such as phospholipids, cholesterol, and triglycerides. Microscopically, it is composed of foam histiocytes, cholesterol slits, giant cells, and a reactive fibrous stroma in various ratios¹. Xanthoma may be seen in normolipidemic cases as well as in hyperlipidemic patients². In our case, hypercholesterolemia and hyperlipidemia were present. Xanthomas may be the first to suggest the diagnosis of familial hypercholesterolemia, leading to early-stage coronary artery disease and myocardial infarction-related deaths². Therefore, our case was also evaluated by the medical genetics department, but familial hypercholesterolemia was excluded since the patient had no family history of hyperlipidemia and early cardiac death.

Patients are usually asymptomatic, and the disease is most commonly detected during physical examinations and incidentally with tests performed for other clinical conditions; however, symptoms may also develop due to the localization of the xanthoma^{2,3}. In our case, radiological findings of a pulmonary lesion were present in our patient who complained of acute bronchial cough. Xanthomas are most commonly seen on skin and tendons, and very rarely in the thoracic cavity and lung^{2,3}. No skin lesion was present in our patient, echocardiography was normal, and liver ultrasonography indicated grade 1 hepatosteatosis. In our patient who had a grade 1 obesity, grade 1 hepatosteatosis, and pulmonary xanthoma was believed to have developed due to hyperlipidemia. A case report of a rare intrathoracic xanthoma that led to auto-pneumonectomy demonstrates that, despite having benign character, xanthomas may cause life-threatening complications related to their localization². Guvener et al.³ reported

the resection of a large intrathoracic extrapulmonary xanthoma mimicking lung cancer in a patient with familial hypercholesterolemia type II. In our patient, who was thought to have a bronchogenic cyst, hydatid cyst or pericardial cyst, the final pathology report of the resected material was conclusive for pulmonary xanthoma. The xanthoma of the lung is considered a benign lesion and successfully treated with local resection, preventing the occurrence of life-threatening complications due to its localization⁴. Pulmonary xanthomas are extremely rare and may mimic cysts or tumors^{2,3}.

An appropriate resection was performed, which led to correct diagnosis and complete treatment. Pulmonary xanthoma should be kept in mind as a rare diagnosis in seemingly-perfect cystic lesions extending into the lung. The lesion should be resected without delay to prevent any life-threatening development. Further studies are needed to determine the possibility of preoperative diagnosis and recurrence after lesion resection.

References

1. Zak A, Zeman M, Slaby A, Vecka M. Xanthomas: clinical and pathophysiological relations. *Biomed Pap Med Fac Univ Palacky Olomouc Czech Repub* 2014;158(2):181–8.
2. Guvener M, Uçar HI, Tok M. Intrathoracic Xanthoma Mimicking Lung Cancer in a Patient with Familial Hypercholesterolemia Type II. A Case Report. *The Heart Surgery Forum* 10(1), 2007.
3. Andrianopoulos E, Lautide G, Kormas P, Mugolias J, Mavrogeorgis A. Pulmonary xanthoma: A case report with immunohistologic study and DNA-image analysis. *Eur J Cardiothorac Surg* 1995;9(9):534–6.
4. Weissferdt A, Moran CA editors. *Diagnostic Pathology of Pleuropulmonary Neoplasia* Springer Science & Business Media 2013. pp.415–417.