

## Histologic Evaluation of Artificial Floors Under MTA and Nano-Filled Resin-Modified Glass Ionomer Used to Repair Furcation Perforations in Dogs

 Adel A. ALADIMI,  Hatem A. ALHADAINY,  Ali FARAG,  Nahed Abo AZMA,  Faisal TORAD,  Saleem ABDULRAB

### ABSTRACT

**Objective:** This study aimed to compare the tissue reaction of two repair materials for furcation perforations, nano-filled resin modified glass ionomer (Nano-FRMGI) and mineral trioxide aggregate (MTA), used with or without an artificial floor.

**Methods:** A total of 96 teeth in 6 dogs were used for this study. After access cavities, root canals were prepared and obturated with gutta percha using cold lateral condensation technique. Perforations were then created on the floors of the pulp chambers. The perforations divided into four groups n=24/group that were sealed with MTA alone, MTA with calcium sulphate artificial floor (CSAF), FRMGI alone and Nano-FRMGI with CSAF. All access cavities were filled with composite resin. Two dogs were sacrificed at 1, 3, and 6 month. The experimental tooth along with the surrounding alveolar bone were cut in block sections and histologically evaluated for tissue response. Data were analyzed by Chi-square ( $P \leq 0.05$ ).

**Results:** MTA and MTA with CSAF showed more bone and cementum apposition when compared to Nano-FRMGI at 6-month interval. MTA and MTA with CSAF showed less bone resorption, epithelium proliferation and inflammation compared to Nano-FRMGI at 6-month interval.

**Conclusion:** MTA with CSAF or MTA-alone show better outcomes in the repair of pulp chamber floor perforation.

**Keywords:** Artificial floor, calcium sulphate, mineral trioxide aggregate, glass ionomer, pulp chamber perforation, plaster of Paris

Please cite this article as: Aladimi AA, Alhadainy H, Farag A, Azma NA, Torad F, Abdulrab S. Histologic Evaluation of Artificial Floors Under Mta and Nano-Filled Resin-Modified Glass Ionomer Used to Repair Furcation Perforation in Dogs. Eur Endod J 2020; 2: 138-44

From the Department of Conservative Dentistry (A.A.A.) College of Dentistry, Taiz University, Taiz, Yemen; Department of Conservative Dentistry (H.A.), University of North Carolina, Chapel Hill, NC, USA; Department of Endodontics (A.F.), Faculty of Dentistry, Tanta University, Tanta, Egypt; Department of Oral Pathology (N.A.A.), Faculty of Dentistry, Tanta University, Tanta, Egypt; Department of Surgery, Anesthesiology and Radiology (F.T.), Faculty of Veterinary Medicine, Cairo University, Cairo, Egypt; Department of Dentistry (S.A.) ✉ dentistsalim@gmail.com), Madinat Khalifa Health Center, Primary Health Care Corporation, Doha, Qatar

Received 04 November 2019,  
Accepted 09 April 2020

Published online: 15 May 2020  
DOI 10.14744/eej.2020.44127

This work is licensed under a Creative Commons Attribution-NonCommercial 4.0 International License.



### HIGHLIGHTS

- MTA alone or with CSAF has similar tissue response when used as a perforation repair material in dogs.
- MTA with CSAF show better outcomes about a newly bone and cementum formation.
- Nano-FRMGI is not the suitable material for repairing furcal perforations even when used with CSAF.

### INTRODUCTION

Root perforation is an pathological communication between the root canal system and supporting tissues of the tooth through the root canal wall or the pulp chamber floor. The etiology of furcation perforation may be pathological (extensive caries, root resorption) or iatrogenic resulting from procedural accident during access preparation via an incorrectly directed bur, dealing with calcified pulp chambers or during post preparation (1, 2). The affected tissues respond through varied levels of inflammation, and the outcome of repairing root perforations depends on several factors such as the time elapsed before repairing the defect, location of the perforation, the adequacy of perforation seal and the size of the perforation (3).

Although several materials have been recommended for sealing root perforation, mineral trioxide aggregate (MTA) considered the gold standard and the material of choice (4, 5). The biocompatibility of MTA, its ability to seal root perforations effectively and its setting properties in the presence of moisture or even blood are important characteristics that may result in greater success rates when used for treating root perforations (4, 6, 7). Animal studies, case reports, and case series are available on the successful use of MTA as a perforation sealing material (8, 9). In vivo studies on furcation perforation revealed that MTA induced the formation of mineralized tissue (10, 11).

However, MTA is relatively expensive and hard to manipulate, especially in small defects. Researchers and clinicians have reported that it exhibits poor handling characteristics beside long setting time and tooth discoloration (4, 12). In a recent systematic review and meta-analysis, MTA appeared to enhance success rate up to 80.9% (13).

An artificial floor technique was introduced by Alhadainy et al. (14) for the repair of furcation perforation. In addition to control the extension of the repair materials, artificial floor excludes epithelial tissues from the sites of bone formation to help the regeneration of periodontal tissues. The artificial floor should be biodegradable material such as calcium sulphate that has been to act as a good barrier against the extrusion of the repair materials (1, 14).

A nano-filled resin modified glass ionomer (Nano-FRMGI) restorative material (glass ionomer that is modified by adding nano-sized resinous fillers) has been introduced for restoration of primary teeth and small cavities in permanent teeth. The Nano-FRMGI bonds effectively to enamel and dentin and its bonding mechanism could be attributed to micro-mechanical interlocking provided by the surface roughness, most likely combined with chemical interaction through its acrylic itaconic acid copolymers to get the best adhesion (15).

However, the problem with furcation perforation repair is still not agreed on as there is no currently available material meets all the ideal requirements of an ideal repair material as defined in the literature. Therefore, the objective of this study is to compare the tissue reaction of two repairing materials for furcation perforations (Nano-FRMGI and MTA) used with or without calcium sulphate artificial floor (CSAF).

## MATERIALS AND METHODS

The protocol of this study was approved from the committee of dental research and ethics of institution in accordance with international agreements of World Medical Association Declaration of Helsinki "Ethical Principles for Medical Research Involving Human Subjects, October 2013" at ([www.wma.net](http://www.wma.net)).

This study involved 96 teeth from 6 healthy adult male dogs, weighting between 11 to 17 kg and more than 1 year old. Each dog was numbered by a collar tag for consistent identification. Both sides of the mandibular and maxillary premolars, first and second molars were used (16 teeth per dog). The 96 teeth were divided into 4 groups (n=24) according to the furcation repair material. G1: MTA (Pro Root MTA, Dentsply Tulsa Dental, Tulsa, OK, USA), G2: MTA with CSAF (CAPSET, Lifecore Biomedical, Inc, Chaska, MN), G3: Nano-FRMGI (3M ESPE, Germany), G4: Nano-FRMGI with CSAF.

### Operative procedures

Each dog was medicated with an intramuscular injection of acepromazine (Prom Ace S- AVECO, Fort Dodge, Iowa) at 0.2 mg/kg dosage for sedation to allow its safe handling. At the same time, the dog received an intramuscular injection of atropine sulphate in a dose of 0.04 mg/kg to decrease salivary secretions. One dose of penicillin (Penicillin G Benzathine and Penicillin G Procaine) was also intramuscularly given at 30.000 U/Kg as prophylactic against infection. Each dog was placed under general

anaesthetic by a veterinarian via intravenous injection of a mixture of ketamine hydrochloride and Xylazine in ratio of 1: 2.

Preoperative radiographs were taken for all teeth before beginning of any operative procedures to confirm absence of periapical pathologies and complete root formation. A diamond bur (Mani Inc, Touchigi-Ken, Japan) in high-speed handpiece with water-cooling was used to reduce the cusps until until the pulps were exposed; coronal access openings were prepared with #2 round bur in a low-speed handpiece. After pulpectomy, the working length was determined 2 mm short of the radiographic apex. Instrumentation of the canal was completed with nickel-titanium K-files (Dentsply/Maillefer Corporation, Zurich, Switzerland) using a step-back technique and irrigation of root canals with 2.5% sodium hypochlorite were performed after each file. All prepared root canals were filled with gutta percha (Dentsply/Maillefer Corporation, Zurich, Switzerland) and AH26 sealer (Dentsply/Maillefer Corporation, Zurich, Switzerland) using cold lateral compaction technique.

A 1.4 mm diameter perforation was created in the center of the pulp chamber floor of the experimental teeth using a sterile #2 round bur (Dentsply/Maillefer Corporation, Zurich, Switzerland) at low speed. The perforation depth was limited to 2 mm into the alveolar bone. This was guided by using preoperative radiograph (parallel technique) and a rubber stopper as a marker on the shank of the bur. Sodium hypochlorite solution was used to irrigate the perforations and followed by normal saline solution. Bleeding was controlled and swabbed with sterile cotton pellets. Materials were prepared according to the manufacturers' instructions and gently placed into the perforations. After setting of the materials, the coronal access cavity was sealed with light-cured composite resin (Filtek™ Z250 XT, 3M ESPE). Two dogs were sacrificed at each interval (1, 3, and 6 months) with a 150 mg/kg overdose of sodium pentobarbital (65 mg/mL) (Altabarak 10st Alkopa, Cairo, Egypt). Evaluation of the tissue reaction was made histologically.

### Histological evaluation:

The teeth with surrounding bone were block sectioned and placed immediately in 10% neutral buffered formalin for tissue fixation and decalcified for 8 weeks using formic acid-sodium citrate. After dehydration and histological processing, Step-serial sections of each block were cut using a microtome at a setting of 6µ thickness through the area of the furcal perforation in longitudinal sections parallel to the mesiodistal plane. Slides were stained with hematoxylin and eosin. Slides were then examined under light microscopy and photographs of selected areas were taken using a digital camera.

The histological sections were assessed for inflammation and type of healing at the furcation area adjacent to the repaired materials. The severity of inflammation was classified as in Table 1. The presence or absence of bone resorption, bone or cementum deposition, active of fibrosis, inflammation, regeneration PDL and epithelium at the furcation site were scored according to criteria used by AL Daafas and AL Nazhan (16).

### Statistical analysis

Date were collected and tabulated, and descriptive statistics were presented as frequencies and corresponding percent-



**TABLE 1.** Classification of the severity of inflammation

Scores	Classification	Description
0	None	No infiltration of inflammatory cells
1	Mild	Few scattered inflammatory cells
2	Moderate	Inflammatory cells did not obscure the normal tissues
3	Severe	Massive infiltration of inflammatory cells replaced normal tissue

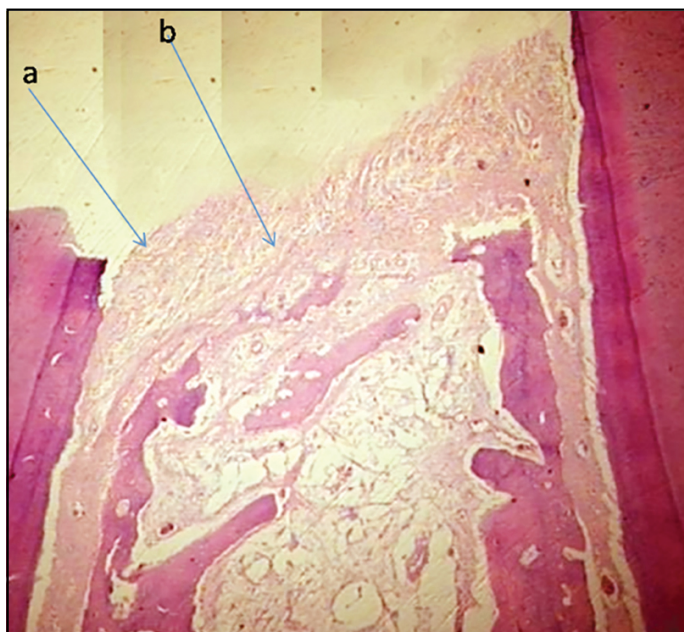
ages. Groups were analyzed for significant differences using Chi-square test and mean rank test at  $P \leq 0.05$ .

**RESULTS**

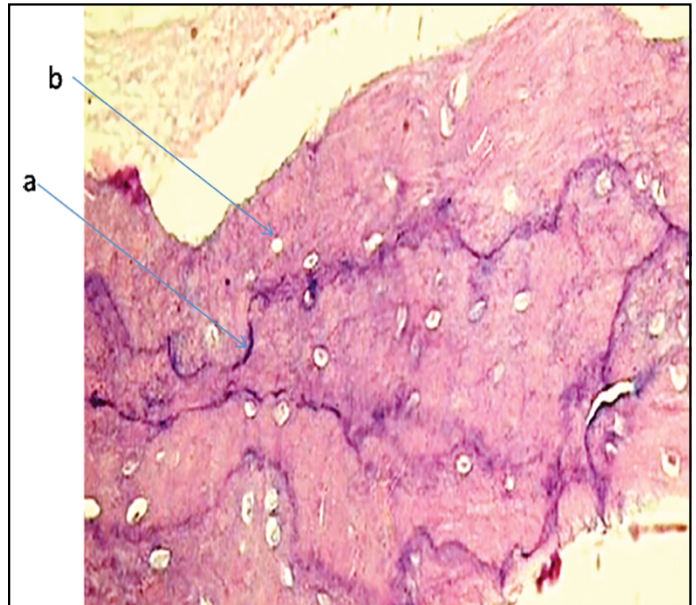
**Tissues responses for different treatment options and different time points:**

Table 2 shows histological tissue reaction with different treatment options and different time points. Bone deposition was observed in up to 62.5% of cases in all groups. It occurred more frequently in MTA with CSAF and Nano-FRMGI with CSAF throughout the successive time intervals. However, bone resorption was found in 50% of cases after one month. In Nano-FRMGI, bone resorption decreased at 3- and 6-month observation. No single case of cementum deposition was reported in any group after one month. Afterward, cementum deposition increased gradually in MTA and MTA with CSAF at 3- and 6-month follow-up, while Nano-FRMGI and Nano-FRMGI with CSAF the increase was minimal.

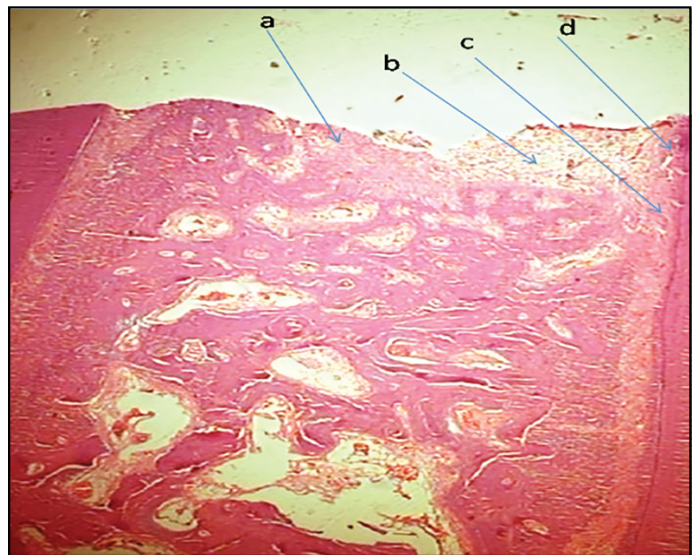
Initial inflammation occurred in all groups with subsequent resolution of few cases through time except for Nano-FRMGI. Periodontal ligament (PDL) regeneration was observed in all groups through all time intervals, while MTA and MTA with CSAF were the highest percentage. Epithelium proliferation occurred in some cases of all groups after one month and disappeared with time in MTA and MTA with CSAF but oscillated in Nano-FRMGI and Nano-FRMGI with CSAF (Figs. 1-8).



**Figure 1.** A photomicrograph of stained tissue section of the bifurcation of MTA after 6 months showing perforation area (a) contains mild inflammation (b) and new bone formation(c) (H&E 40X)



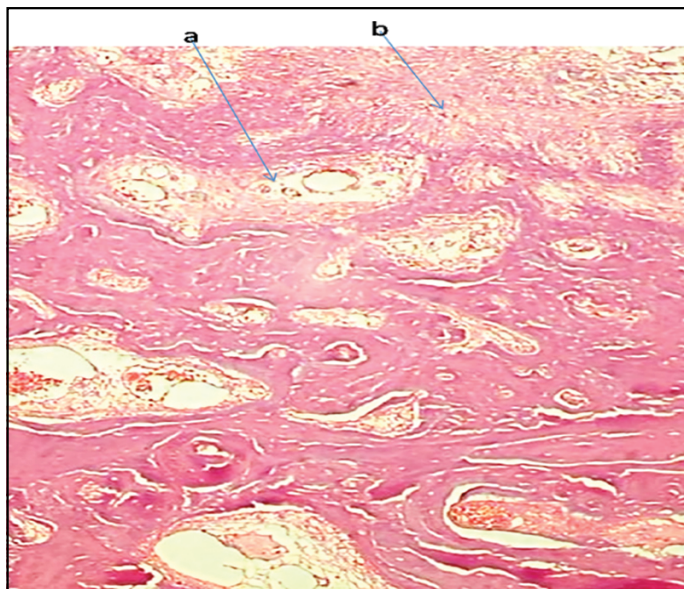
**Figure 2.** A photomicrograph of stained tissue section of the bifurcation of MTA after 6 months showing perforation area (a) contains mild inflammation (b) and new bone formation(c) (H&E 200X)



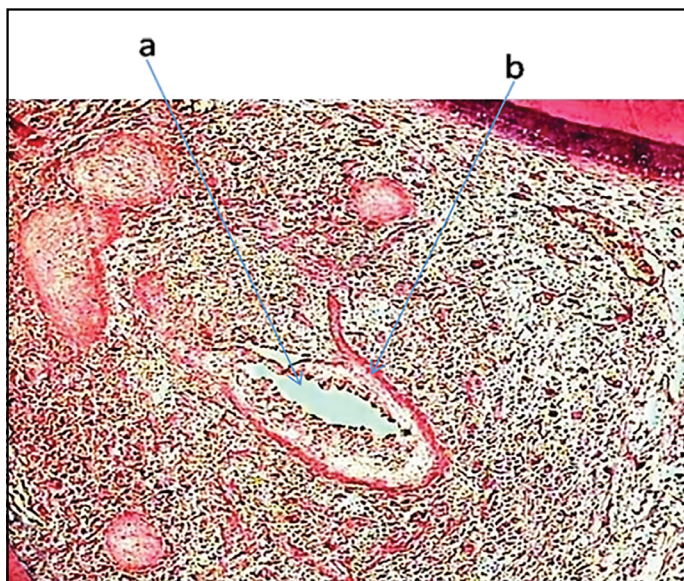
**Figure 3.** A photomicrograph of stained tissue section of the bifurcation of Calcium sulfate with MTA after 6 months showing new bone formation and Improve toward to perforation (a), Mild chronic inflammation (b), Regeneration PDL(c) and new cementum formed (d) (H&E 200X)

Inter-groups comparison, Chi square test showed no statistical significant difference between groups at any time interval ( $P > 0.05$ ). However, intra-group comparison, mean rank test indicated a significant difference between 1-month interval and 6-month interval in cementum for MTA-alone ( $P < 0.05$ ). That





**Figure 4.** A photomicrograph of stained tissue section of the bifurcation of Calcium sulfate with MTA after 6 months showing new bone formation and Improve toward to perforation (a), Mild chronic inflammation (b), Regeneration PDL (H&E 40X)

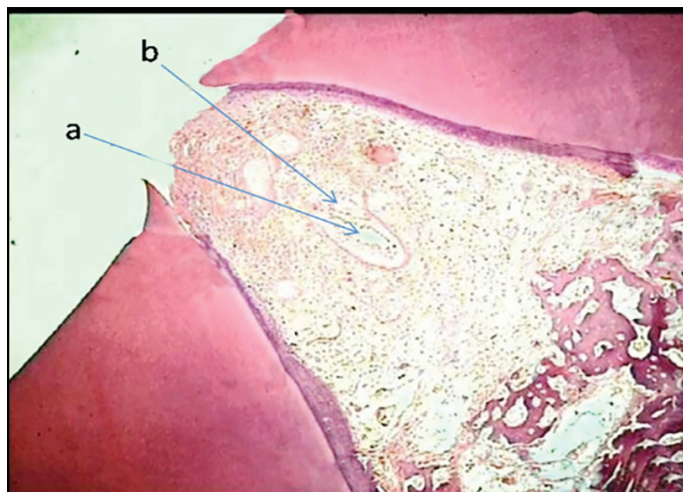


**Figure 5.** A photomicrograph of stained tissue section of the bifurcation of NanoFRMGI after six months showing abscess formation (a) and many chronic inflammatory cells surrounded the abscess cavity (b) (H&E 200X)

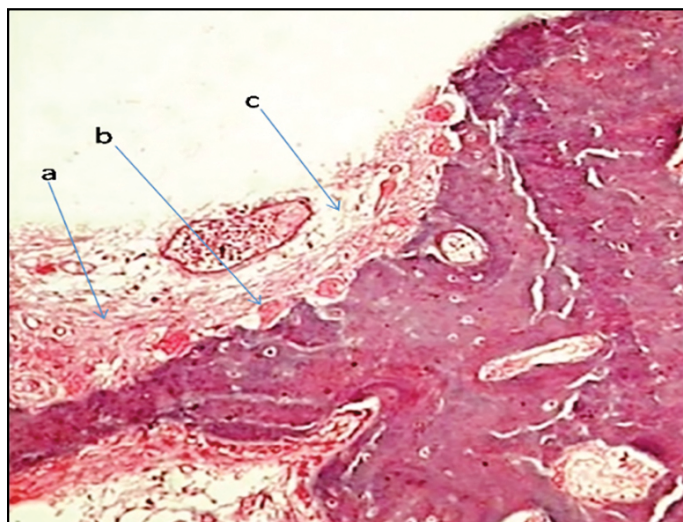
is, a significant increase in cementum deposition at 6-month interval was found. There was also a significant increase in cementum deposition and a significant decrease in inflammation at 6-month compared to 1-month interval in MTA/CSAF group.

**Severity of inflammation for different treatment options and time intervals:**

Table 3 represents the severity of inflammation induced by the used materials in all time points observations. All the materials used induced some degree of inflammation ranging from mild to moderate. Unlike Nano-FRMGI and Nano-FRMGI with CSAF, the inflammation resolved with time in MTA and MTA with



**Figure 6.** A photomicrograph of stained tissue section of the bifurcation of NanoFRMGI after six months showing abscess formation (a) and many chronic inflammatory cells surrounded the abscess cavity (b) (H&E 40X)



**Figure 7.** A photomicrograph of stained tissue section of the bifurcation of Calcium sulfate with Nano Filled Resin Modified Glass Ionomer after six months showing PDL regeneration and reorientation (a), improve bone formation toward perforation (b) and bone marrow spaces containing blood capillaries (c) (H&E 200X)

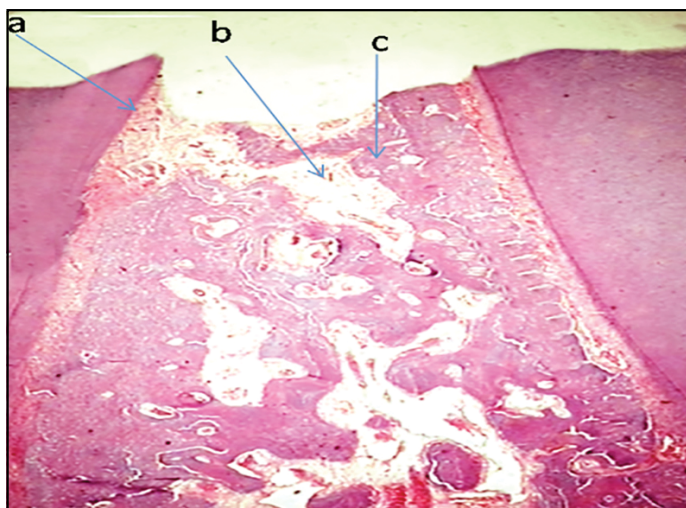
CSAF. Comparison using Chi square test showed statistically no significant differences ( $P > 0.05$ ).

**DISCUSSION**

The material used in direct contact with living tissue should meet certain standards of tissue compatibility, in addition to any therapeutic or mechanical benefit that it may provide. Therefore, this study was conducted to investigate the tissue response to different repairing materials and techniques used in repairing furcation perforations and dogs appear to possess the most suitable model characteristic to furcation perforation studies (17).

Initial high inflammatory response was found with all groups at one-month interval that decreased gradually in the subsequent intervals. These finding are in accordance with other studies (14,





**Figure 8.** A photomicrograph of stained tissue section of the bifurcation of Calcium sulfate with Nano Filled Resin Modified Glass Ionomer after six months showing collagen formation (a), osteoclastic activity with bone resorption in peripheral bone (b) and minimal amount of chronic inflammatory cells (c) (H&E 40X)

16-20). This initial inflammatory response to MTA is most likely attributed to its high pH, heat generated during setting and the generation of inflammatory cytokines such as interleukin-1 and interleukin-6 contributing to that process (21). The low inflammatory score in MTA groups at 3- and 6-month intervals may be related to the increasing strength by time, ability to set in the presence of blood, being hydrophilic, low cellular toxicity, and anti-microbial effect on certain bacteria (22, 23).

Abscess was formed in one sample of Nano-FRMGI group at 3-month interval and another at 6-month interval. These find-

ings agreed with previous findings (26-27) and may be related to the resin content of Nano-FRMGI which has been reported to liberate unbound substances from methacrylate derivative which has been shown to be not only a cytotoxic agent but also a genotoxic agent (24). In addition, substances leached from glass ionomer were also cytotoxic (25).

Bone apposition increased with time and bone resorption decreased for all materials except in Nano-FRMGI group. This agreed with the findings of (14, 16, 19-20). The use of CSAF increased bone deposition more than groups with repairing materials used alone. CSAF may accelerate the rate of mineralization of new bone by providing a source of calcium ions (28), prevent extrusion of repairing material into the peri-radicular space and its rate of resorption coincides with rate of bone growth that aids in tissue regeneration and excludes epithelium from the site of bone formation (29-30). These findings confirmed with previous studies (14,31-34) that reported that the use of calcium sulphate under MTA provided the highest scores of bone deposition at 3- month evaluation period.

A high percentage of bone deposition in MTA with or without calcium sulphate at all intervals that increased with time is in accordance previous reports (16, 19, 29-30,32- 33) and (38). That can be explained by the favourable properties of MTA as mineral oxides content, non-cytotoxic, good biological compatibility and repair stimulation that allows cellular adhesion, growth and tissue proliferation on its surface (35-37).

Low percentage of bone deposition and inflammation in Nano-FRMGI at all time intervals compared with other groups agreed with previous studies (20, 26-27) and may be attributed to its initial good sealing ability which is followed by leakage due to seal breakdown by microbes from subgingival plaque

**TABLE 2.** Histological tissue reaction with different treatment options and different time intervals

Interval	Tissue reaction	Group 1 No. (%)	Group 2 No. (%)	Group 3 No. (%)	Group 4 No. (%)
1-month	Bone apposition	4 (50%)	5 (62.5%)	4 (50%)	4 (50%)
	Bone resorption	4 (50%)	3 (50%)	4 (50%)	4 (50%)
	Cementum	0 (0.0%)	0 (0.0%)	0 (0.0%)	0 (0.0%)
	Fibrosis	4 (50%)	5 (62.5%)	3 (37.5%)	4 (50%)
	Inflammation	8 (100%)	8 (100%)	8 (100%)	8 (100%)
	PDL reorientation	3 (37.5%)	3 (37.5%)	1 (12.5%)	2 (25%)
	Epithelium	3 (37.5%)	2 (25%)	4 (50%)	3 (37.5%)
3- month	Bone apposition	5 (62.5%)	6 (75%)	4 (50%)	5 (62.5%)
	Bone resorption	3 (37.5%)	2 (25%)	4 (50%)	3 (37.5%)
	Cementum	3 (37.5%)	3 (37.5%)	1 (12.5%)	1 (12.5%)
	Fibrosis	4 (50%)	5 (62.5%)	3 (37.5%)	3 (37.5%)
	Inflammation	6 (75%)	5 (62.5%)	8 (100%)	7 (87.5%)
	PDL reorientation	5 (62.5%)	5 (62.5%)	2 (25%)	3 (37.5%)
	Epithelium	2 (25%)	2 (25%)	3 (37.5%)	2 (25%)
6- month	Bone apposition	6 (75%)	7 (87.5%)	4 (50%)	5 (62.5%)
	Bone resorption	2 (25%)	1 (12.5%)	5 (62.5%)	4 (50%)
	Cementum	5 (62.5%)	5 (62.5%)	1 (12.5%)	2 (25%)
	Fibrosis	5 (62.5%)	6 (75%)	3 (37.5%)	4 (50%)
	Inflammation	5 (62.5%)	4 (50%)	8 (100%)	6 (75%)
	PDL reorientation	6 (75%)	6 (75%)	3 (37.5%)	5 (62.5%)
	Epithelium	0 (0.0%)	0 (0.0%)	4 (50%)	3 (37.5%)

PDL: Periodontal ligaments

**TABLE 3.** Severity of inflammation for different treatment options after 1, 3, 6 months

Interval	Severity	Score	Group 1 No. %	Group 2 No. %	Group 3 No. %	Group 4 No. %
1-month	None	0	0 (0.0)	0 (0.0)	0 (0.0)	0 (0.0)
	Mild	1	3 (37.5)	3 (37.5)	2 (25)	2 (25)
	Moderate	2	2 (25)	2 (25)	4 (50)	3 (37.5)
	Sever	3	3 (37.5)	3 (37.5)	2 (25)	3 (37.5)
3-month	None	0	2 (25)	3 (37.5)	0 (0.0)	1 (12.5)
	Mild	1	3 (37.5)	3 (37.5)	2 (25)	3 (37.5)
	Moderate	2	2 (25)	1 (12.5)	3 (37.5)	3 (37.5)
	Sever	3	1 (12.5)	1 (12.5)	3 (37.5)	1 (12.5)
6-month	None	0	3 (37.5)	3 (37.5)	0 (0.0)	0 (0.0)
	Mild	1	3 (37.5)	4 (50)	2 (25)	3 (37.5)
	Moderate	2	2 (25)	1 (12.5)	2 (25)	3 (37.5)
	Sever	3	0 (0.0)	0 (0.0)	4 (50)	2 (25)

(26) and the resin has been reported to liberate unbound substances from polymenzaton (39). In addition, substances leached from glass ionomer were also cytotoxic (25). Although fluoride release from RMGI is considered advantageous in terms of tissue remineralization, yet the material seems to be inefficient in reducing the bacterial loads around restoration.

There was decrease in bone resorption by time in MTA with or without CSAF, while Nano-FRMGI group showed increased bone resorption over time. These findings were in agreement with Alhadainy et al. (14) who reported calcium sulphate with the lowest bone resorption that decreased with time when used to repair furcation perforation in dog's teeth. The increased bone resorption in Nano-FRMGI agrees with Al-Hezaimi et al. (26). However, the initial bone resorption may be due to the low thermal trauma generated while perforating. Although low speed was used, increased temperature may have been generated when inserting the bur into the alveolar bone. This may have caused resorption and deposition of new bone and cementum.

Bone remodelling with new deposition was found more often in MTA with or without calcium sulphate. The bone deposition after resorption is called reversal lines which are scalloped rough lines. That represent the terminal of resorption process, new osteoblasts differentiated and deposited bone tissue. Thus, the resorption cavities were filled with new bone and bone surface was gradually smoothed in late process (16).

There was no increase in epithelial proliferation in MTA neither alone nor with calcium sulphate. While Nano-FRMGI had the highest epithelial proliferation at all intervals. The presence of epithelial proliferation in the perforation areas had been reported in previous studies (14, 16). MTA with or without calcium sulphate showed no epithelial tissue at 6-month interval. This may be due to its good biocompatibility and sealing ability (19). The epithelium detected probably resulted from the trauma that occurred during the perforation of the furcal area. The presence of epithelium may also be explained by the fact of the proximity of the dog's teeth CEJ to the furcation area might be a limitation for using dog model studying the furcation perforation (40).

Periodontal ligament regeneration was observed in all groups through all time intervals, MTA alone or with calcium sulphate

showed a higher percentage of PDL regeneration at all intervals. However, there was no statistical differences between groups at any time interval. This is referred to that MTA consistently allows the overgrowth of cementum and may facilitate the regeneration of the PDL and formation of bone. When used in dogs' teeth with incomplete root formation and contaminated canals, MTA often induced the formation of apical barrier with hard tissue. The artificial floor maintained the MTA in situ may be interesting, permitting this material acting for more time. The effect of calcium sulphate is consistent with previously obtained results (14, 16, 29).

No cementum apposition was detected in any group at 1-month interval, but it was detected in all groups at 3- and 6-month intervals. MTA and MTA/CSAF had the same percentage that was higher than Nano-FRMGI and Nano-FRMGI/CSAF. These results support reports of perforation repair when using MTA (19, 29, 38, 41-43). Newly formed cementum may be derived from either the remaining PDL or ingrown connective tissue (42). This findings strongly support the role of calcite crystals and fibronectin as an initiating step in the formation of a hard tissue barrier (44). The calcite crystals were observed with reaction of calcium hydroxide content of MTA when contact the connective tissues (43).

**CONCLUSION**

In conclusion, within the limits of this study, it appears that Nano-FRMGI should not be the material of choice for repairing furcal perforations that accidentally occurs during endodontic treatment. Calcium sulphate under MTA provided the best results for repairing the accidental furcation perforation.

**Disclosures**

**Conflict of interest:** The authors declare that they have no conflict of interest.

**Ethics Committee Approval:** This study was approved from the committee of dental research and ethics of Tanta University in accordance with international agreements of World Medical Association Declaration of Helsinki.

**Peer-review:** Externally peer-reviewed.

**Financial Disclosure:** No financial support was obtained from any sponsor for this study.

**Authorship contributions:** Concept – H.A.; Design – H.A.; Supervision – A.F., F.T., N.A.A.; Funding - A.A.A.; Materials - A.A.A.; Data collection &/or processing

– A.A.A., F.T.; Analysis and/or interpretation – A.A.A.; Literature search – A.A.A.; Writing – S.A., H.A.; Critical Review – H.A., S.A.

## REFERENCES

- Fuss Z, Trope M. Root perforations: classification and treatment choices based on prognostic factors. *Endod Dent Traumatol* 1996; 12(6):255–64.
- Tsesis I, Fuss Z. Diagnosis and treatment of accidental root perforations. *Endodontic Topics* 2006; 13(1):95–107. [\[CrossRef\]](#)
- Alhadainy HA. Root perforations. A review of literature. *Oral Surg Oral Med Oral Pathol* 1994; 78(3):368–74. [\[CrossRef\]](#)
- Parirokh M, Torabinejad M. Mineral trioxide aggregate: a comprehensive literature review—Part III: Clinical applications, drawbacks, and mechanism of action. *J Endod* 2010; 36(3):400–13. [\[CrossRef\]](#)
- Srinivasan R, Bhagabati N, Rajput A, Akhtar S. Non surgical repair of iatrogenic furcal perforation of radix entomolaris. *Med J Armed Forces India* 2015; 71(Suppl 2):S422–4. [\[CrossRef\]](#)
- Torabinejad M, Hong CU, Pitt Ford TR, Kettering JD. Cytotoxicity of four root end filling materials. *J Endod* 1995; 21(10):489–92. [\[CrossRef\]](#)
- Parirokh M, Torabinejad M. Mineral trioxide aggregate: a comprehensive literature review—Part I: chemical, physical, and antibacterial properties. *J Endod* 2010; 36(1):16–27. [\[CrossRef\]](#)
- Silva LAB, Pieroni KAMG, Nelson-Filho P, Silva RAB, Hernández-Gatón P, Lucisano MP, et al. Furcation Perforation: periradicular tissue response to biodentine as a repair material by histopathologic and indirect immunofluorescence analyses. *J Endod* 2017; 43(7):1137–42. [\[CrossRef\]](#)
- de Sousa Reis M, Scarparo RK, Steier L, de Figueiredo JAP. Periradicular inflammatory response, bone resorption, and cementum repair after sealing of furcation perforation with mineral trioxide aggregate (MTA Angelus™) or Biodentine™. *Clin Oral Investig* 2019; 23(11):4019–27.
- Samiee M, Eghbal MJ, Parirokh M, Abbas FM, Asgary S. Repair of furcal perforation using a new endodontic cement. *Clin Oral Investig* 2010; 14(6):653–8. [\[CrossRef\]](#)
- Zairi A, Lambrianidis T, Pantelidou O, Papadimitriou S, Ztziapas D. Periradicular tissue responses to biologically active molecules or MTA when applied in furcal perforation of dogs' teeth. *Int J Dent* 2012;2012:257832.
- Marciano MA, Duarte MA, Camilleri J. Dental discoloration caused by bismuth oxide in MTA in the presence of sodium hypochlorite. *Clin Oral Investig* 2015; 19(9):2201–9. [\[CrossRef\]](#)
- Siew K, Lee AH, Cheung GS. Treatment Outcome of repaired root perforation: A systematic review and meta-analysis. *J Endod* 2015; 41(11):1795–1804. [\[CrossRef\]](#)
- Alhadainy HA, Himel VT, Lee WB, Elbaghdady YM. Use of a hydroxylapatite-based material and calcium sulfate as artificial floors to repair furcal perforations. *Oral Surg Oral Med Oral Pathol Oral Radiol Endod* 1998; 86(6):723–9. [\[CrossRef\]](#)
- Coutinho E, Cardoso MV, De Munck J, Neves AA, Van Landuyt KL, Poitevin A, et al. Bonding effectiveness and interfacial characterization of a nano-filled resin-modified glass-ionomer. *Dent Mater* 2009; 25(11):1347–57.
- Al-Daafas A, Al-Nazhan S. Histological evaluation of contaminated furcal perforation in dogs' teeth repaired by MTA with or without internal matrix. *Oral Surg Oral Med Oral Pathol Oral Radiol Endod* 2007; 103(3):e92–9. [\[CrossRef\]](#)
- Cardoso M, Catré D, Noites R, Paulo M, Viegas C. Animal models used in furcation perforation studies: A systematic review and comprehensive synthesis of model characteristics. *Aust Endod J* 2018; 44(3):273–80.
- Holland R, Bisco Ferreira L, de Souza V, Otoboni Filho JA, Murata SS, Dezan E Jr. Reaction of the lateral periodontium of dogs' teeth to contaminated and noncontaminated perforations filled with mineral trioxide aggregate. *J Endod* 2007; 33(10):1192–7. [\[CrossRef\]](#)
- Holland R, Filho JA, de Souza V, Nery MJ, Bernabé PF, Junior ED. Mineral trioxide aggregate repair of lateral root perforations. *J Endod* 2001; 27(4):281–4. [\[CrossRef\]](#)
- Salman MA, Quinn F, Dermody J, Hussey D, Claffey N. Histological evaluation of repair using a bioresorbable membrane beneath a resin-modified glass ionomer after mechanical furcation perforation in dogs' teeth. *J Endod* 1999; 25(3):181–6. [\[CrossRef\]](#)
- Koh ET, Torabinejad M, Pitt Ford TR, Brady K, McDonald F. Mineral trioxide aggregate stimulates a biological response in human osteoblasts. *J Biomed Mater Res* 1997; 37(3):432–9. [\[CrossRef\]](#)
- Lee SJ, Monsef M, Torabinejad M. Sealing ability of a mineral trioxide aggregate for repair of lateral root perforations. *J Endod* 1993; 19(11):541–4.
- Torabinejad M, Chivian N. Clinical applications of mineral trioxide aggregate. *J Endod* 1999; 25(3):197–205. [\[CrossRef\]](#)
- Heil J, Reifferscheid G, Waldmann P, Leyhausen G, Geurtsen W. Genotoxicity of dental materials. *Mutat Res* 1996; 368(3–4):181–94. [\[CrossRef\]](#)
- Chong BS, Owadally ID, Pitt Ford TR, Wilson RF. Cytotoxicity of potential retrograde root-filling materials. *Endod Dent Traumatol* 1994; 10(3):129–33.
- Al-Hezaimi K, Al-Fouzan K, Javed F, Rotstein I. Histological examination of furcal perforation repair using Geristore®: a preliminary report. *Dentistry* 2012; 2(120):1–4. [\[CrossRef\]](#)
- Huang TH, Yang CC, Ding SJ, Yeng M, Kao CT, Chou MY. Inflammatory cytokines reaction elicited by root-end filling materials. *J Biomed Mater Res B Appl Biomater* 2005; 73(1):123–8. [\[CrossRef\]](#)
- Yamazaki Y, Oida S, Akimoto Y, Shioda S. Response of the mouse femoral muscle to an implant of a composite of bone morphogenetic protein and plaster of Paris. *Clin Orthop Relat Res* 1988; (234):240–9. [\[CrossRef\]](#)
- Silva Neto JD, Schnaider TB, Gragnani A, Paiva AP, Novo NF, Ferreira LM. Portland cement with additives in the repair of furcation perforations in dogs. *Acta Cir Bras* 2012; 27(11):809–14. [\[CrossRef\]](#)
- Silva Neto JD, Brito RH, Schnaider TB, Gragnani A, Engelman M, Ferreira LM. Root perforations treatment using mineral trioxide aggregate and Portland cements. *Acta Cir Bras* 2010; 25(6):479–84. [\[CrossRef\]](#)
- Rafter M, Baker M, Alves M, Daniel J, Remeikis N. Evaluation of healing with use of an internal matrix to repair furcation perforations. *Int Endod J* 2002; 35(9):775–83. [\[CrossRef\]](#)
- Rahimi S, Ghasemi N, Shahi S, Lotfi M, Froughreyhani M, Milani AS, et al. Effect of blood contamination on the retention characteristics of two endodontic biomaterials in simulated furcation perforations. *J Endod* 2013; 39(5):697–700. [\[CrossRef\]](#)
- De-Deus G, Reis C, Brandão C, Fidel S, Fidel RA. The ability of Portland cement, MTA, and MTA Bio to prevent through-and-through fluid movement in repaired furcal perforations. *J Endod* 2007; 33(11):1374–7. [\[CrossRef\]](#)
- Moretton TR, Brown CE Jr, Legan JJ, Kafrawy AH. Tissue reactions after subcutaneous and intraosseous implantation of mineral trioxide aggregate and ethoxybenzoic acid cement. *J Biomed Mater Res* 2000; 52(3):528–33. [\[CrossRef\]](#)
- Torabinejad M, Hong CU, McDonald F, Pitt Ford TR. Physical and chemical properties of a new root-end filling material. *J Endod* 1995; 21(7):349–53.
- Torabinejad M, Hong CU, Lee SJ, Monsef M, Pitt Ford TR. Investigation of mineral trioxide aggregate for root-end filling in dogs. *J Endod* 1995; 21(12):603–8. [\[CrossRef\]](#)
- Torabinejad M, Hong CU, Pitt Ford TR, Kettering JD. Antibacterial effects of some root end filling materials. *J Endod* 1995; 21(8):403–6. [\[CrossRef\]](#)
- Yildirim T, Gençoğlu N, Firat I, Perk C, Guzel O. Histologic study of furcation perforations treated with MTA or Super EBA in dogs' teeth. *Oral Surg Oral Med Oral Pathol Oral Radiol Endod* 2005; 100(1):120–4. [\[CrossRef\]](#)
- Ferracane JL, Condon JR. Rate of elution of leachable components from composite. *Dent Mater* 1990; 6(4):282–7. [\[CrossRef\]](#)
- Sinai IH. Endodontic perforations: their prognosis and treatment. *J Am Dent Assoc* 1977; 95(1):90–5. [\[CrossRef\]](#)
- Ford TR, Torabinejad M, McKendry DJ, Hong CU, Kariyawasam SP. Use of mineral trioxide aggregate for repair of furcal perforations. *Oral Surg Oral Med Oral Pathol Oral Radiol Endod* 1995; 79(6):756–63. [\[CrossRef\]](#)
- Torabinejad M, Pitt Ford TR, McKendry DJ, Abedi HR, Miller DA, Kariyawasam SP. Histologic assessment of mineral trioxide aggregate as a root-end filling in monkeys. *J Endod* 1997; 23(4):225–8. [\[CrossRef\]](#)
- Holland R, de Souza V, Nery MJ, Otoboni Filho JA, Bernabé PF, Dezan Júnior E. Reaction of dogs' teeth to root canal filling with mineral trioxide aggregate or a glass ionomer sealer. *J Endod* 1999; 25(11):728–30. [\[CrossRef\]](#)
- Seux D, Couble ML, Hartmann DJ, Gauthier JP, Magloire H. Odontoblast-like cytodifferentiation of human dental pulp cells in vitro in the presence of a calcium hydroxide-containing cement. *Arch Oral Biol* 1991; 36(2):117–28. [\[CrossRef\]](#)